

Endoscopic papillary large balloon dilation for the removal of bile duct stones

Jin Hong Kim, Min Jae Yang, Jai Chul Hwang, Byung Moo Yoo

Jin Hong Kim, Min Jae Yang, Jai Chul Hwang, Byung Moo Yoo, Department of Gastroenterology, Ajou University School of Medicine, Suwon 443-721, South Korea

Author contributions: Kim JH designed, reviewed the literature, collected data, wrote and revised the paper; Yang MJ prepared the tables of this review and performed statistical analyses; Hwang JC reviewed the literature, collected data, performed significant editing; Yoo BM prepared the first draft of this manuscript. Correspondence to: Jin Hong Kim, MD, PhD, Department of Gastroenterology, Ajou University School of Medicine, San 5, Woncheon-dong, Youngtong-gu, Suwon 443-721, South Korea. jinhkim@ajou.ac.kr

Telephone: +82-31-2196937 Fax: +82-31-2195999

Received: August 27, 2013 Revised: October 14, 2013

Accepted: October 17, 2013

Published online: December 14, 2013

Abstract

Endoscopic papillary large balloon dilation (EPLBD) with endoscopic sphincterotomy (EST) has been widely used as the alternative to EST along with endoscopic mechanical lithotripsy (EML) for the removal of large or difficult bile duct stones. Furthermore, EPLBD without EST was recently introduced as its simplified alternative technique. Thus, we systematically searched PubMed, Medline, the Cochrane Library and EMBASE, and analyzed all gathered data of EPLBD with and without EST, respectively, by using a single standardized definition, reviewing relevant literatures, published between 2003 and June 2013, where it was performed with large-diameter balloons (12-20 mm). The outcomes, including the initial success rate, the rate of needs for EML, and the overall success rate, and adverse events were assessed in each and compared between both of two procedures: "EPLBD with EST" and "EPLBD without EST". A total of 2511 procedures from 30 published articles were included in EPLBD with EST, while a total of 413 procedures from 3 published articles were included in EPLBD without EST. In the results of outcomes, the

overall success rate was 96.5% in EPLBD with EST and 97.2% in EPLBD without EST, showing no significant difference between both of them. The initial success rate (84.0% vs 76.2%, $P < 0.001$) and the success rate of EPLBD without EML (83.2% vs 76.7%, $P = 0.001$) was significantly higher, while the rate of use of EML was significantly lower (14.1% vs 21.6%, $P < 0.001$), in EPLBD with EST. The rate of overall adverse events, pancreatitis, bleeding, perforation, other adverse events, surgery for adverse events, and fatal adverse events were 8.3%, 2.4%, 3.6%, 0.6%, 1.7%, 0.2% and 0.2% in EPLBD with EST and 7.0%, 3.9%, 1.9%, 0.5%, 0.7%, 0% and 0% in EPLBD without EST, respectively, showing no significant difference between both of them. In conclusion, recent accumulated results of EPLBD with or even without EST suggest that it is a safe and effective procedure for the removal of large or difficult bile duct stones without any additional risk of severe adverse events, when performed under appropriate guidelines.

© 2013 Baishideng Publishing Group Co., Limited. All rights reserved.

Key words: Balloon dilation; Endoscopic sphincterotomy; Common bile duct gallstones; Lithotripsy; Complications; Assessment; Patient outcomes

Core tip: We systematically analyzed all gathered data of endoscopic papillary large balloon dilation (EPLBD) with and without endoscopic sphincterotomy (EST), respectively, by using a single standardized definition, to evaluate their outcomes, reviewing relevant literatures. Thirty studies involving 2511 procedures of EPLBD with EST and 3 studies involving 413 procedures of EPLBD without EST were enrolled in this review. The results of EPLBD with or even without EST suggest that it is a safe and effective procedure for the removal of large or difficult bile duct stones without any additional risk of severe adverse events, when performed under appro-

priate guidelines.

Kim JH, Yang MJ, Hwang JC, Yoo BM. Endoscopic papillary large balloon dilation for the removal of bile duct stones. *World J Gastroenterol* 2013; 19(46): 8580-8594 Available from: URL: <http://www.wjgnet.com/1007-9327/full/v19/i46/8580.htm> DOI: <http://dx.doi.org/10.3748/wjg.v19.i46.8580>

INTRODUCTION

Ever since its introduction in 1974^[1,2], endoscopic sphincterotomy (EST) has become the standard procedure for the removal of common bile duct stones. However, it still runs the risk of various adverse events, such as bleeding, perforation, pancreatitis and cholangitis^[3-6], and large bile duct stones may require endoscopic mechanical lithotripsy (EML) as an adjunctive procedure to facilitate stone clearance^[7-11]. Endoscopic papillary balloon dilation (EPBD) was first proposed as an alternative to EST in 1982^[12]. Initially it was widely performed in the belief that it had more advantages over EST such as the reduction of bleeding and perforation risks and functional preservation of the biliary sphincter^[13-17]. However, it has been proven that EPBD is significantly less successful in removing bile duct stones compared to EST, because dilating balloons with a range of 6- to 10-mm in diameter are inadequate in achieving an ampullary opening wide enough^[18,19]. More importantly the risk of pancreatitis is significantly higher than EST to the extent of an increased mortality rate^[7,18,20].

Endoscopic papillary large balloon dilation (EPLBD) combined with EST was initially introduced to facilitate in the removal of large bile duct stones in 2003^[21], where large-diameter balloons (12- to 20-mm balloon) are used to remove large or difficult bile duct stones^[22-26]. It was initially presumed that this new technique would cause higher incidence rates of potential serious adverse events such as pancreatitis and bile duct perforation^[27-31]. However, recent results on EPLBD with EST have quashed these presumptions^[32-36], therefore it is rapidly and widely being adopted as a useful technique for the removal of large or difficult bile duct stones^[37-50]. As an alternative technique, EPLBD without EST was formally incorporated as a simplified technique in 2009^[51]. A number of studies have recently been conducted in South Korea and Taiwan^[43,45,52,53], concurring that it is also as safe and effective in patients with large bile duct stones without any additional risk of severe pancreatitis or perforation. Nevertheless, it was very difficult to get a precise analysis of the outcomes of EPLBD, because the results from each article were based on different definitions. Thus, we analyzed all gathered data of EPLBD with and without EST, respectively, by using a single standardized definition, reviewing relevant literatures.

LITERATURE SEARCH AND REVIEW

A search of literatures on EPLBD was initially performed

under title and abstract with the search terms “large balloon”, “balloon dilation”, “sphincteroplasty” and “endoscopic papillary large balloon dilation” by means of the commonly used online databases; PubMed, Medline, the Cochrane Library and EMBASE. After reviewing the corresponding abstracts of the retrieved articles, those that showed relevance to this review were downloaded in full text. Additional articles were then searched by tracing back on their references. Details of literature search and evaluation process are shown in Figure 1.

The following inclusion criteria were employed in this review: (1) original articles about clinical trials in humans published between 2003 and 2013 June, since EPLBD was first reported on in 2003^[21]; (2) the language filtering system was not used in online databases; (3) EPLBD performed with large-diameter balloons (12-20 mm) whether preceding EST was done or not; and (4) EPLBD performed when the standard balloon and basket techniques after EST failed even though the stone size was under 10 mm. Exclusion criteria of patients or articles were as follows: (1) review articles^[54-58], editorial letters^[59-63], case reports^[64-68], case series^[69] and preliminary reports^[70]; (2) articles which included EPBD with a dilating balloon less than 12 mm in diameter^[52,53,71-76]; (3) articles about clinical trials on only patients with surgically altered anatomy of the upper gastrointestinal tract, such as Billroth II surgery and Roux-en-Y anastomosis^[77-82]; (4) articles where data extraction were not possible^[83-86]; and (5) articles which contained duplicated patient data from another publication^[87].

Patient data from the relevant articles was independently extracted by two reviewers and is as follows; baseline clinical characteristics of the patients, study design, study inclusion criteria, a history of gastrointestinal surgery, periampullary diverticulum, largest stone size, range of stones, number of stones, treatment naïve, performance of EST, size of EST, prior EST, balloon diameter, time duration of inflated balloon, initial success rate, success rate of EPLBD without EML, rate of use of EML, overall success rate, number of sessions needed for complete stone removal, rates of adverse events and rate of surgery and mortality due to adverse events. An article of a large scaled multicenter study^[43], that included our institute, where the data of both the patients who had EPLBD with EST and those without EST were calculated as one, was re-analyzed using its raw data in order to re-group both of them separately. Any discrepancies between the two reviewers' results were resolved through discussion.

DEFINITION

Because data from each article, such as size of EST, initial success rate, success rate of EPLBD without EML, rate of use of EML, overall success rate, and rate of adverse events, was based on different definitions, we re-analyzed all gathered data by using a single standardized definition, in order to get a precise analysis of the outcomes. The size of the EST used before performing EPLBD was classified into 2 groups based on the extent of ampullary

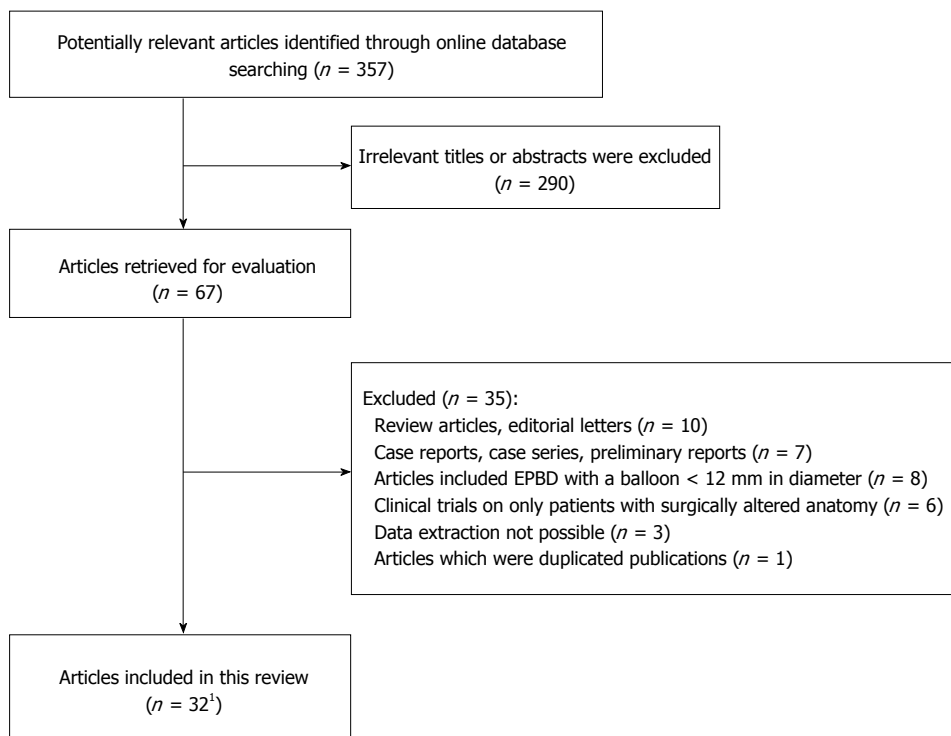


Figure 1 Flow-chart of literature search and evaluation. Data from one article of a large scaled multi-center study was re-grouped into two; endoscopic papillary large balloon dilation with and without endoscopic sphincterotomy, and the outcomes were re-analyzed separately.

incision: (1) “large” if EST was completed to anywhere between two-thirds of the total length of the ampulla and up until the major horizontal fold crossing the intramural portion of the bile duct or if the extent of EST was described under such terms as “full incision EST”^[40,46], “full-EST”^[43], “maximum EST”^[23], “major EST”^[49], “complete EST”^[29], “standard EST”^[30,36] or “normal EST”^[44]; and (2) “limited” if EST was made from the orifice of the ampulla proximally up to, but not exceeding two-thirds of the ampulla or if the extent of EST was described under such terms as “mid-incision EST”^[22,28,38], “medium EST”^[28], “middle EST”^[48], “mid-EST”^[43], “small EST”^[24,42], “minor EST”^[25] or “limited EST”^[41,47,48].

Initial success was defined as complete bile duct stone clearance when only one session of EPLBD was performed whether EML as an adjunctive procedure was used or not. Overall success was defined as overall complete bile duct stone clearance by using EPLBD whether EML as an adjunctive procedure was used or not, with the exception of using other lithotripsies such as electrohydraulic lithotripsy and laser lithotripsy, irrespective of the number of EPLBD sessions. Success of EPLBD without EML was defined as complete stone clearance without the assistance of EML by using EPLBD irrespective of the number of EPLBD sessions. The rate of use of EML was defined as the rate for using EML as an adjunctive procedure to remove bile duct stones in all cases irrespective of the number of EPLBD sessions. Adverse events were classified and graded according to the consensus criteria proposed by Cotton *et al*^[3].

STATISTICAL ANALYSIS

Statistical analyses were done using SPSS version 18.0 software (SPSS Inc., Chicago, Illinois, United States). The

significance of difference for categorical variables was determined using either chi-square test or Fisher’s exact test and a logistic regression analysis was performed for multiple comparisons in the statistically significant categorical variables that have more than two subgroups. Quantitative data were analyzed by either unpaired Student’s *t* test or Mann-Whitney test, and presented as the mean ± SD. A *P* value below 0.05 was regarded as statistically significant.

EPLBD COMBINED WITH EST

A total of 2511 procedures in 2503 patients were included in this review from 30 published original articles, made up of 23 retrospective studies, 4 prospective studies and 3 prospective randomized controlled studies. The baseline clinical characteristics of the patients are described in Table 1. Periampullary diverticulum, which was provided in 25 studies, was noted in 36.7%. Prior EST, which was provided in 28 studies, was done in 20.2%. Patients with surgically altered anatomy of the upper gastrointestinal tract, such as Billroth I or II surgery and Roux-en-Y anastomosis were included in 2.4% from 20 studies.

Patient outcomes

Based on the size of EST, EPLBD was performed in 10 studies mainly when stone removal had failed with the standard techniques after a large EST, in 13 studies after a limited EST mainly if it is speculated that the stone size is too large to be removed using the standard techniques, in 4 studies without additional EST if they had a previous history of EST, and in one multi-center study after variable sizes of EST. Twenty four studies described time duration of inflated balloon using a dilating balloon with a diameter of 12 to 20 mm which varied from 10 to 180 s, most of which were less than 60 s with the exception

Table 1 Baseline clinical characteristics of the patients undergoing endoscopic papillary large balloon dilation with endoscopic sphincterotomy *n* (%)

| Ref. | Study design | No. of procedures No. of patients | Mean age, year | No. of periampullary diverticulum | Mean size of largest stone, mm | Range of stone size, mm | Prior EST | Altered anatomy |
|------------------------------------------|--------------|--------------------------------------|-------------------|--------------------------------------|-----------------------------------|----------------------------|-----------------|--------------------|
| Ersoz <i>et al</i> ^[21] | R | 58 | NA | 4 (6.9) | NA | 12-28 | 14 | 0 |
| Hwang <i>et al</i> ^[22] | R | 30 | 71.3 | 6 (20.0) | 21.6 | 15-35 | 0 | NA |
| Maydeo <i>et al</i> ^[23] | P | 60 | 58.0 | 0 (0.0) | 16.0 | 12-20 | 0 | 0 |
| Minami <i>et al</i> ^[24] | R | 88 | 74.0 ¹ | NA | 14.0 | > 12 | 0 | NA |
| Heo <i>et al</i> ^[25] | RCT | 100 | 64.4 | 49 (49.0) | 16.0 | NA | 0 | 0 |
| Lee <i>et al</i> ^[26] | R | 55 | 70.8 | 16 (29.1) | 20.8 | 15.4-35.5 | 0 | B-II:2 |
| Kim <i>et al</i> ^[27] | R | 35 | 66.9 | 9 (25.7) | 26.1 | 12-50 | 14 | NA |
| Lee <i>et al</i> ^[28] | R | 41 | 72.2 | 21 (51.2) | 18.2 | 10-45 | 0 | B-II:2, R-Y:2 |
| Misra <i>et al</i> ^[29] | R | 50 | 40.1 | NA | NA | < 15-25 | 0 | NA |
| Attasaranya <i>et al</i> ^[30] | R | 107, 103 | 70.1 | 36 (35.0) | 13.0 ¹ | 10-30 | 50 | B-II:6 |
| Espinel <i>et al</i> ^[31] | P | 93 | 76.5 | 30 (32.2) | 13.4 | 5-30 | 42 | B-II:4 |
| Itoi <i>et al</i> ^[32] | R | 53 | 75.3 | 25 (47.2) | 14.8 | 10-28 | 0 | 0 |
| Kim <i>et al</i> ^[33] | RCT | 27 | 70.3 | 9 (33.3) | 20.8 | 15-38.3 | 0 | 0 |
| Itoi <i>et al</i> ^[34] | R | 18 | 79.1 | 9 (50.0) | 16.7 | 13-21 | 0 | B-I:1 |
| Kurita <i>et al</i> ^[35] | R | 24 | 82.0 ¹ | 18 (75.0) | 16.5 ¹ | 12-33 | 24 | NA |
| Ghazanfar <i>et al</i> ^[36] | P | 84 | 48.4 | NA | 14.7 | 10-32 | 0 | NA |
| Kim <i>et al</i> ^[37] | R | 70 | 68.7 | 24 (34.3) | 12.5 | 5-30 | 70 | NA |
| Youn <i>et al</i> ^[38] | R | 101 | 69.1 | 12 (11.9) | 21.8 | 7-52 | 0 | B-I:2, B-II:3 |
| Kim <i>et al</i> ^[39] | R | 72 | 69.3 | 41 (56.9) | NA | > 10 | 0 | 0 |
| Stefanidis <i>et al</i> ^[40] | RCT | 45 | 69.4 | NA | NA | 12-20 | 0 | 0 |
| Rebello <i>et al</i> ^[41] | R | 30 | 68.0 | 7 (23.3) | 17.0 ¹ | 12-30 | 4 | NA |
| Sakai <i>et al</i> ^[42] | R | 59 | 76.7 | 27 (45.8) | 15.0 | 10-28 | 21 | B-I:3, B-II:2 |
| Park <i>et al</i> ^[43] | R | 633 | 72.7 | 246 (39.1) | 15.4 | 10-38.4 | NA ² | B-II:20 |
| Poincloux <i>et al</i> ^[44] | R | 64, 62 | 77.0 | 15 (24.2) | NA | NA | 0 | NA |
| Hwang <i>et al</i> ^[45] | R | 69 | 68.2 | 33 (47.8) | 16.5 | NA | 0 | 0 |
| Paspatis <i>et al</i> ^[46] | RCT | 124 | 74.9 | 21 (16.9) | 15.7 | NA | NA ² | 0 |
| Rosa <i>et al</i> ^[47] | R | 68 | 70.8 | NA | 16.8 | NA | 0 | 0 |
| Yang <i>et al</i> ^[48] | R | 171, 169 | 69.3 | 73 (43.2) | 15.0 ¹ | 10-45 | 32 | B-II:1 |
| Yoon <i>et al</i> ^[49] | P | 52 | 68.1 | 19 (36.5) | 20.1 | 12-40 | 52 | 0 |
| Harada <i>et al</i> ^[50] | R | 30 | 78.0 | 23 (76.7) | 18.0 | 10-39 | 30 | NA |
| Total | | 2511, 2503 | | 773 (36.7) | | 5-45 | 353 (20.2) | 48 (2.4) |

¹Median value; ²Studies that included patients with a history of prior endoscopic sphincterotomy, but their exact numbers were not described. EST: Endoscopic sphincterotomy; R: Retrospective; P: Prospective; RCT: Randomized controlled trial; NA: Not available; B-I: Billroth-I anastomosis; B-II: Billroth-II anastomosis; R-Y: Roux-en-Y anastomosis.

of 3 studies^[27,43,49] (Table 2). The initial success rate was 84.0% (range 61.9%-100%), which was provided in only 24 studies, thirteen of which studies were designed to include cases where EML was performed along with the first session of EPLBD. The mean number of EPLBD sessions for complete stone clearance was 1.2. The success rate of EPLBD without EML, the rate of use of EML, and the overall success rate, which were provided from all 30 studies, were 83.2% (59.6%-100%), 14.1% (0%-38.6%) and 96.5% (79.7%-100%), respectively (Table 2).

Adverse events

The overall rate of adverse events following EPLBD with EST was 8.3% (0%-17.0%), the majority of which were of mild to moderate severity. Adverse events were classified as pancreatitis, bleeding, perforation, and others (Table 3), and graded accordingly to severity as found in Table 4. Pancreatitis occurred in 2.4% (0%-13.2%), all cases of which were of mild to moderate severity (98.4%), except for one fatal case who had had a history of severe pancreatitis^[46]. Bleeding occurred in 3.6% (0%-8.6%), but it mostly was of mild to moderate severity (94.5%). Four problematic bleedings, including 2 severe and 2

fatal cases, were reported in 4 studies^[29,30,36,43]; two were successfully managed with angiography and surgery, respectively, and the other two had expired due to post-EPLBD massive bleeding. Perforation occurred in 0.6% (0%-2.8%). Six problematic perforations (5 duodenum and 1 cystic duct), including 3 severe and 3 fatal cases, were reported in 3 studies^[30,43,45]; two with duodenal perforation were successfully managed with surgery and one with cystic duct perforation with percutaneous drainage, and the other three expired due to septic shock and multi-organ failure (2) and cardiogenic shock (1). Other adverse events were noted in 1.7% (0%-14.8%), including cholangitis (14), hypotension (10), pain (4), intramural dissection (3), pneumonia (3), basket impaction (2), sepsis (2), cholecystitis (1), injured bile duct (1), and hypoxia (1). All of these cases were successfully managed with conservative treatment, except for all basket impaction cases who received surgery.

EPLBD WITHOUT EST

A total of 413 patients who each received EPLBD without EST were included in this review from 3 published

Table 2 Procedure characteristics and outcomes of endoscopic papillary large balloon dilation with endoscopic sphincterotomy *n* (%)

| Ref. | Size of EST | Balloon size, mm | Duration of inflated balloon, s | Initial success | No. of sessions, mean | Success without EML | Use of EML | Overall success |
|------------------------------------------|-------------|------------------|---------------------------------|--------------------------------------|-----------------------|-------------------------|-------------------------|-------------------------|
| Ersoz <i>et al</i> ^[21] | Large | 12-20 | 20-45 | 48 (82.8) | 1.17 | 54 (93.1) | 4 (6.9) | 58 (100) |
| Hwang <i>et al</i> ^[22] | Limited | 15-18 | 30-60 | NA | NA | 30 (100.0) | 0 (0.0) | 30 (100) |
| Maydeo <i>et al</i> ^[23] | Large | 12-20 | 30 | 57 (95.0) | 1.05 | 57 (95.0) | 3 (5.0) | 60 (100) |
| Minami <i>et al</i> ^[24] | Limited | 20 | NA | 87 (98.9) | 1.00 | 87 (98.9) | 1 (1.1) | 88 (100) |
| Heo <i>et al</i> ^[25] | Limited | 12-20 | 60 | 83 (83.0) | 1.12 | 90 (90.0) | 8 (8.0) | 97 (97.0) |
| Lee <i>et al</i> ^[26] | Limited | 15-20 | 30-60 | NA | NA | 52 (94.5) | 3 (5.5) | 55 (100) |
| Kim <i>et al</i> ^[27] | Limited | 12-20 | 60-90 | NA | NA | 22 (63.1) | 9 (25.7) | 31 (88.6) |
| Lee <i>et al</i> ^[28] | Limited | 13-20 | 20-60 | 35 (85.3) | 1.20 | 37 (90.3) | 4 (9.8) | 41 (100) |
| Misra <i>et al</i> ^[29] | Large | 15-20 | 30-45 | NA | NA | 45 (90.0) | 5 (10.0) | 50 (100) |
| Attasaranya <i>et al</i> ^[30] | Large | 12-18 | NA | 102 (95.3) ¹ | 1.00 | 78 (72.9) | 29 (27.1) | 102 (95.3) |
| Espinel <i>et al</i> ^[31] | Large | 12-20 | 30-45 | 93 (100.0) ¹ | 1.00 | 90 (96.8) | 3 (3.2) | 93 (100) |
| Itoi <i>et al</i> ^[32] | Large | 15-20 | 15-30 | 51 (96.2) ¹ | 1.04 | 50 (94.3) | 3 (5.7) | 53 (100) |
| Kim <i>et al</i> ^[33] | Limited | 15-18 | NA | 23 (85.2) ¹ | 1.27 | 18 (66.7) | 9 (33.3) | 27 (100) |
| Itoi <i>et al</i> ^[34] | Large | 15-18 | 10 | 17 (94.4) | 1.06 | 14 (77.8) | 4 (22.2) | 18 (100) |
| Kurita <i>et al</i> ^[35] | Prior | 15-20 | 30 | 23 (95.8) | 1.00 | 23 (95.8) | 1 (4.2) | 23 (95.8) |
| Ghazanfar <i>et al</i> ^[36] | Large | 15-18 | NA | 52 (61.9) | 1.28 | 67 (79.7) | 0 (0.0) | 67 (79.7) |
| Kim <i>et al</i> ^[37] | Prior | 12-18 | 20-60 | 68 (97.1) | 1.02 | 69 (98.6) | 1 (1.4) | 70 (100) |
| Youn <i>et al</i> ^[38] | Limited | 15-20 | 30-60 | 93 (92.1) ¹ | 1.08 | 94 (93.1) | 7 (6.9) | 101 (100) |
| Kim <i>et al</i> ^[39] | Limited | 12-20 | 30 | 63 (87.5) ¹ | 1.14 | 64 (88.9) | 6 (8.3) | 70 (97.2) |
| Stefanidis <i>et al</i> ^[40] | Large | 15-20 | 10-12 | 44 (97.7) | 1.00 | 44 (97.7) | 0 (0.0) | 44 (97.7) |
| Rebello <i>et al</i> ^[41] | Limited | 12-18 | 60 | 25 (83.3) ¹ | 1.14 | 23 (76.7) | 6 (20.0) | 29 (96.7) |
| Sakai <i>et al</i> ^[42] | Limited | 12-20 | NA | 49 (83.1) ¹ | 1.30 | 51 (86.4) | 8 (13.6) | 57 (96.6) |
| Park <i>et al</i> ^[43] | Variable | 12-20 | 30-180 | 357 ³ (65.4) ¹ | 1.46 | 484 ⁴ (78.4) | 123 ⁴ (19.9) | 602 ⁴ (97.6) |
| Poincloux <i>et al</i> ^[44] | Large | 15-20 | 30-60 | 62 (96.9) | 1.05 | 61 (95.3) | 3 (4.7) | 64 (100) |
| Hwang <i>et al</i> ^[45] | Limited | 12-20 | 60 | 65 (94.2) ¹ | 1.02 | 51 (73.9) | 18 (26.1) | 66 (95.7) |
| Paspatis <i>et al</i> ^[46] | Large | 15-20 | 30-60 | NA | NA | 102 (81.8) | 4 (3.2) | 106 (85.0) |
| Rosa <i>et al</i> ^[47] | Limited | 12-18 | 60 | 56 (82.4) ¹ | 1.10 | 55 (80.9) | 10 (14.7) | 65 (95.6) |
| Yang <i>et al</i> ^[48] | Limited | 12-18 | NA | 163 (95.3) ¹ | 1.00 | 102 (59.6) | 66 (38.6) | 163 (95.3) |
| Yoon <i>et al</i> ^[49] | Prior | 12-20 | 60-120 | NA | 1.70 | 36 (69.2) | 12 (23.1) | 48 (92.4) |
| Harada <i>et al</i> ^[50] | Prior | 15-20 | 30 | 29 (96.7) ¹ | 1.00 | 27 (90.0) | 3 (10.0) | 29 (96.7) |
| Total | | 12-20 | 10-180 | 1745 (84.0) | 1.20 ² | 2077 (83.2) | 353 (14.1) | 2407 (96.5) |

¹Studies which were designed to include cases where endoscopic mechanical lithotripsy was performed along with the first session of endoscopic papillary large balloon dilation; ²Calculated by dividing total number of procedures into total number of sessions which was calculated by multiplying each mean number of session with each number of procedures; ³Total number of procedures was 546 due to missing data; ⁴Total number of procedures was 617 due to missing data. EST: Endoscopic sphincterotomy; EML: Endoscopic mechanical lithotripsy; Prior: Prior endoscopic sphincterotomy; NA: Not available.

original articles, all of which were retrospective studies. The baseline clinical characteristics of the patients are described in Table 5. Mean age was 71.8, periampullary diverticulum was noted in 33.2% of the patients, the mean size of the largest stone was 15.4 mm, the range of stone size was 10 mm up to 37 mm, and patients with Billroth II surgery were included in 2.7%.

Patient outcomes

EPLBD without EST was performed using a dilating balloon with a diameter of 12 to 20 mm in all 3 studies with time duration of inflated balloon of 30 s up to 180 s. The initial success rate was 76.2% (74.1%-91.9%), but two of the 3 studies were designed to include cases where EML was performed along with the first session of EPLBD. The mean number of EPLBD sessions for complete stone clearance was 1.27. The success rate of EPLBD without EML, the rate of use of EML, and the overall success rate were 76.7% (76.0%-80.6%), 21.6% (19.4%-21.7%), and 97.2% (96.8%-97.4%), respectively (Table 6).

Adverse events

The overall rate of adverse events following EPLBD without EST was 7.0% (2.6%-7.7%), the majority of which were of mild to moderate severity. Adverse events were classified as pancreatitis, bleeding, perforation, and others (Table 7), and graded accordingly to severity as found in Table 4. No cases of severe or fatal adverse events were reported. Pancreatitis and bleeding occurred in 3.9% (2.6%-6.4%) and 1.9% (0%-2.6%), respectively, all cases of which were of mild to moderate severity. Perforation occurred in two cases, 0.5% (0%-0.6%), both of which were of moderate severity, which were successfully managed with conservative management. As other adverse events, only 3 cases of mild cholangitis were reported from one multicenter study^[43].

COMPARISON BETWEEN EPLBD WITH EST AND EPLBD WITHOUT EST

Comparison between patients who received EPLBD with

Table 3 Adverse events of endoscopic papillary large balloon dilation with endoscopic sphincterotomy *n* (%)

| Ref. | Overall AEs | Pancreatitis | Bleeding | Perforation | Others | AE-related surgery | AE-related death |
|-------------------------------------------|-------------|--------------|----------|-------------|-----------|--------------------|------------------|
| Ersoz <i>et al</i> ^[221] | 9 (15.5) | 2 (3.4) | 5 (8.6) | 0 (0.0) | 2 (3.4) | 0 (0.0) | 0 (0.0) |
| Hwang <i>et al</i> ^[222] | 1 (3.3) | 0 (0.0) | 1 (3.3) | 0 (0.0) | 0 (0.0) | 0 (0.0) | 0 (0.0) |
| Maydeo <i>et al</i> ^[223] | 5 (8.3) | 0 (0.0) | 5 (8.3) | 0 (0.0) | 0 (0.0) | 0 (0.0) | 0 (0.0) |
| Minami <i>et al</i> ^[224] | 15 (17.0) | 1 (1.1) | 1 (1.1) | 0 (0.0) | 13 (14.8) | 0 (0.0) | 0 (0.0) |
| Heo <i>et al</i> ^[225] | 5 (5.0) | 4 (4.0) | 0 (0.0) | 0 (0.0) | 1 (1.0) | 0 (0.0) | 0 (0.0) |
| Lee <i>et al</i> ^[226] | 2 (3.6) | 0 (0.0) | 2 (3.6) | 0 (0.0) | 0 (0.0) | 0 (0.0) | 0 (0.0) |
| Kim <i>et al</i> ^[227] | 1 (2.8) | 0 (0.0) | 0 (0.0) | 1 (2.8) | 0 (0.0) | 0 (0.0) | 0 (0.0) |
| Lee <i>et al</i> ^[228] | 3 (7.2) | 2 (4.8) | 1 (2.4) | 0 (0.0) | 0 (0.0) | 0 (0.0) | 0 (0.0) |
| Misra <i>et al</i> ^[229] | 7 (14.0) | 4 (8.0) | 3 (6.0) | 0 (0.0) | 0 (0.0) | 1 (2.0) | 0 (0.0) |
| Attasaranya <i>et al</i> ^[301] | 6 (5.6) | 0 (0.0) | 2 (1.9) | 1 (0.9) | 3 (2.8) | 1 (0.9) | 0 (0.0) |
| Espinel <i>et al</i> ^[311] | 2 (2.2) | 1 (1.1) | 1 (1.1) | 0 (0.0) | 0 (0.0) | 0 (0.0) | 0 (0.0) |
| Itoi <i>et al</i> ^[32] | 2 (3.8) | 1 (1.9) | 0 (0.0) | 0 (0.0) | 1 (1.9) | 0 (0.0) | 0 (0.0) |
| Kim <i>et al</i> ^[33] | 0 (0.0) | 0 (0.0) | 0 (0.0) | 0 (0.0) | 0 (0.0) | 0 (0.0) | 0 (0.0) |
| Itoi <i>et al</i> ^[34] | 0 (0.0) | 0 (0.0) | 0 (0.0) | 0 (0.0) | 0 (0.0) | 0 (0.0) | 0 (0.0) |
| Kurita <i>et al</i> ^[35] | 0 (0.0) | 0 (0.0) | 0 (0.0) | 0 (0.0) | 0 (0.0) | 0 (0.0) | 0 (0.0) |
| Ghazanfar <i>et al</i> ^[36] | 6 (7.1) | 3 (3.6) | 3 (3.6) | 0 (0.0) | 0 (0.0) | 0 (0.0) | 1 (1.2) |
| Kim <i>et al</i> ^[37] | 1 (2.3) | 1 (2.3) | 0 (0.0) | 0 (0.0) | 0 (0.0) | 0 (0.0) | 0 (0.0) |
| Youn <i>et al</i> ^[38] | 7 (6.9) | 2 (2.0) | 2 (2.0) | 1 (1.0) | 2 (2.0) | 0 (1.0) | 0 (1.0) |
| Kim <i>et al</i> ^[39] | 6 (8.3) | 5 (6.9) | 0 (0.0) | 0 (0.0) | 1 (1.4) | 0 (0.0) | 0 (0.0) |
| Stefanidis <i>et al</i> ^[40] | 2 (4.4) | 1 (2.2) | 1 (2.2) | 0 (0.0) | 0 (0.0) | 0 (0.0) | 0 (0.0) |
| Rebello <i>et al</i> ^[41] | 4 (13.3) | 1 (3.3) | 0 (0.0) | 0 (0.0) | 3 (10.0) | 0 (0.0) | 0 (0.0) |
| Sakai <i>et al</i> ^[42] | 4 (6.8) | 0 (0.0) | 1 (1.7) | 1 (1.7) | 2 (3.4) | 0 (0.0) | 0 (0.0) |
| Park <i>et al</i> ^[43] | 71 (11.2) | 13 (2.1) | 48 (7.6) | 7 (1.1) | 3 (0.4) | 2 (0.3) | 4 (0.6) |
| Poincloux <i>et al</i> ^[44] | 9 (14.1) | 2 (3.1) | 5 (7.8) | 0 (0.0) | 2 (3.1) | 0 (0.0) | 0 (0.0) |
| Hwang <i>et al</i> ^[45] | 5 (7.2) | 3 (4.3) | 0 (0.0) | 1 (1.4) | 1 (1.4) | 2 (2.9) | 0 (0.0) |
| Paspatis <i>et al</i> ^[46] | 17 (13.7) | 4 (3.2) | 6 (4.8) | 2 (1.6) | 5 (4.1) | 0 (0.0) | 1 (0.8) |
| Rosa <i>et al</i> ^[47] | 10 (14.7) | 9 (13.2) | 0 (0.0) | 0 (0.0) | 1 (1.5) | 0 (0.0) | 0 (0.0) |
| Yang <i>et al</i> ^[48] | 8 (4.7) | 2 (1.2) | 4 (2.4) | 1 (0.6) | 1 (0.6) | 0 (0.0) | 0 (0.0) |
| Yoon <i>et al</i> ^[49] | 0 (0.0) | 0 (0.0) | 0 (0.0) | 0 (0.0) | 0 (0.0) | 0 (0.0) | 0 (0.0) |
| Harada <i>et al</i> ^[50] | 1 (3.3) | 0 (0.0) | 0 (0.0) | 0 (0.0) | 1 (3.3) | 0 (0.0) | 0 (0.0) |
| Total | 809 (8.3) | 61 (2.4) | 91 (3.6) | 15 (0.6) | 42 (1.7) | 6 (0.2) | 6 (0.2) |

AE: Adverse event.

Table 4 Comparison between endoscopic papillary large balloon dilation with and without endoscopic sphincterotomy *n* (%)

| | EPLBD with EST | No. of studies | EPLBD without EST | No. of studies | <i>P</i> value |
|--------------------------------|----------------------------------|----------------|-------------------------|----------------|----------------|
| No. of procedures | 2511 | 30 | 413 | 3 | |
| Mean of mean age, yr | 69.6 ± 8.6 ¹ | 29 | 70.3 ± 2.3 ¹ | 3 | 0.808 |
| Periampullary diverticulum | 773 (36.7) | 23 | 122 (33.2) | 2 | 0.186 |
| Initial success | 1745 (84.0) | 24 | 285 (76.2) | 3 | < 0.001 |
| Success without EML | 2077 (83.2) | 30 | 306 (76.7) | 3 | 0.001 |
| Use of EML | 353 (14.1) | 30 | 86 (21.6) | 3 | < 0.001 |
| Overall success | 2407 (96.5) | 30 | 388 (97.2) | 3 | 0.432 |
| Overall adverse events | 209 (8.3) | 30 | 29 (7.0) | 3 | 0.370 |
| Pancreatitis, total; M/Mod/S/F | 61; 51/9/0/1 (2.4) | 30 | 16; 14/2/0/0 (3.9) | 3 | 0.089 |
| Bleeding, total; M/Mod/S/F | 91; 75/11/2/2 (3.6) ² | 30 | 8; 7/1/0/0 (1.9) | 3 | 0.079 |
| Perforation, total; M/Mod/S/F | 15; 3/6/3/3 (0.6) | 30 | 2; 0/2/0/0 (0.5) | 3 | 1.000 |
| Other adverse events | 42 (1.7) | 30 | 3; 3/0/0/0 (0.7) | 3 | 0.148 |
| AE-related surgery | 6 (0.2) | 30 | 0 (0) | 3 | 1.000 |
| AE-related death | 6 (0.2) | 30 | 0 (0) | 3 | 1.000 |

¹mean ± SD; ²One case of bleeding was not graded for severity. M: Mild; Mod: Moderate; S: Severe; F: Fatal; EPLBD: Endoscopic papillary large balloon dilation; EST: Endoscopic sphincterotomy; EML: Endoscopic mechanical lithotripsy; AE: Adverse event.

EST and those who received EPLBD without EST were summarized in Table 4. Mean age and the rate of periampullary diverticulum showed no significant difference between both procedures. Mean number of EPLBD session and the overall success rate were not significantly different between both procedures, but the initial success rate (84.0% *vs* 76.2%, *P* < 0.001) and the success rate of

EPLBD without EML (83.2% *vs* 76.7%, *P* = 0.001) were significantly higher in patients who received EPLBD with EST than in those who received EPLBD without EST, while the rate of use of EML (14.1% *vs* 21.6%, *P* < 0.001) were significantly lower in patients who received EPLBD with EST. Overall adverse events, pancreatitis, bleeding, perforation, other adverse events, the rate of surgery for

Table 5 Baseline clinical characteristics of the patients on endoscopic papillary large balloon dilation without endoscopic sphincterotomy *n* (%)

| Ref. | Study design | No. of procedures | Mean age, yr | No. of periampullary diverticulum | Mean size of largest stone, mm | Range of stone size, mm | Altered anatomy |
|------------------------------------|--------------|-------------------|-------------------|-----------------------------------|--------------------------------|-------------------------|-----------------|
| Jeong <i>et al</i> ^[51] | R | 38 | 68 | NA | 17.7 | 12-31 | 0 |
| Hwang <i>et al</i> ^[45] | R | 62 | 70.4 | 16 (25.8) | 15.7 | 12-26 | 0 |
| Park <i>et al</i> ^[43] | R | 313 | 72.6 | 106 (34.6) | 15.0 | 10-37 | B-II :11 |
| Total | | 413 | 71.8 ¹ | 122 (33.2) | 15.4 ² | 10-37 | 11 (2.7) |

¹Calculated by dividing total number of procedures into total number of the parameter which was calculated by multiplying each mean value with each number of procedures; ²A retrospective multicenter study where missing data are present in each analyzed variable. R: Retrospective; B-II: Billroth-II anastomosis.

Table 6 Procedure characteristics and outcomes of endoscopic papillary large balloon dilation without endoscopic sphincterotomy *n* (%)

| Ref. | Balloon size, mm | Duration of inflated balloon, s | Initial success | No. of sessions, mean | Success without EML | Use of EML | Overall success |
|------------------------------------|------------------|---------------------------------|--------------------------------------|-----------------------|-------------------------|------------------------|-------------------------|
| Jeong <i>et al</i> ^[51] | 15-18 | 60 | 25 (65.8) | 1.20 | 29 (76.3) | 9 (23.7) | 37 (97.4) |
| Hwang <i>et al</i> ^[45] | 12-20 | 60 | 57 (91.9) ¹ | 1.05 | 50 (80.6) | 12 (19.4) | 60 (96.8) |
| Park <i>et al</i> ^[43] | 12-20 | 30-180 | 203 ³ (74.1) ¹ | 1.33 | 227 ⁴ (76.0) | 65 ⁴ (21.7) | 291 ⁴ (97.3) |
| Total | 12-20 | 30-180 | 285 (76.2) | 1.27 ² | 306 (76.7) | 86 (21.6) | 388 (97.2) |

¹Studies which were designed to include cases where endoscopic mechanical lithotripsy was performed along with the first session of endoscopic papillary large balloon dilation; ²Calculated by dividing total number of procedures into total number of sessions which was calculated by multiplying each mean number of session with each number of procedures; ³Total number of procedures was 274 due to missing data; ⁴Total number of procedures was 299 due to missing data. EML: Endoscopic mechanical lithotripsy.

Table 7 Adverse events of endoscopic papillary large balloon dilation without endoscopic sphincterotomy *n* (%)

| Ref. | Overall AEs | Pancreatitis | Bleeding | Perforation | Others | AE-related surgery | AE-related death |
|------------------------------------|-------------|--------------|----------|-------------|---------|--------------------|------------------|
| Jeong <i>et al</i> ^[51] | 1 (2.6) | 1 (2.6) | 0 (0.0) | 0 (0.0) | 0 (0.0) | 0 (0.0) | 0 (0.0) |
| Hwang <i>et al</i> ^[45] | 4 (6.4) | 4 (6.4) | 0 (0.0) | 0 (0.0) | 0 (0.0) | 0 (0.0) | 0 (0.0) |
| Park <i>et al</i> ^[43] | 24 (7.7) | 11 (3.5) | 8 (2.6) | 2 (0.6) | 3 (1.0) | 0 (0.0) | 0 (0.0) |
| Total | 29 (7.0) | 16 (3.9) | 8 (1.9) | 2 (0.5) | 3 (0.7) | 0 (0.0) | 0 (0.0) |

AE: Adverse event.

Table 8 Comparison of adverse events among endoscopic papillary large balloon dilation with large, limited and without endoscopic sphincterotomy *n* (%)

| | EPLBD with large EST | EPLBD with limited EST | EPLBD without EST | <i>P</i> value |
|-----------------------|----------------------|------------------------|-------------------|--------------------|
| No. of procedures | 756 | 946 | 413 | |
| Overall adverse event | 65 (8.6) | 71 (7.5) | 29 (7.0) | 0.568 |
| Pancreatitis | 18 (2.4) | 29 (3.1) | 16 (3.9) | 0.349 |
| Bleeding | 31 (4.1) | 12 (1.3) | 8 (1.9) | 0.001 ¹ |
| Perforation | 3 (0.4) | 5 (0.5) | 2 (0.5) | 1.000 |
| Other adverse events | 13 (1.7) | 25 (2.6) | 3 (0.7) | 0.054 |
| AE-related surgery | 2 (0.3) | 2 (0.2) | 0 (0.0) | 0.832 |
| AE-related death | 2 (0.3) | 0 (0.0) | 0 (0.0) | 0.166 |

¹EPLBD with large EST *vs* EPLBD with limited EST, *P* < 0.001; EPLBD with large EST *vs* EPLBD without EST, *P* = 0.049; EPLBD with limited EST *vs* EPLBD without EST, *P* = 0.35. EPLBD: Endoscopic papillary large balloon dilation; EST: Endoscopic sphincterotomy; AE: Adverse event.

adverse events, and fatal adverse events were not significantly different between both procedures.

We compared the rates of adverse events among 3 kinds of EPLBD procedures which we classified based on the extent of ampullary incision of the EST; large EST, limited EST and no EST (Table 8). There were no significant differences among the 3 EPLBD procedures

in the rates of the overall adverse events, pancreatitis, perforation, other adverse events, and adverse events related to surgery and death, but the rate of bleeding was significantly higher in EPLBD with large EST, compared with EPLBD with limited EST (*P* < 0.001, OR = 3.33) or without EST (*P* = 0.049, OR = 2.17), but no significant difference between EPLBD with limited EST and

Table 9 Comparison among endoscopic sphincterotomy, endoscopic papillary balloon dilation, and endoscopic papillary balloon dilation with endoscopic sphincterotomy *n* (%)

| | EST ¹ | EPBD ¹ | No. of studies | EPLBD with EST | No. of studies | <i>P</i> value |
|----------------------------|------------------|-------------------|----------------|----------------|----------------|----------------|
| No. of procedures | 890 | 878 | 15 | 2511 | 30 | |
| Mean age, range, yr | 47-71 | 49-75 | 15 | 40-82 | 29 | |
| Mean stone size, range, mm | 7.3-16.9 | 7-15.6 | 15 | 5-45 | 25 | |
| Initial success | 322 (80.9) | 285 (73.5) | 7 | 1745 (84.0) | 24 | < 0.001 |
| Use of EML | 121 (13.3) | 162 (19.6) | 13 | 353 (14.1) | 30 | < 0.001 |
| Overall success | 776 (95.3) | 733 (90.1) | 13 | 2407 (96.5) | 30 | < 0.001 |
| Overall adverse events | 113 (12.7) | 106 (12.1) | 15 | 209(8.3) | 30 | < 0.001 |
| Pancreatitis | 36 (4.3) | 71 (8.6) | 14 | 61 (2.4) | 30 | < 0.001 |
| Bleeding | 33 (4.8) | 1 (0.1) | 12 | 91 (3.6) | 30 | < 0.001 |
| Perforation | 3 (0.5) | 2 (0.3) | 9 | 15 (0.6) | 30 | 0.941 |
| AE-related death | 2 (0.3) | 4 (0.7) | 7 | 6 (0.24) | 30 | 0.152 |

¹Results of a meta-analysis by Weinberg *et al*^[18]. EST: Endoscopic sphincterotomy; EPBD: Endoscopic papillary balloon dilation; EPLBD: Endoscopic papillary large balloon dilation; EML: Endoscopic mechanical lithotripsy.

without EST ($P = 0.35$).

DISCUSSION

Standard basket and balloon techniques after EST are most commonly used for the removal of bile duct stones with overall success rates of more than 80% to 90%^[88-92]. When it fails due to the stone size being larger than the widened ampullary orifice by performing EST or the distal common bile duct, additional endoscopic procedures, mainly EML, are usually required for complete stone clearance^[93-97]. However, EML proved to be a time-consuming and challenging technique^[11,98,99]. EPLBD has been widely used as the alternative to EST with EML for the removal of large or difficult bile duct stones. EPLBD was initially performed when the standard techniques failed after a large EST^[21,23], but recently it has been performed after a limited EST or sometimes without EST, even before attempting trials the standard technique with a large EST. Such procedure is usually performed when it is speculated that the size of the stone is too large for it to be removed using the standard techniques after a large EST and on the assumption that it would reduce the incidence rate of potential serious adverse events of a large EST such as bleeding and bile duct perforation.

The initial success rate and the overall success rate were 84.0% and 96.5%, respectively, in EPLBD with EST in this review, while the results showed 80.9% and 95.3% in EST alone and 73.5% and 90.1% in EPBD alone, respectively, in a previous meta-analysis^[18] (Table 9). When we compared these results, the initial success rate was significantly lower in EPBD alone than EPLBD with EST ($P < 0.001$, OR = 1.89) and EST alone ($P = 0.013$, OR = 1.53), but showing no significant differences between EPLBD with EST and EST alone ($P = 0.131$); the overall success rate was also significantly lower in EPBD alone than EPLBD with EST ($P < 0.001$, OR = 2.72) and EST alone ($P = 0.001$, OR = 2.03), and showing also no significant differences between EPLBD with EST and EST alone ($P = 0.141$). However, a comparison between these meta-analysis results and ours is somewhat contradictory

because their meta-analysis was of relatively small bile duct stones. Furthermore, the initial success rate in this review was statistically flawed, because studies included were designed heterogeneously based on different definitions, some of which included cases where EML was performed along with the first session of EPLBD. There were only 4 comparison studies, including 2 prospective randomized studies^[25,33] and 2 retrospective studies^[52,39], done for the evaluation of outcomes between EPLBD with EST and EST alone with the assistance of EML in patients with large or difficult bile duct stones. However, these studies failed to show any differences in the initial success rate and the overall success rate between both procedures, except one retrospective study^[52], where EPLBD with EST was superior to EST alone only in the initial success rate, not the overall success rate^[52]. The initial success rate in EPLBD without EST in this review was significantly lower, compared with that in EPLBD with EST, most likely due to the opening of the orifice retracting almost immediately back to its original size which is commonly seen in EPBD alone. However, the overall success rate showed no significant difference between both of them.

The intended purpose of EPLBD was to simplify removing large or difficult bile duct stones without additional adverse events to EST alone or EPBD alone, and contemplated major advantages were that it would reduce both the need of EML and the procedure time, increasing the success rates of stone removal, compared with EST alone and EPBD alone. This is believed to be because the wider ampullary orifice, made when using EPLBD, would facilitate in the easier extraction of relatively large bile duct stones. In addition, it may also reduce potential EML-related adverse events, such as basket impaction and bile duct injury. However, the frequency of EML use in EPLBD might be related to various factors, such as the diameter of dilating balloon used, discrepancy in the size between the stone and the ampullary orifice or the distal bile duct, and the shape of the stone and the bile duct. The rate of use of EML was 14.1% in EPLBD with EST with a wide range of 0% to 38.6% in this review. It

showed similar results in EST alone of 13.3% in a previous meta-analysis^[18], but significantly lower than EPLBD without EST of 21.6% from this review and EPBD alone of 19.6% in a previous meta-analysis^[18]. In 4 comparison studies between EPLBD with EST and EST alone, there were conflicting results concerning the use of EML for the removal of large or difficult bile duct stones; two prospective randomized studies reported no significant difference in the use of EML^[25,33], on the contrary to two retrospective studies^[32,39]. These studies overlooked one important fact that the rate of use of EML when tallied against the number of patients requiring EML, could not help but be similar between both procedures, because EML was still needed in patients where the size of the stones exceeded the size of the widened ampullary orifice even after EPLBD. However, the need for repeated EML would be reduced due to a wider ampullary orifice, if the stones were fragmented mostly by one session of EML following EPLBD. Thus, for a more accurate evaluation about the rate of use of EML, it should be calculated based on the frequency of EML use in each patient who underwent EPLBD, not the number of patients requiring EML. Mean procedure time was evaluated in two of these 4 comparison studies; one prospective randomized study failed to show any difference between EPLBD with EST and EST alone^[33], while the other retrospective study showed a shorter procedure time in EPLBD with EST^[32]. Large-scale, prospective multicenter comparison studies will be needed to confirm advantages of EPLBD in the frequency of EML use and procedure time.

In results of adverse events following EPLBD in this review, adverse events in EPLBD without EST showed no significant difference compared with those in EPLBD with EST. The most common adverse event in each procedure was bleeding with a mean rate of 3.6% in EPLBD with EST and pancreatitis with a mean rate of 3.9% in EPLBD without EST. Our results showed definite evidence that EPLBD with and even without EST, did not increase the risk of serious pancreatitis, as more frequently seen in EPBD using small-diameter balloons (≤ 10 mm)^[18,20]. It is no doubt that the mechanism of pancreatitis would be different in EPLBD, compared with EPBD, although its mechanism still remains unclear, a major etiologic factor of pancreatitis. The most serious adverse event was bile duct perforation in EPLBD with EST. The following shows the comparison of adverse events between results of a previous meta-analysis^[18] in EST alone and EPBD alone and those of our review in EPLBD with EST (Table 9); the rate of overall adverse events was significantly lower in EPLBD with EST than EST alone ($P < 0.001$, OR = 1.60) and EPBD alone ($P = 0.001$, OR = 1.51); the rate of pancreatitis was significantly lower in EPLBD with EST than EST alone ($P = 0.006$, OR = 1.80) and EPBD alone ($P < 0.001$, OR = 3.77); the rate of bleeding was not significantly different between the EPLBD with EST and EST alone ($P = 0.164$) and was significantly lower in EPBD alone than EPLBD with EST ($P = 0.001$, OR = 25.27) and EST alone ($P =$

0.001, OR = 33.75); the rate of perforation and the rate of adverse event-related death showed no significant differences among the 3 procedures ($P = 0.941$ and $P = 0.152$, respectively). However, within 4 comparison studies on adverse events between EPLBD with EST and EST alone, each study showed no significant differences between both of them^[25,32,33,39].

Major risk factors which are related to adverse events include procedure-related factors such as size of balloon, size of EST, and time duration of inflated balloon, and patient-related factors such as the existence of bile duct strictures, periampullary diverticulum, surgically altered anatomy, and a bleeding tendency. Park *et al.*^[43] reported that larger stone size more than 16mm in diameter, underlying cirrhosis, and full-length EST were independently associated with an increase in adverse events. The size of the balloon is the most important major factor in ensuring a success of EPLBD and a reduction of adverse events^[53]. As the ampullary orifice becomes wider as a result of balloon dilation, stone removal becomes easier. However, choosing an inappropriately oversized balloon increases the risk of adverse events, such as perforation or bleeding due to blood vessel injury^[53]. Interestingly, a multicenter study by Park *et al.*^[43] reported that balloons larger than 14 mm in diameter were independently associated with a decreased risk of pancreatitis, projecting that only simple stretching of the ampullary orifice or direct blockage of the pancreatic orifice by compression of large-diameter balloons is not a major etiologic factor of pancreatitis following EPLBD.

The intended maximal target diameter of a dilating balloon for EPLBD should be determined based on the size of the stone and the size of the distal bile duct proximal to the tapered segment^[26,55,100], but must never exceed the diameter of the distal bile duct to prevent bile duct perforation^[43,53]. A 12- to 20-mm diameter balloon for pyloric use (CRETM wire-guided balloon dilator, Boston Scientific, Natick, Massachusetts, United States) is mostly used to dilate the duodenal ampulla during EPLBD, each of which gradually inflates in 3 different diameter steps by increasing balloon inflation pressure. The balloon used should be selected with the 2nd or the 3rd diameter step being the intended maximal target diameter, and be inflated gradually, starting from a smaller diameter step of the balloon than the intended maximal target diameter. The balloon is slowly dilated until it reaches its 1st diameter step with gradual increment of balloon pressure to prevent sudden tearing of the ampullary roof. If the balloon is dilated without any difficulty with the disappearance of its central waist, it is then dilated gradually to its 2nd diameter step and then further up to its 3rd diameter step till its diameter reaches the intended maximal target diameter. If the central waist of the balloon does not disappear against the marked resistance of the bile duct or the patient indicates severe pain during balloon inflation at any step, further balloon inflation must be ceased for the prevention of bile duct perforation^[43]. Lee *et al.*^[55] recommended based on personal experience that balloon

inflation should be discontinued if the balloon waist does not disappear even once it reaches 75% of the recommended maximal inflation pressure. In patients who are known to have obvious distal bile duct strictures, EPBLD should be avoided to prevent bile duct perforation^[43,55]. If there is a suspicion of strictures, based on personal experience, we recommend pulling back a large retrieval balloon, that should be inflated up to approximately the same size as the distal bile duct, just up until the inside of the ampullary orifice. If there is no existence of a stricture, the suspected site of stricture should easily expand allowing the balloon to pass through without any resistance.

The extent of ampullary incision is another important major factor to prevent adverse events, such as bleeding and perforation. Theoretically, EPLBD with limited EST would have combined advantages to minimize major adverse events of both EST alone and EPBD alone, such as bleeding and perforation mainly in a large EST and pancreatitis mainly in EPBD^[54]. In comparison of the 3 different EPLBD procedures based on the extent of ampullary incision of the preceding EST, which were classified into large, limited and no EST, it showed no significant differences among them in the rates of overall adverse events, pancreatitis, perforation and other adverse events. However, the rate of bleeding was significantly higher in EPLBD with large EST than in EPLBD with limited EST or without EST, but there was no significant difference between EPLBD with limited EST and without EST. Delayed fatal bleeding was noted in 2 patients who underwent a full-incision EST before EPLBD in this review. Delayed serious bleeding may occur if a large blood vessel located at the proximal part of the ampullary roof is severed during full-incision EST, not injury caused by stretching of the ampullary orifice using a large-diameter balloon. Therefore, EPLBD with large, especially full-incision EST should be avoided to prevent serious bleeding. In patients with prior EST, it is known that extended incision of the previous EST site can increase the risk of adverse events such as bleeding or perforation^[3,6,8]. Therefore, almost all patients with prior EST did not receive repeated EST in this review. There were 3 retrospective studies and one prospective study about clinical trials of EPLBD using 12- to 20-mm large balloons on only patients with prior EST but without repeated EST, showing similar results in stone clearance and adverse events, compared with their counterpart studies in which all patients underwent no prior EST^[35,37,49,50].

The main purpose of EST during EPLBD is not to make an incision of the duodenal ampulla long, but to control the direction of tearing during balloon dilation. A probable mechanism of a reduced pancreatitis rate in EPLBD with EST is believed to be that the radial force exerted by the dilating balloon shifts along the cutting direction made during EST toward the bile duct away from the pancreatic orifice, resulting in less periampullary injury around the pancreatic duct with a decreased risk of pancreatitis^[21,24,43,101]. However, EST may be a limited

role in preventing pancreatitis in EPLBD, because there was no evidence that EPLBD without EST increased the risk of pancreatitis in this review. So to explain this, we suggest the following hypothesis surrounding the mechanism of pancreatitis after EPLBD; manipulation of Dormia basket and retrieval balloon catheter as well as the frequency of EML in EPLBD with, or even without, EST, may be reduced due to a sufficiently widened ampullary orifice, resulting in less periampullary trauma or edema that occurs during stone extraction and eventually leading to a low risk of pancreatitis. On the contrary, its frequency in EPBD using small-diameter balloons is increased due to the ampullary orifice not widening enough, increasing the risk of pancreatitis^[100].

Time duration of inflated balloon of the duodenal ampulla during EPLBD is mostly around 1 min in this review, after the intended maximal target diameter of the balloon was reached. One prospective randomized study revealed that 30 s of duration of inflated balloon was not different in adverse events, including pancreatitis, bleeding and perforation, to 60 s in EPLBD with EST^[46]. The longer the time duration of inflated balloon did not seem to be related to an increase of the risk of adverse events, and the shorter the time duration of inflated balloon seems to be related to an increase of the risk of serious bleeding, due to insufficient compression by the balloon. Further studies are warranted to determine the optimal time duration of inflated balloon during EPLBD.

The patient-related factors related to adverse events include periampullary diverticulum, surgically altered anatomy, and a bleeding tendency. Patients with periampullary diverticulum were suitable for EPLBD. A retrospective comparison study in patients between with and without periampullary diverticulum, showed similar stone clearance rates and adverse events in both, following EPLBD with limited EST^[76], and several studies reported that the presence of a periampullary diverticulum was not associated with a significant increased rate of adverse events such as pancreatitis, bleeding, or perforation^[43,46,48,86]. There were 6 studies about clinical trials of EPLBD on only patients with surgically altered anatomy, such as Billroth II surgery (5)^[77-81] and Roux-en-Y anastomosis (1)^[82], resulting in complete stone clearance in all patients with a low incidence of pancreatitis and bleeding. In patients with coagulopathy, EPLBD without EST may be useful, but should be undertaken cautiously^[43,100], even though further studies are warranted. Park *et al*^[43] reported that the size of the bile duct stone (≥ 16 mm) and presence of cirrhosis might be independent factors of bleeding. If serious bleeding from the ampulla occurs after balloon deflation, compression of the ampulla with re-balloon can be done for several minutes till the bleeding stops.

Our recommendations for a successful EPLBD are as follows, based on the results in this review and personal experiences: (1) EPLBD with large, especially full-incision EST should be avoided to prevent serious bleeding; (2) EPLBD with limited EST is recommended to be

Table 10 Recommendations for successful endoscopic papillary large balloon dilation

| |
|------------------------------------------------------------------------------------------------------------------------------------------------------------------------------------------------------------------------------------------------|
| 1 EPLBD with large, especially full-incision EST should be avoided |
| 2 EPLBD with limited EST is recommended to be performed, even before attempting trials of a standard technique with large EST, when the stone is seen to be too large on cholangiogram |
| 3 EPLBD without EST may be useful in some patients with coagulopathy, periampullary diverticulum, or surgically altered anatomy |
| 4 In patients with obvious distal bile duct strictures, EPBLD should be avoided. If there is a suspicion of strictures, using the pulling method of a large inflated retrieval balloon through the site is recommended to confirm an existence |
| 5 The intended maximal target diameter of the balloon should be determined based on the diameter of the largest stones, but should not exceed the diameter of the distal bile duct |
| 6 The balloon should always be inflated gradually, starting from a smaller diameter step of the balloon than the intended maximal target diameter |
| 7 Further balloon inflation must be ceased, if the central waist of the balloon does not disappear or the patient indicates severe pain during balloon inflation at any step |

EST: Endoscopic sphincterotomy; EPLBD: Endoscopic papillary large balloon dilation.

performed to reduce the risk of bleeding and perforation even before attempting trials of a standard technique with large EST, when the stone is seen to be too large on cholangiogram; (3) EPLBD without EST may be useful in some patients with coagulopathy, periampullary diverticulum, or surgically altered anatomy to reduce the risk of serious bleeding and perforation; (4) In patients with obvious distal bile duct strictures, EPBLD should be avoided to prevent perforation. If there is a suspicion of strictures, using the pulling method of a large inflated retrieval balloon through the site is recommended to confirm an existence; (5) The intended maximal target diameter of the balloon should be determined based on the diameter of the largest stones, but should not exceed the diameter of the distal bile duct to reduce the risk of perforation; (6) The balloon should always be inflated gradually, starting from a smaller diameter step of the balloon than the intended maximal target diameter; and (7) Further balloon inflation must be ceased to prevent perforation, if the central waist of the balloon does not disappear or the patient indicates severe pain during balloon inflation at any step (Table 10).

There are several limitations to this review. It was very difficult to analyze systematically the outcomes of EPLBD, because the results from each relevant article were based on different definitions. So we re-analyzed all gathered data by using a single standardized definition. An article of a large scaled multicenter study^[43] that included our institute, where the data of the patients undergoing EPLBD with and without EST were calculated as one, was re-analyzed using its raw data in order to re-group both of them separately. Another limitation is that most articles included in this review are not prospective controlled studies, but retrospective studies. Therefore, further large-scale prospective randomized controlled studies will be needed not only to confirm our claims on effectiveness of EPLBD with or without EST, compared with both of EST alone and EPBD alone, but to assess the facts which affect the outcome and adverse events of EPLBD. In conclusion, recent accumulated results of EPLBD with or even without EST suggest that it is a safe and effective procedure for the removal of large or difficult bile duct stones without any additional risk of

severe adverse events, when performed under appropriate guidelines.

ACKNOWLEDGMENTS

We would like to extend a special thanks to Dr. Soo Jung Park, Division of Gastroenterology, Department of Internal Medicine, Yonsei University College of Medicine, Seoul, South Korea for helping us to reanalyze the data of the large-scale multicenter study described in this review.

REFERENCES

- 1 **Classen M**, Demling L. Endoscopic sphincterotomy of the papilla of Vater and extraction of stones from the choledochal duct (author's transl). *Dtsch Med Wochenschr* 1974; **99**: 496-497 [PMID: 4835515 DOI: 10.1055/s-0028-1107790]
- 2 **Kawai K**, Akasaka Y, Murakami K, Tada M, Koli Y. Endoscopic sphincterotomy of the ampulla of Vater. *Gastrointest Endosc* 1974; **20**: 148-151 [PMID: 4825160]
- 3 **Cotton PB**, Lehman G, Vennes J, Geenen JE, Russell RC, Meyers WC, Liguory C, Nickl N. Endoscopic sphincterotomy complications and their management: an attempt at consensus. *Gastrointest Endosc* 1991; **37**: 383-393 [PMID: 2070995]
- 4 **Sherman S**, Ruffolo TA, Hawes RH, Lehman GA. Complications of endoscopic sphincterotomy. A prospective series with emphasis on the increased risk associated with sphincter of Oddi dysfunction and nondilated bile ducts. *Gastroenterology* 1991; **101**: 1068-1075 [PMID: 1889699]
- 5 **Boender J**, Nix GA, de Ridder MA, van Blankenstein M, Schütte HE, Dees J, Wilson JH. Endoscopic papillotomy for common bile duct stones: factors influencing the complication rate. *Endoscopy* 1994; **26**: 209-216 [PMID: 8026367 DOI: 10.1055/s-2007-1008945]
- 6 **Leung JW**, Chan FK, Sung JJ, Chung S. Endoscopic sphincterotomy-induced hemorrhage: a study of risk factors and the role of epinephrine injection. *Gastrointest Endosc* 1995; **42**: 550-554 [PMID: 8674926]
- 7 **Bergman JJ**, Rauws EA, Fockens P, van Berkel AM, Bossuyt PM, Tijssen JG, Tytgat GN, Huijbregtse K. Randomised trial of endoscopic balloon dilation versus endoscopic sphincterotomy for removal of bile duct stones. *Lancet* 1997; **349**: 1124-1129 [PMID: 9113010 DOI: 10.1016/S0140-6736(96)11026-6]
- 8 **Freeman ML**, Nelson DB, Sherman S, Haber GB, Herman ME, Dorsher PJ, Moore JP, Fennerty MB, Ryan ME, Shaw MJ, Lande JD, Pheley AM. Complications of endoscopic biliary sphincterotomy. *N Engl J Med* 1996; **335**: 909-918 [PMID: 8782497 DOI: 10.1056/NEJM199609263351301]

- 9 **Higuchi T**, Kon Y. Endoscopic mechanical lithotripsy for the treatment of common bile duct stone. Experience with the improved double sheath basket catheter. *Endoscopy* 1987; **19**: 216-217 [PMID: 3678165 DOI: 10.1055/s-2007-1013015]
- 10 **Moriai T**, Hasegawa T, Fuzita M, Kimura A, Tani T, Makino I. Successful removal of massive intragastric gallstones by endoscopic electrohydraulic lithotripsy and mechanical lithotripsy. *Am J Gastroenterol* 1991; **86**: 627-629 [PMID: 2028958]
- 11 **Hintze RE**, Adler A, Veltzke W. Outcome of mechanical lithotripsy of bile duct stones in an unselected series of 704 patients. *Hepatogastroenterology* 1996; **43**: 473-476 [PMID: 8799379]
- 12 **Staritz M**, Ewe K, Meyer zum Büschenfelde KH. [Endoscopic papillary dilatation: an alternative to papillotomy? (author's transl)]. *Dtsch Med Wochenschr* 1982; **107**: 895-897 [PMID: 7084054 DOI: 10.1055/s-2008-1070041]
- 13 **Mathuna PM**, White P, Clarke E, Merriman R, Lennon JR, Crowe J. Endoscopic balloon sphincteroplasty (papillary dilation) for bile duct stones: efficacy, safety, and follow-up in 100 patients. *Gastrointest Endosc* 1995; **42**: 468-474 [PMID: 8566640]
- 14 **Yasuda I**, Tomita E, Enya M, Kato T, Moriwaki H. Can endoscopic papillary balloon dilation really preserve sphincter of Oddi function? *Gut* 2001; **49**: 686-691 [PMID: 11600473 DOI: 10.1136/gut.49.5.686]
- 15 **Kozarek RA**. Balloon dilation of the sphincter of Oddi. *Endoscopy* 1988; **20** Suppl 1: 207-210 [PMID: 3168949 DOI: 10.1055/s-2007-1018177]
- 16 **Minami A**, Nakatsu T, Uchida N, Hirabayashi S, Fukuma H, Morshed SA, Nishioka M. Papillary dilation vs sphincterotomy in endoscopic removal of bile duct stones. A randomized trial with manometric function. *Dig Dis Sci* 1995; **40**: 2550-2554 [PMID: 8536511]
- 17 **Sato H**, Kodama T, Takaaki J, Tatsumi Y, Maeda T, Fujita S, Fukui Y, Ogasawara H, Mitsufuji S. Endoscopic papillary balloon dilatation may preserve sphincter of Oddi function after common bile duct stone management: evaluation from the viewpoint of endoscopic manometry. *Gut* 1997; **41**: 541-544 [PMID: 9391256 DOI: 10.1136/gut.41.4.541]
- 18 **Weinberg BM**, Shindy W, Lo S. Endoscopic balloon sphincter dilation (sphincteroplasty) versus sphincterotomy for common bile duct stones. *Cochrane Database Syst Rev* 2006; (4): CD004890 [PMID: 17054222 DOI: 10.1002/14651858.CD004890.pub2]
- 19 **Zhao HC**, He L, Zhou DC, Geng XP, Pan FM. Meta-analysis comparison of endoscopic papillary balloon dilatation and endoscopic sphincteroplasty. *World J Gastroenterol* 2013; **19**: 3883-3891 [PMID: 23840129 DOI: 10.3748/wjg.v19.i24.3883]
- 20 **Disario JA**, Freeman ML, Bjorkman DJ, Macmathuna P, Petersen BT, Jaffe PE, Morales TG, Hixson LJ, Sherman S, Lehman GA, Jamal MM, Al-Kawas FH, Khandelwal M, Moore JP, Derfus GA, Jamidar PA, Ramirez FC, Ryan ME, Woods KL, Carr-Locke DL, Alder SC. Endoscopic balloon dilation compared with sphincterotomy for extraction of bile duct stones. *Gastroenterology* 2004; **127**: 1291-1299 [PMID: 15520997 DOI: 10.1053/j.gastro.2004.07.017]
- 21 **Ersoz G**, Tekesin O, Ozutemiz AO, Gunsar F. Biliary sphincterotomy plus dilation with a large balloon for bile duct stones that are difficult to extract. *Gastrointest Endosc* 2003; **57**: 156-159 [PMID: 12556775 DOI: 10.1067/mge.2003.52]
- 22 **Hwang SJ**, Kim YG, Lee KC, Ji MK, Kim HS, Baik SG, Lee KM, Chang JH, Kim MS, Paik YH, Lee SJ, Park HJ, Lee KS, Lee SI, Lee DK. Endoscopic sphincterotomy plus endoscopic papillary large balloon dilatation for large bile duct stones [In Korean with English abstract]. *Korean J Gastrointest Endosc* 2006; **32**: 184-189
- 23 **Maydeo A**, Bhandari S. Balloon sphincteroplasty for removing difficult bile duct stones. *Endoscopy* 2007; **39**: 958-961 [PMID: 17701853 DOI: 10.1055/s-2007-966784]
- 24 **Minami A**, Hirose S, Nomoto T, Hayakawa S. Small sphincterotomy combined with papillary dilation with large balloon permits retrieval of large stones without mechanical lithotripsy. *World J Gastroenterol* 2007; **13**: 2179-2182 [PMID: 17465497]
- 25 **Heo JH**, Kang DH, Jung HJ, Kwon DS, An JK, Kim BS, Suh KD, Lee SY, Lee JH, Kim GH, Kim TO, Heo J, Song GA, Cho M. Endoscopic sphincterotomy plus large-balloon dilation versus endoscopic sphincterotomy for removal of bile-duct stones. *Gastrointest Endosc* 2007; **66**: 720-726, quiz 768, 771 [PMID: 17905013 DOI: 10.1016/j.gie.2007.02.033]
- 26 **Lee DK**, Lee BJ, Hwang SJ, Baik YH, Lee SJ. Endoscopic papillary large balloon dilation after endoscopic sphincterotomy for treatment of large common bile duct stone. *Digestive Endoscopy* 2007; **19**: S52-S56 [DOI: 10.1111/j.1443-1661.2007.00716.x]
- 27 **Kim MK**, Kim MH, Lee TY, Oh HC, Kwon SH, Han JH, Choi HO, Park SJ, Kim TH, Lee SS, Seo DW, Lee SK. Combined endoscopic sphincterotomy and large balloon sphincteroplasty for bile duct stones [In Korean with English abstract]. *Korean J Med* 2007; **73**: 474-480
- 28 **Lee SH**, Hong SW, Cho YD, Cheon YK, Kim SG, Jang JY, Kim YS, Moon JH, Lee JS, Lee MS, Shim CS, Kim BS. The safety and effectiveness of medium endoscopic sphincterotomy with endoscopic papillary large balloon dilation for removing difficult common bile duct stones [In Korean with English abstract]. *Korean J Gastrointest Endosc* 2007; **35**: 80-86
- 29 **Misra SP**, Dwivedi M. Large-diameter balloon dilation after endoscopic sphincterotomy for removal of difficult bile duct stones. *Endoscopy* 2008; **40**: 209-213 [PMID: 18264886 DOI: 10.1055/s-2007-967040]
- 30 **Attasaryana S**, Cheon YK, Vittal H, Howell DA, Wakelin DE, Cunningham JT, Ajmere N, Ste Marie Jr RW, Bhattacharya K, Gupta K, Freeman ML, Sherman S, McHenry L, Watkins JL, Fogel EL, Schmidt S, Lehman GA. Large-diameter biliary orifice balloon dilation to aid in endoscopic bile duct stone removal: a multicenter series. *Gastrointestinal Endoscopy* 2008; **67**: 1046-1052 [DOI: 10.1016/j.gie.2007.08.047]
- 31 **Espinel J**, Pinedo E. [Large balloon dilation for removal of bile duct stones]. *Rev Esp Enferm Dig* 2008; **100**: 632-636 [PMID: 19119789]
- 32 **Itoi T**, Itokawa F, Sofuni A, Kurihara T, Tsuchiya T, Ishii K, Tsuji S, Ikeuchi N, Moriyasu F. Endoscopic sphincterotomy combined with large balloon dilation can reduce the procedure time and fluoroscopy time for removal of large bile duct stones. *Am J Gastroenterol* 2009; **104**: 560-565 [PMID: 19174779 DOI: 10.1038/ajg.2008.67]
- 33 **Kim HG**, Cheon YK, Cho YD, Moon JH, Park do H, Lee TH, Choi HJ, Park SH, Lee JS, Lee MS. Small sphincterotomy combined with endoscopic papillary large balloon dilatation versus sphincterotomy. *World J Gastroenterol* 2009; **15**: 4298-4304 [PMID: 19750573 DOI: 10.3748/wjg.15.4298]
- 34 **Itoi T**, Sofuni A, Itokawa F, Kurihara T, Tsuchiya T, Ishii K, Tsuji S, Ikeuchi N, Umeda J, Moriyasu F. New large-diameter balloon-equipped sphincterotome for removal of large bile duct stones (with videos). *Gastrointest Endosc* 2010; **72**: 825-830 [PMID: 20883862 DOI: 10.1016/j.gie.2010.06.018]
- 35 **Kurita A**, Maguchi H, Takahashi K, Katanuma A, Osanai M. Large balloon dilation for the treatment of recurrent bile duct stones in patients with previous endoscopic sphincterotomy: preliminary results. *Scand J Gastroenterol* 2010; **45**: 1242-1247 [PMID: 20521873 DOI: 10.3109/00365521.2010.495420]
- 36 **Ghazanfar S**, Qureshi S, Leghari A, Taj MA, Niaz SK, Quraishy MS. Endoscopic balloon sphincteroplasty as an adjunct to endoscopic sphincterotomy in removing large and difficult bile duct stones. *J Pak Med Assoc* 2010; **60**: 1039-1042 [PMID: 21381560]
- 37 **Kim KO**, Kim TN, Lee SH. Endoscopic papillary large balloon dilation for the treatment of recurrent bile duct stones in patients with prior sphincterotomy. *J Gastroenterol* 2010; **45**:

- 1283-1288 [PMID: 20635102 DOI: 10.1007/s00535-010-0284-7]
- 38 **Youn YH**, Lim HC, Jahng JH, Jang SI, You JH, Park JS, Lee SJ, Lee DK. The increase in balloon size to over 15 mm does not affect the development of pancreatitis after endoscopic papillary large balloon dilatation for bile duct stone removal. *Dig Dis Sci* 2011; **56**: 1572-1577 [PMID: 20945093 DOI: 10.1007/s10620-010-1438-4]
- 39 **Kim TH**, Oh HJ, Lee JY, Sohn YW. Can a small endoscopic sphincterotomy plus a large-balloon dilation reduce the use of mechanical lithotripsy in patients with large bile duct stones? *Surg Endosc* 2011; **25**: 3330-3337 [PMID: 21533521 DOI: 10.1007/s00464-011-1720-3]
- 40 **Stefanidis G**, Viazis N, Pleskow D, Manolakopoulos S, Theocharis L, Christodoulou C, Kotsikoros N, Giannousis J, Sgouros S, Rodias M, Katsikani A, Chuttani R. Large balloon dilation vs. mechanical lithotripsy for the management of large bile duct stones: a prospective randomized study. *Am J Gastroenterol* 2011; **106**: 278-285 [PMID: 21045816 DOI: 10.1038/ajg.2010.421]
- 41 **Rebelo A**, Ribeiro PM, Correia AP, Cotter J. Endoscopic papillary large balloon dilation after limited sphincterotomy for difficult biliary stones. *World J Gastrointest Endosc* 2012; **4**: 180-184 [PMID: 22624069 DOI: 10.4253/wjge.v4.i5.180]
- 42 **Sakai Y**, Tsuyuguchi T, Sugiyama H, Nishikawa T, Kurosawa J, Saito M, Tawada K, Mikata R, Tada M, Ishihara T, Yokosuka O. Endoscopic sphincterotomy combined with large balloon dilation for removal of large bile duct stones. *Hepatogastroenterology* 2013; **60**: 58-64 [PMID: 22641109 DOI: 10.5754/hge12351]
- 43 **Park SJ**, Kim JH, Hwang JC, Kim HG, Lee DH, Jeong S, Cha SW, Cho YD, Kim HJ, Kim JH, Moon JH, Park SH, Itoi T, Isayama H, Kogure H, Lee SJ, Jung KT, Lee HS, Baron TH, Lee DK. Factors predictive of adverse events following endoscopic papillary large balloon dilation: results from a multicenter series. *Dig Dis Sci* 2013; **58**: 1100-1109 [PMID: 23225136 DOI: 10.1007/s10620-012-2494-8]
- 44 **Poincloux L**, Rouquette O, Privat J, Gorce D, Abergel A, Dapigny M, Bonnellaer G. Large-balloon dilation of the sphincter of Oddi after sphincterotomy or infundibulotomy to extract large calculi or multiple common bile duct stones without using mechanical lithotripsy. *Scand J Gastroenterol* 2013; **48**: 246-251 [PMID: 22229762 DOI: 10.3109/00365521.2011.647064]
- 45 **Hwang JC**, Kim JH, Lim SG, Kim SS, Shin SJ, Lee KM, Yoo BM. Endoscopic large-balloon dilation alone versus endoscopic sphincterotomy plus large-balloon dilation for the treatment of large bile duct stones. *BMC Gastroenterol* 2013; **13**: 15 [PMID: 23324454 DOI: 10.1186/1471-230X-13-15]
- 46 **Paspatis GA**, Konstantinidis K, Tribonias G, Voudoukis E, Tavernaraki A, Theodoropoulou A, Chainaki I, Manolaraki M, Chlouverakis G, Vardas E, Paraskeva K. Sixty- versus thirty-seconds papillary balloon dilation after sphincterotomy for the treatment of large bile duct stones: a randomized controlled trial. *Dig Liver Dis* 2013; **45**: 301-304 [PMID: 23195665 DOI: 10.1016/j.dld.2012.10.015]
- 47 **Rosa B**, Moutinho Ribeiro P, Rebelo A, Pinto Correia A, Cotter J. Endoscopic papillary balloon dilation after sphincterotomy for difficult choledocholithiasis: A case-controlled study. *World J Gastrointest Endosc* 2013; **5**: 211-218 [PMID: 23678373 DOI: 10.4253/wjge.v5.i5.211]
- 48 **Yang XM**, Hu B, Pan YM, Gao DJ, Wang TT, Wu J, Ye X. Endoscopic papillary large-balloon dilation following limited sphincterotomy for the removal of refractory bile duct stones: experience of 169 cases in a single Chinese center. *J Dig Dis* 2013; **14**: 125-131 [PMID: 23167553 DOI: 10.1111/1751-2980.12013]
- 49 **Yoon HG**, Moon JH, Choi HJ, Kim DC, Kang MS, Lee TH, Cha SW, Cho YD, Park SH, Kim SJ. Endoscopic papillary large balloon dilation for the management of recurrent difficult bile duct stones after previous endoscopic sphincterotomy. *Dig Endosc* 2013 Apr 14; Epub ahead of print [PMID: 23581623 DOI: 10.1111/den.12102]
- 50 **Harada R**, Maguchi H, Takahashi K, Katanuma A, Osanai M, Yane K, Hashigo S, Kaneko M, Katoh R, Katoh S. Large balloon dilation for the treatment of recurrent bile duct stones prevents short-term recurrence in patients with previous endoscopic sphincterotomy. *J Hepatobiliary Pancreat Sci* 2013; **20**: 498-503 [PMID: 23361432 DOI: 10.1007/s00534-012-0579-6]
- 51 **Jeong S**, Ki SH, Lee DH, Lee JI, Lee JW, Kwon KS, Kim HG, Shin YW, Kim YS. Endoscopic large-balloon sphincteroplasty without preceding sphincterotomy for the removal of large bile duct stones: a preliminary study. *Gastrointest Endosc* 2009; **70**: 915-922 [PMID: 19647241 DOI: 10.1016/j.gie.2009.04.042]
- 52 **Chan HH**, Lai KH, Lin CK, Tsai WL, Wang EM, Hsu PI, Chen WC, Yu HC, Wang HM, Tsay FW, Tsai CC, Chen IS, Chen YC, Liang HL, Pan HB. Endoscopic papillary large balloon dilation alone without sphincterotomy for the treatment of large common bile duct stones. *BMC Gastroenterol* 2011; **11**: 69 [PMID: 21668994 DOI: 10.1186/1471-230X-11-69]
- 53 **Oh MJ**, Kim TN. Prospective comparative study of endoscopic papillary large balloon dilation and endoscopic sphincterotomy for removal of large bile duct stones in patients above 45 years of age. *Scand J Gastroenterol* 2012; **47**: 1071-1077 [PMID: 22934594 DOI: 10.3109/00365521.2012.690046]
- 54 **Attam R**, Freeman ML. Endoscopic papillary large balloon dilation for large common bile duct stones. *J Hepatobiliary Pancreat Surg* 2009; **16**: 618-623 [PMID: 19551331 DOI: 10.1007/s00534-009-0134-2]
- 55 **Lee DK**, Han JW. Endoscopic papillary large balloon dilation: guidelines for pursuing zero mortality. *Clin Endosc* 2012; **45**: 299-304 [PMID: 22977823 DOI: 10.5946/ce.2012.45.3.299]
- 56 **Meine GC**, Baron TH. Endoscopic papillary large-balloon dilation combined with endoscopic biliary sphincterotomy for the removal of bile duct stones (with video). *Gastrointest Endosc* 2011; **74**: 1119-1126 [PMID: 21944309 DOI: 10.1016/j.gie.2011.06.042]
- 57 **Lee DK**, Jahng JH. Alternative methods in the endoscopic management of difficult common bile duct stones. *Dig Endosc* 2010; **22** Suppl 1: S79-S84 [PMID: 20590778 DOI: 10.1111/j.1443-1661.2010.00960.x]
- 58 **Lee DK**, Lee BJ. EST, EPBD, and EPLBD (Cut, Stretch, or Both?). In: Niwa H, Tajiri H, Nakajima M, Yasuda K. *New Challenges in Gastrointestinal Endoscopy*. Tokyo: Springer, 2008: 385-397
- 59 **Ustundag Y**, Ersoz G, Saritas U. Analysis of adverse events associated with endoscopic papillary large-balloon dilation. *Dig Dis Sci* 2013; **58**: 2426-2427 [PMID: 23812860 DOI: 10.1007/s10620-013-2741-7]
- 60 **Koruk I**, Parlak E, Seçilmiş S, Akdoğan M, Köklü S. Endoscopic sphincteroplasty with large balloon dilatation for extraction of difficult common bile duct stones. *Dig Dis Sci* 2008; **53**: 1737-1738 [PMID: 17940901 DOI: 10.1007/s10620-007-0060-6]
- 61 **Vila JJ**, Artifon EL. Endoscopic papillary large-balloon dilatation in patients with Billroth II gastrectomy. *Dig Dis Sci* 2013; **58**: 1452-1453 [PMID: 23543086 DOI: 10.1007/s10620-013-2650-9]
- 62 **Ozaslan E**. Endoscopic large balloon dilation after sphincterotomy: is perforation risk an alarming issue? *Dig Dis Sci* 2013; **58**: 1438 [PMID: 23504351 DOI: 10.1007/s10620-013-2615-z]
- 63 **Lee JH**. Is combination biliary sphincterotomy and balloon dilation a better option than either alone in endoscopic removal of large bile-duct stones? *Gastrointest Endosc* 2007; **66**: 727-729 [PMID: 17905014 DOI: 10.1016/j.gie.2007.03.1060]
- 64 **Lee YS**, Moon JH, Ko BM, Choi HJ, Cho YD, Park SH, Lee MS, Shim CS. Endoscopic closure of a distal common bile duct perforation caused by papillary dilation with a large-diameter balloon (with video). *Gastrointest Endosc* 2010; **72**:

- 616-618 [PMID: 20541195 DOI: 10.1016/j.gie.2010.02.034]
- 65 **Katsinelos P**, Fasoulas K, Beltsis A, Chatzimavroudis G, Zavos C, Terzoudis S, Kountouras J. Large-balloon dilation of the biliary orifice for the management of basket impaction: a case series of 6 patients. *Gastrointest Endosc* 2011; **73**: 1298-1301 [PMID: 21492853 DOI: 10.1016/j.gie.2011.01.034]
- 66 **Maroy B**. Life-threatening hemorrhage caused by balloon dilation after sphincterotomy for extraction of a large stone. *Endoscopy* 2011; **43** Suppl 2 UCTN: E94-E95 [PMID: 21425028 DOI: 10.1055/s-0030-1256026]
- 67 **Lee TH**, Park SH, Lee CK, Chung IK, Kim SJ, Kang CH. Life-threatening hemorrhage following large-balloon endoscopic papillary dilation successfully treated with angiographic embolization. *Endoscopy* 2009; **41** Suppl 2: E241-E242 [PMID: 19757375 DOI: 10.1055/s-0029-1214984]
- 68 **Lee JH**, Kang DH, Park JH, Kim MD, Yoon KT, Choi CW, Kim HW, Cho M. Endoscopic removal of a bile-duct stone using sphincterotomy and a large-balloon dilator in a patient with situs inversus totalis. *Gut Liver* 2010; **4**: 110-113 [PMID: 20479922 DOI: 10.5009/gnl.2010.4.1.110]
- 69 **Park SY**, Park CH, Yoon KW, Cho SB, Lee WS, Joo YE, Kim HS, Choi SK, Rew JS. Endoscopic large-diameter balloon dilation after fistulotomy for the removal of bile duct stones in a difficult cannulation. *Gastrointest Endosc* 2009; **69**: 955-959 [PMID: 19327486 DOI: 10.1016/j.gie.2008.12.048]
- 70 Abstracts of Digestive Disease Week and ASGE (American Society for Gastrointestinal Endoscopy) Annual Postgraduate Course, May 2007, Washington, DC, USA. *Gastrointest Endosc* 2007; **65**: AB90-A371 [PMID: 17536233 DOI: 10.1016/j.gie.2007.03.107]
- 71 **Bang S**, Kim MH, Park JY, Park SW, Song SY, Chung JB. Endoscopic papillary balloon dilation with large balloon after limited sphincterotomy for retrieval of choledocholithiasis. *Yonsei Med J* 2006; **47**: 805-810 [PMID: 17191309 DOI: 10.3349/ymj.2006.47.6.805]
- 72 **Kochhar R**, Dutta U, Shukla R, Nagi B, Singh K, Wig JD. Sequential endoscopic papillary balloon dilatation following limited sphincterotomy for common bile duct stones. *Dig Dis Sci* 2009; **54**: 1578-1581 [PMID: 19005760 DOI: 10.1007/s10620-008-0534-1]
- 73 **Draganov PV**, Evans W, Fazel A, Forsmark CE. Large size balloon dilation of the ampulla after biliary sphincterotomy can facilitate endoscopic extraction of difficult bile duct stones. *J Clin Gastroenterol* 2009; **43**: 782-786 [PMID: 19318979 DOI: 10.1097/MCG.0b013e31818f50a2]
- 74 **Martín-Arranz E**, Rey-Sanz R, Martín-Arranz MD, Gea-Rodríguez F, Mora-Sanz P, Segura-Cabral JM. Safety and efficacy of large balloon sphincteroplasty in a third care hospital. *Rev Esp Enferm Dig* 2012; **104**: 355-359 [PMID: 22849496]
- 75 **García-Cano J**, Arana LT, Ayllón CJ, Chicano MV, Fernández RM, Sánchez LS, Ruiz CJ, xAriño MJ, García JI, Vígara MG, Cerezo ER, Sola AP. Biliary sphincterotomy dilation for the extraction of difficult common bile duct stones. *Rev Esp Enferm Dig* 2009; **101**: 541-545 [PMID: 19785493]
- 76 **Kim HW**, Kang DH, Choi CW, Park JH, Lee JH, Kim MD, Kim ID, Yoon KT, Cho M, Jeon UB, Kim S, Kim CW, Lee JW. Limited endoscopic sphincterotomy plus large balloon dilation for choledocholithiasis with periampullary diverticula. *World J Gastroenterol* 2010; **16**: 4335-4340 [PMID: 20818818]
- 77 **Kim GH**, Kang DH, Song GA, Heo J, Park CH, Ha TI, Kim KY, Lee HJ, Kim ID, Choi SH, Song CS. Endoscopic removal of bile-duct stones by using a rotatable papillotome and a large-balloon dilator in patients with a Billroth II gastrectomy (with video). *Gastrointest Endosc* 2008; **67**: 1134-1138 [PMID: 18407269 DOI: 10.1016/j.gie.2007.12.016]
- 78 **Itoi T**, Ishii K, Itokawa F, Kurihara T, Sofuni A. Large balloon papillary dilation for removal of bile duct stones in patients who have undergone a billroth ii gastrectomy. *Dig Endosc* 2010; **22** Suppl 1: S98-S102 [PMID: 20590782 DOI: 10.3748/wjg.v16.i34.4335]
- 79 **Kim TN**, Lee SH. Endoscopic Papillary Large Balloon Dilation Combined with Guidewire-Assisted Precut Papillotomy for the Treatment of Choledocholithiasis in Patients with Billroth II Gastrectomy. *Gut Liver* 2011; **5**: 200-203 [PMID: 21814601 DOI: 10.5009/gnl.2011.5.2.200]
- 80 **Choi CW**, Choi JS, Kang DH, Kim BG, Kim HW, Park SB, Yoon KT, Cho M. Endoscopic papillary large balloon dilation in Billroth II gastrectomy patients with bile duct stones. *J Gastroenterol Hepatol* 2012; **27**: 256-260 [PMID: 21793902 DOI: 10.1111/j.1440-1746.2011.06863.x]
- 81 **Jang HW**, Lee KJ, Jung MJ, Jung JW, Park JY, Park SW, Song SY, Chung JB, Bang S. Endoscopic papillary large balloon dilatation alone is safe and effective for the treatment of difficult choledocholithiasis in cases of Billroth II gastrectomy: a single center experience. *Dig Dis Sci* 2013; **58**: 1737-1743 [PMID: 23392745 DOI: 10.1007/s10620-013-2580-6]
- 82 **Itoi T**, Ishii K, Sofuni A, Itokawa F, Kurihara T, Tsuchiya T, Tsuji S, Ikeuchi N, Umeda J, Tanaka R, Moriyasu F. Large balloon dilatation following endoscopic sphincterotomy using a balloon enteroscope for the bile duct stone extractions in patients with Roux-en-Y anastomosis. *Dig Liver Dis* 2011; **43**: 237-241 [PMID: 20947457 DOI: 10.1016/j.dld.2010.09.002]
- 83 **Kim JH**, Kim YS, Kim DK, Ha MS, Lee YJ, Lee JJ, Lee SJ, Won IS, Ku YS, Kim YS, Kim JH. Short-term Clinical Outcomes Based on Risk Factors of Recurrence after Removing Common Bile Duct Stones with Endoscopic Papillary Large Balloon Dilatation. *Clin Endosc* 2011; **44**: 123-128 [PMID: 22741123 DOI: 10.5946/ce.2011.44.2.123]
- 84 **Ha DW**, Song GA, Kim DU, Kim GH, Heo J, Lee HW, Cho EJ, Jeon HK. [Recurrent common bile duct stone and endoscopic treatment after endoscopic papillary large balloon dilatation with minor endoscopic sphincterotomy]. *Korean J Gastroenterol* 2011; **57**: 352-357 [PMID: 21694487]
- 85 **Kim KH**, Rhu JH, Kim TN. Recurrence of bile duct stones after endoscopic papillary large balloon dilation combined with limited sphincterotomy: long-term follow-up study. *Gut Liver* 2012; **6**: 107-112 [PMID: 22375179 DOI: 10.5009/gnl.2012.6.1.107]
- 86 **Lee JW**, Kim JH, Kim YS, Choi HS, Kim JS, Jeong SH, Ha MS, Ku YS, Kim YS, Kim JH. [The effect of periampullary diverticulum on the outcome of bile duct stone treatment with endoscopic papillary large balloon dilation]. *Korean J Gastroenterol* 2011; **58**: 201-207 [PMID: 22042420]
- 87 **Espinell J**, Pinedo E, Olcoz JL. [Large hydrostatic balloon for choledocholithiasis]. *Rev Esp Enferm Dig* 2007; **99**: 33-38 [PMID: 17295596]
- 88 **Hochberger J**, Tex S, Maiss J, Hahn EG. Management of difficult common bile duct stones. *Gastrointest Endosc Clin N Am* 2003; **13**: 623-634 [PMID: 14986790]
- 89 **Binmoeller KF**, Brückner M, Thonke F, Soehendra N. Treatment of difficult bile duct stones using mechanical, electrohydraulic and extracorporeal shock wave lithotripsy. *Endoscopy* 1993; **25**: 201-206 [PMID: 8519238 DOI: 10.1055/s-2007-1010293]
- 90 **Gupta N**, Poreddy V, Al-Kawas F. Endoscopy in the management of choledocholithiasis. *Curr Gastroenterol Rep* 2008; **10**: 169-176 [PMID: 18462604]
- 91 **Wojtun S**, Gil J, Gietka W, Gil M. Endoscopic sphincterotomy for choledocholithiasis: a prospective single-center study on the short-term and long-term treatment results in 483 patients. *Endoscopy* 1997; **29**: 258-265 [PMID: 9255528 DOI: 10.1055/s-2007-1004186]
- 92 **Sivak MV**. Endoscopic management of bile duct stones. *Am J Surg* 1989; **158**: 228-240 [PMID: 2672845]
- 93 **Gutiérrez-Bermúdez JA**, Adalid-Martínez R, Güitrón-Cantú A. [Endoscopic mechanical lithotripsy in choledocholithiasis of difficult extraction handling]. *Rev Gastroenterol Mex* 2006; **71**: 16-21 [PMID: 17063570]
- 94 **Kudrevatykh IP**, Shchetinin VN. [Endoscopic mechanical lithotripsy in the treatment of choledocholithiasis]. *Vestn*

- Khir Im I I Grek* 2001; **160**: 19-20 [PMID: 11836992]
- 95 **Cohello R**, Bordas JM, Guevara MC, Liach J, Mondelo F, Ginès A, Terés J. [Mechanical lithotripsy during retrograde cholangiography in choledocholithiasis untreatable by conventional endoscopic sphincterotomy]. *Gastroenterol Hepatol* 1997; **20**: 124-127 [PMID: 9162531]
- 96 **Cipolletta L**, Costamagna G, Bianco MA, Rotondano G, Piscopo R, Mutignani M, Marmo R. Endoscopic mechanical lithotripsy of difficult common bile duct stones. *Br J Surg* 1997; **84**: 1407-1409 [PMID: 9361600]
- 97 **Vij JC**, Jain M, Rawal KK, Gulati RA, Govil A. Endoscopic management of large bile duct stones by mechanical lithotripsy. *Indian J Gastroenterol* 1995; **14**: 122-123 [PMID: 8868351]
- 98 **Leung JW**, Tu R. Mechanical lithotripsy for large bile duct stones. *Gastrointest Endosc* 2004; **59**: 688-690 [PMID: 15114312]
- 99 **Shaw MJ**, Mackie RD, Moore JP, Dorsher PJ, Freeman ML, Meier PB, Potter T, Hutton SW, Vennes JA. Results of a multicenter trial using a mechanical lithotripter for the treatment of large bile duct stones. *Am J Gastroenterol* 1993; **88**: 730-733 [PMID: 8480739]
- 100 **Shim CS**. Balloon dilation of the native and postsphincterotomy papilla. In: Baron TH, Kozarek RA, Carr-Locke DL. ERCP. Philadelphia: Elsevier Saunders, 2013: 139-151
- 101 **Akashi R**, Kiyozumi T, Tanaka T, Sakurai K, Oda Y, Sagara K. Mechanism of pancreatitis caused by ERCP. *Gastrointest Endosc* 2002; **55**: 50-54 [PMID: 11756914 DOI: 10.1067/mge.2002.118964]

P- Reviewers: Coskun A, Lakatos PL **S- Editor:** Cui XM
L- Editor: A **E- Editor:** Wu HL





百世登

Baishideng®

Published by **Baishideng Publishing Group Co., Limited**

Flat C, 23/F., Lucky Plaza,

315-321 Lockhart Road, Wan Chai, Hong Kong, China

Fax: +852-65557188

Telephone: +852-31779906

E-mail: bpgoffice@wjgnet.com

<http://www.wjgnet.com>



ISSN 1007-9327



9 771007 932045