

Reciprocal Deletion and Duplication of 17p11.2-11.2: Korean Patients with Smith-Magenis Syndrome and Potocki-Lupski Syndrome

Cha Gon Lee¹, Sang-Jin Park²,
Jun-No Yun³, Shin-Young Yim⁴,
and Young Bae Sohn³

¹Department of Pediatrics, Eulji General Hospital, Seoul; ²MG MED, Inc., Seoul; ³Department of Medical Genetics, ⁴Department of Physical Medicine and Rehabilitation, Ajou University School of Medicine, Suwon, Korea

Received: 4 June 2012
Accepted: 14 August 2012

Address for Correspondence:
Young Bae Sohn, MD
Department of Medical Genetics, Ajou University School of Medicine, 164 World cup-ro, Yeongtong-gu, Suwon 443-721, Korea
Tel: +82.31-219-4522, Fax: +82.31-219-4521
E-mail: ybsohn@ajou.ac.kr

Deletion and duplication of the -3.7-Mb region in 17p11.2 result in two reciprocal syndromes, Smith-Magenis syndrome and Potocki-Lupski syndrome. Smith-Magenis syndrome is a well-known developmental disorder. Potocki-Lupski syndrome has recently been recognized as a microduplication syndrome that is a reciprocal disease of Smith-Magenis syndrome. In this paper, we report on the clinical and cytogenetic features of two Korean patients with Smith-Magenis syndrome and Potocki-Lupski syndrome. Patient 1 (Smith-Magenis syndrome) was a 2.9-yr-old boy who showed mild dysmorphic features, aggressive behavioral problems, and developmental delay. Patient 2 (Potocki-Lupski syndrome), a 17-yr-old boy, had only intellectual disabilities and language developmental delay. We used array comparative genomic hybridization (array CGH) and found a 2.6 Mb-sized deletion and a reciprocal 2.1 Mb-sized duplication involving the 17p11.2. These regions overlapped in a 2.1 Mb size containing 11 common genes, including *RAI1* and *SREBF*.

Key Words: Array-CGH; 17p11.2; Deletion; Duplication; Potocki-Lupski Syndrome (PTLS); Smith-Magenis Syndrome (SMS)

INTRODUCTION

A number of common contiguous gene syndromes arise from a nonallelic homologous recombination mechanism. This can cause a loss or increase in the copy number of genes within the deleted or duplicated region. It can also contribute to the copy number variation seen in some gene clusters (1). Deletion and duplication of the -3.7-Mb region in 17p11.2 result in two reciprocal syndromes, Smith-Magenis syndrome (SMS, OMIM #182290) and Potocki-Lupski syndrome (PTLS, OMIM #610883) (2, 3). SMS is caused by a deletion or loss of genetic material on one copy of chromosome 17p11.2. This disorder is a well known and complex neurobehavioral disorder characterized by moderate intellectual disability, distinctive facial features, sleep disturbances, and behavioral problems (4). In contrast, PTLS, also referred to as duplication 17p11.2 syndrome, has recently been recognized as a reciprocal microduplication disease of SMS. Patients with PTLS show infantile hypotonia, sleep apnea, structural cardiovascular anomalies, learning disabilities, attention-deficit disorder, obsessive-compulsive behaviors, malocclusions, short stature, and failure to thrive (5). In this paper, we report the clinical and cytogenetic features of two Korean patients with reciprocal deletion and duplication of 17p11.2.

CASE DESCRIPTION

Patient 1

A 2.9-yr-old boy visited our clinical geneticist with developmental language delay on February 23th, 2012. He was born at week 41 of gestation age by spontaneous vaginal delivery after an unremarkable pregnancy as the first child of healthy non-consanguineous Korean parents. His birth weight was 2,960 g (10-25th percentile), birth length 51 cm (50-75th percentile), and head circumference was 32 cm (3-10th percentile). The mother and father were, respectively, 28 and 31 yr old. The family had no history of neurologic disease or developmental delay. No feeding difficulties or hypotonia occurred during early infancy. He showed normal development until the age of 3-4 months. His mother reported that his development seemed to be delayed since the age of 12 months. He walked independently at 18 months. He did not speak his first words until he was 12 months old. He showed no autistic features or sleep problems. He was unable to adapt to socially acceptable behavior at kindergarten. He showed aggressive behavior and picked on his friends. There was no history of seizure at the moment.

When he visited our clinic as a 2.9-yr-old, his body weight was 12.3 kg (-1.05, standard deviation score, SDS), height was 87.8

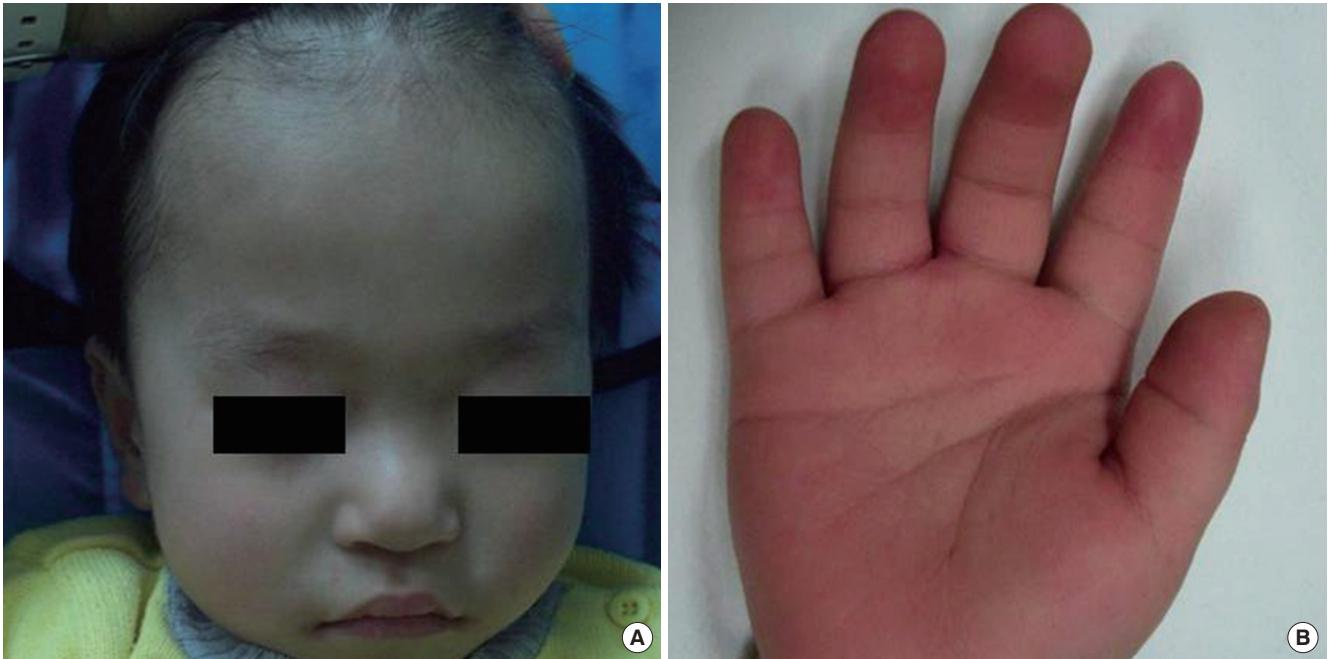

Fig. 1. Patient 1 showed broad forehead and downturned upper lip (A). Brachydactyly was noted (B).

cm (-1.16 SDS), body mass index (BMI) was 15.96 kg/m² (-0.62 SDS), and head circumference was 50 cm (-1.19 SDS). On examination, he was noted to have a broad forehead, brachycephaly, and downturned upper lip but had no dysmorphic features or other significant findings (Fig. 1A). Eye examination was normal. His oral cavity and oropharynx were unremarkable. Extremities showed shortness of the fingers (Fig. 1B). He was alert and made good eye contact. The other neurologic examination was normal.

He underwent a neurodevelopmental evaluation at 3 yr of age. He exhibited inattentive and uncooperative behavior during the tests. He revealed the cognitive function of an 18-month-old on Bayley Scales of Infant Development II. His social quotient (SQ) was 60.6 on social maturity scale (SMS). He revealed developmental language delay determined by the sequenced language scale of infants (SELSI); expressive language function was at the level of an 18-month-old, and receptive language function was at the 12-month-old level. Adaptive skill was checked with the Developmental Age Referenced Breakdown Assessment Schedules (DARBAS). He showed a lower level of adaptive behaviors; he had the activities of daily living (ADL) functional age of a 19-month-old, fine motor functional age of a 20-month-old, and a cognitive functional age of 16.6 months.

His hearing test (otoacoustic emissions test) was normal. The laboratory tests including complete blood count, chemistry panel, lipid profile, thyroid function test, and urinalysis were all normal. Electrocardiography and chest radiograph were normal. Brain magnetic resonance imaging (MRI) was normal, without ventriculomegaly.

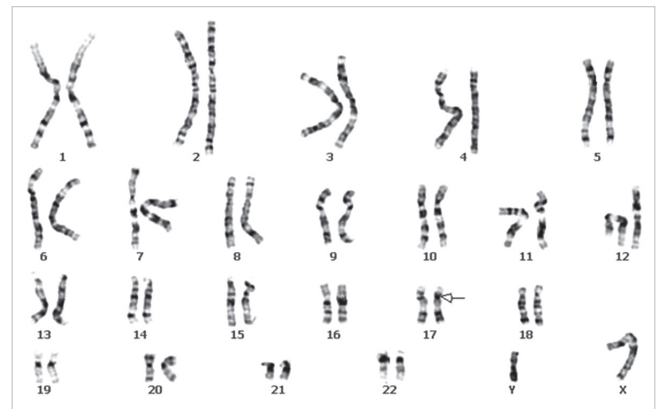


Fig. 2. G-banded karyotype of patient 1 revealed 46, XY, del (17) (p11.2p11.2).

Chromosome analysis revealed a deletion within the short arm of chromosome 7, with breakpoints of p11.2 and p11.2 at least 550-band resolution (Fig. 2). We conducted whole genome array comparative genomic hybridization (array CGH) using commercially available array-CGH slides (MACArray Karyo 1440 BAC-chip, MacroGen, Seoul, Korea) to confirm the suspected cytogenetic findings. We found a 2.6 Mb deletion on chromosome 17p11.2 (Fig. 3). The start and stop points of this deletion were estimated at 17,083,225 and 19,654,341 (GRCh37 February 2009 assembly) with a total of 5 probes: BAC90_H16, BAC-249_G12, BAC41_D18, BAC132_L20, and BAC10_I20. The 2.57 Mb region contained 15 RefSeq (NCBI reference sequence) genes: *MPRIIP* [MIM 612935], *PLD6*, *FLCN* [MIM 607273], *COPS3* [MIM 604665], *RAI1* [MIM 607642], *SMCR5*, *SREBF1* [MIM 184756],

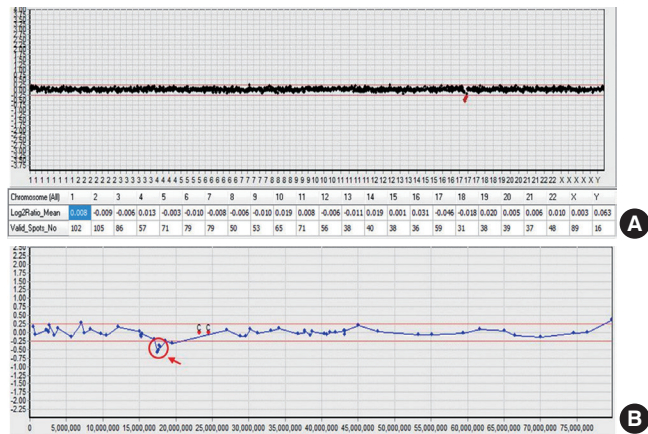


Fig. 3. Array CGH result of patient 1. (A) Array CGH data profile in whole chromosomes. A dot represents a bacterial artificial chromosome (BAC) clone, X-axis represents chromosome number (1-22, X, Y) and the Y-axis represents the \log_2 T/R signal ratio value. The table below the graph represents the average \log_2 T/R signal ratio value for each chromosome. Red dots represent a copy number loss (\log_2 T/R signal ratio value < -0.25) and deletion on chromosome 17. (B) Array CGH profile from chromosome 17 showed a deletion on the short arm, internal boundaries of the deletion in 17p11.2 (17,083,225-19,654,341), and its exact size (2.6 Mb) including *RAI1* gene region.

MIR33B [MIM 613486], *TOM1L2*, *TRIM16L*, *FBXW10* [MIM 611679], *FAM18B*, *ALDH3A2* [MIM 609523], *SLC47A* [MIM 609833], and *ALDH3A1* [MIM 100660].

Patient 2

A 17-yr-old boy revisited the hospital for rehabilitation and was referred to our genetic clinic for an evaluation of unexplained intellectual disability and language disability on July 11th, 2011. He had been delivered at week 36 of gestation by vaginal delivery after an induced preterm birth due to preeclampsia and intrauterine growth retardation. His birth weight was 1,500 g (< 3 rd percentile). He spent about 25 days in the neonatal intensive care unit (NICU) for very low birth weight. The mother and father were both 33 yr old. He had an older healthy brother. The family had no history of neurologic disease or developmental delay. His parents reported that he was rather slow to walk (18 months). He had obvious language development after 3 yr old. He showed no autistic features, sleep problems, hyperactivity, or oppositional behaviors. He had two provoked seizures; his first seizure at the age of 3.5 yr was associated with hypoglycemia (serum glucose 38 mg/dL) and his second seizure occurred at the age of 7 yr during a high fever.

On physical examination at 17 yr, he showed no definite dysmorphic facial features or other significant findings. His dominant hand was left. His heart sound was normal without murmurs. No skeletal abnormalities were noted. His neurologic examination was normal.

His first neurodevelopmental evaluation was checked at age 3.5 yr. At that time (3.5 yr old), he showed mild intellectual disability, a low level of adaptive behaviors, and significant developmental language delay; his ADL functional age was 33.6 months,

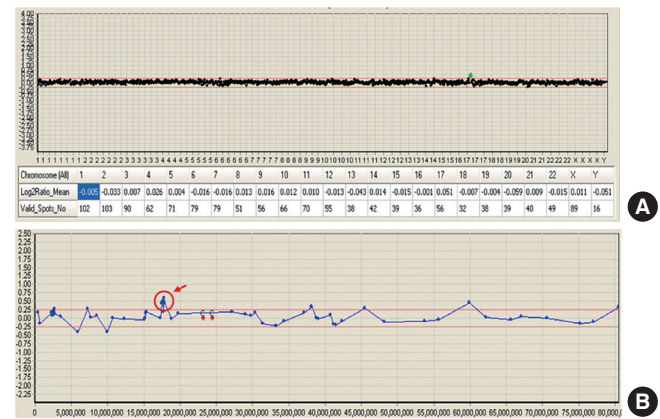


Fig. 4. Array CGH result of patient 2. (A) Array CGH data profile in whole chromosomes. Green dots represent a copy number gain (\log_2 T/R signal ratio value > 0.25) and duplication on chromosome 17. (B) Array CGH profile from chromosome 17 showed a duplication on the short arm, internal boundaries of the duplication in 17p11.2 (17,575,978-19,654,341), and its exact size (2.1 Mb).

his fine motor functional age was 30.07 months, his cognitive functional age was 21.44 months on the DARBAS, his receptive language age was 24 months, and his expressive language age was 18-24 months on the PRES. He underwent a second neurodevelopmental evaluation at age 17 yr. His intellectual functioning was measured by the Korean Wechsler Adult Intelligence Scale (K-WAIS). He had a moderate intellectual disability; FSIQ, VIQ, and PIQ were all below 45. His social maturation quotient (SQ 48.7) also showed a moderate trainable intellectual disability. He still exhibited developmental language delay, with a receptive language age of 5 yr and an expressive language age of around 3 yr.

Laboratory tests, which included a complete blood count, chemistry panel, lipid profile, thyroid function test, and urinalysis, were all normal. Brain MRI showed no focal lesion and a normal ventricular size (17 yr old).

He underwent a chromosome analysis at another hospital. The result of a blood lymphocyte karyotype was 46, XY. We performed whole genome array CGH (MACArray Karyo 1440 BAC-chip, MacroGen, Seoul, Korea), which revealed a duplication on chromosome 17p11.2 including the *RAI1* gene region [$\text{arr } 17\text{p}11.2 (17,575,978-19,654,341) \times 3$] (Fig. 4). The size was estimated at approximately 2.1 Mb with 4 probes that contained 11 RefSeq genes: *RAI1* [MIM 607642], *SMCR5*, *SREBF1* [MIM 184756], *MIR33B* [MIM 613486], *TOM1L2*, *TRIM16L*, *FBXW10* [MIM 611679], *FAM18B*, *ALDH3A2* [MIM 609523], *SLC47A* [MIM 609833], and *ALDH3A1* [MIM 100660].

DISCUSSION

Clinically, both the SMS and the PTLs syndromes are associated with nonspecific developmental delay, language impairment, and intellectual disability. Typically, besides intellectual disability, SMS is characterized by self-injurious behaviors, sleep

disturbance, obesity, and craniofacial/skeletal anomalies. The SMS clinical phenotype is rarely evident before late childhood. With increasing age, the dysmorphic features become apparent (6). In contrast, PTLs presents as a milder syndrome than SMS, with distinct characteristics including infantile hypotonia, sleep apnea, structural cardiovascular anomalies, autistic features, and failure to thrive. In our cases, both of our patients showed developmental language delay and intellectual disability. Although patient 1 was too young to show full expression of clinical features, he showed mildly dysmorphic features including a broad, square-shaped forehead, brachycephaly, an outward-curving upper lip, and brachydactyly. Despite his relatively older age, patient 2 had no definite dysmorphic features. Patient 1 revealed frequent temper tantrums, aggression behavior, and difficulty paying attention. However, patient 2 showed no definite behavioral problems. In spite of similarly sized gene dosage changes, patient 2 exhibited a milder phenotype.

Chromosome 17 has the second highest gene content among all chromosomes (7). It contains several dosage-sensitive genes such as *PMP22*, *PAFAH1B1*, *YWHAE*, *RAI1*, and *NF1*, which have been implicated in a number of genomic disorders (8). Several reciprocal deletion/duplication syndromes of chromosome 17 are associated with these dosage sensitive genes, including SMS and PTLs, which are also known as reciprocal microdeletion and microduplication of chromosome 17p11.2. Most SMS deletions and reciprocal duplications have common breakpoints, although deletions and duplications of different sizes have been identified. Both appear to involve a common 1.3-3.7 Mb chromosome section in 17p11.2 that includes the *RAI1* gene (5, 8, 9). Previous studies (10-13) have provided evidence that the number of *RAI1* copies is most likely responsible for these syndromes. Thus, *RAI1* is believed to represent the critical gene involved in these diseases. However, since no cases of *RAI1* duplication alone have been identified, this hypothesis requires further supporting evidence. Other candidate genes have been identified within the duplicated section, including *SREBF1* [MIM 184756], *DRG2* [MIM 602986], *LLGL1* [MIM 600966], *SHMT1* [MIM 182144], *MFAP4* [MIM 600596], and *TTC19* [MIM 613814], located within and flanking the SMS common deletion region (13). Our cases represent two patients with similarly sized overlapping locations of deletion and duplication; a 2.6 Mb deletion (17,083,225-19,654,341) and a reciprocal 2.1 Mb duplication (17,575,978-19,654,341) on chromosome 17p11.2 (Fig. 5). These regions contained dosage changes of common 11 RefSeq genes included the well-known dosage sensitive genes, *RAI1* [MIM 607642] and *SREBF1* [MIM 184756]. This raised doubts as to whether *RAI1* [MIM 607642] and *SREBF1* [MIM 184756] were disease-causing genes responsible for the phenotype of our patients.

Although reciprocal duplications may occur at the same frequency as deletions, only a few reciprocal deletion/duplication

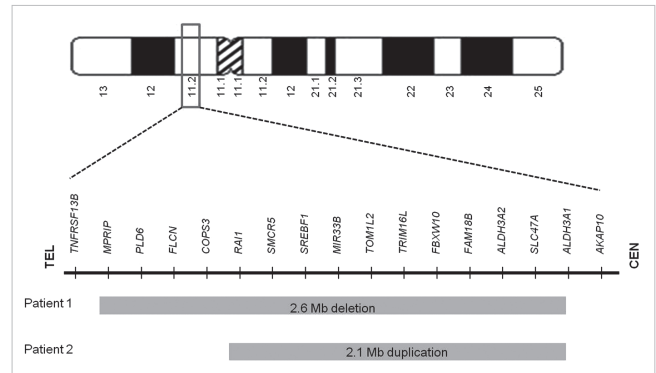


Fig. 5. Schematic diagram of breakpoints for genes/regions on chromosome 17p11.2 of patient 1 and 2.

syndromes have been reported. In general, patients with duplications will exhibit a significantly milder phenotype when compared to patients with deletions. In addition, G-banded duplications are more difficult to identify compared to deletions (2). Estimates of the incidence of SMS are 1 in 20,000-25,000 individuals, whereas fewer than 50 persons with PTLs have been reported in the medical literature (14, 15). In Korea, several reports of SMS have been published (16-18). However, to our knowledge, patient 2 was only the second case report of clinical features with PTLs.

Current technological advances in cytogenetics, and specifically the use of array CGH for genetic diagnosis, now allow microdeletions and microduplications to be detected with equal efficacy. Array CGH has recently become a popular tool in the clinical field in Korea. We anticipate that more patients with PTLs will be detected using array CGH in persons with unexplained developmental delay, intellectual disability, and/or autism spectrum disorder.

REFERENCES

- Morrow EM. Genomic copy number variation in disorders of cognitive development. *J Am Acad Child Adolesc Psychiatry* 2010; 49: 1091-104.
- Shaw CJ, Bi W, Lupski JR. Genetic proof of unequal meiotic crossovers in reciprocal deletion and duplication of 17p11.2. *Am J Hum Genet* 2002; 71: 1072-81.
- Bi W, Park SS, Shaw CJ, Withers MA, Patel PI, Lupski JR. Reciprocal crossovers and a positional preference for strand exchange in recombination events resulting in deletion or duplication of chromosome 17p11.2. *Am J Hum Genet* 2003; 73: 1302-15.
- Gropman AL, Duncan WC, Smith AC. Neurologic and developmental features of the Smith-Magenis syndrome (del 17p11.2). *Pediatr Neurol* 2006; 34: 337-50.
- Potocki L, Bi W, Treadwell-Deering D, Carvalho CM, Eifert A, Friedman EM, Glaze D, Krull K, Lee JA, Lewis RA, et al. Characterization of Potocki-Lupski syndrome (dup(17)(p11.2p11.2)) and delineation of a dosage-sensitive critical interval that can convey an autism phenotype. *Am J Hum Genet* 2007; 80: 633-49.

6. Jones KL, Smith DW. *Smith's recognizable patterns of human malformation*. 6th edition. Philadelphia: Elsevier Saunders, 2005, p.210-2.
7. Zody MC, Garber M, Adams DJ, Sharpe T, Harrow J, Lupski JR, Nicholson C, Searle SM, Wilming L, Young SK, et al. *DNA sequence of human chromosome 17 and analysis of rearrangement in the human lineage*. *Nature* 2006; 440: 1045-9.
8. Shchelochkov OA, Cheung SW, Lupski JR. *Genomic and clinical characteristics of microduplications in chromosome 17*. *Am J Med Genet A* 2010; 152A: 1101-10.
9. Zhang F, Potocki L, Sampson JB, Liu P, Sanchez-Valle A, Robbins-Furman P, Navarro AD, Wheeler PG, Spence JE, Brasington CK, et al. *Identification of uncommon recurrent Potocki-Lupski syndrome-associated duplications and the distribution of rearrangement types and mechanisms in PTLs*. *Am J Hum Genet* 2010; 86: 462-70.
10. Walz K, Spencer C, Kaasik K, Lee CC, Lupski JR, Paylor R. *Behavioral characterization of mouse models for Smith-Magenis syndrome and dup(17)(p11.2p11.2)*. *Hum Mol Genet* 2004; 13: 367-78.
11. Edelman EA, Girirajan S, Finucane B, Patel PI, Lupski JR, Smith AC, Elsea SH. *Gender, genotype, and phenotype differences in Smith-Magenis syndrome: a meta-analysis of 105 cases*. *Clin Genet* 2007; 71: 540-50.
12. Walz K, Paylor R, Yan J, Bi W, Lupski JR. *Rai1 duplication causes physical and behavioral phenotypes in a mouse model of dup(17)(p11.2p11.2)*. *J Clin Invest* 2006; 116: 3035-41.
13. Molina J, Carmona-Mora P, Chrast J, Krall PM, Canales CP, Lupski JR, Raymond A, Walz K. *Abnormal social behaviors and altered gene expression rates in a mouse model for Potocki-Lupski syndrome*. *Hum Mol Genet* 2008; 17: 2486-95.
14. Madduri N, Peters SU, Voigt RG, Llorente AM, Lupski JR, Potocki L. *Cognitive and adaptive behavior profiles in Smith-Magenis syndrome*. *J Dev Behav Pediatr* 2006; 27: 188-92.
15. Hamosh A, Scott AF, Amberger JS, Bocchini CA, McKusick VA. *Online Mendelian Inheritance in Man (OMIM), a knowledgebase of human genes and genetic disorders*. *Nucleic Acids Res* 2005; 33: D514-D7.
16. Jung SK, Park KH, Shin HK, Eun SH, Eun BL, Yoo KH, Hong YS, Lee JW, Bae SY. *Two cases of Smith-Magenis syndrome*. *Korean J Pediatr* 2009; 52: 701-4.
17. Suk JH, Lee SG, Bae JC, Lee HJ, Kim SH. *Two Cases of Smith-Magenis Syndrome with Tetralogy of Fallot Confirmed by FISH*. *Korean J Lab Med* 2005; 25: 361-4.
18. Cho EH, Park BYN, Cho JH, Kang YS. *Comparing two diagnostic laboratory tests for several microdeletions causing mental retardation syndromes: multiplex ligation-dependent amplification vs fluorescent in situ hybridization*. *Korean J Lab Med* 2009; 29: 71-6.