


# Reconstruction of chronic tibialis anterior tendon ruptures using a free anterior half of a peroneus longus tendon autograft: A technical note

Journal of Orthopaedic Surgery  
30(1) 1–8  
© The Author(s) 2022  
Article reuse guidelines:  
[sagepub.com/journals-permissions](https://sagepub.com/journals-permissions)  
DOI: 10.1177/10225536221083044  
[journals.sagepub.com/home/osj](https://journals.sagepub.com/home/osj)  


Sung Jae Kim<sup>1,\*</sup>, Young Uk Park<sup>2,\*</sup>, Joong Taek Ahn<sup>3</sup> and Hyong Nyun Kim<sup>3</sup> 

## Abstract

**Purpose:** Chronic rupture of the tibialis anterior (TA) tendon is rare. Several reconstruction techniques have been introduced. However, to the best of our knowledge, the use of a free anterior half of a peroneus longus tendon (AHPLT) autograft has not been reported for reconstruction of TA tendon rupture. This study aimed to describe the surgical technique and present the clinical outcomes of reconstruction of the chronic TA tendon ruptures using an AHPLT autograft. **Methods:** Between September 2013 and April 2019, five patients with chronic TA tendon rupture were surgically treated by reconstruction using an AHPLT autograft. The AHPLT could be easily harvested percutaneously with a tendon stripper from the ipsilateral lower leg around the reconstruction site. The study included four men and one woman, with a mean age of 43.8 (range: 23–65) years. **Results:** At a mean follow-up period of 42.8 (range: 12–70) months, the mean Foot Function Index value significantly improved from  $53.6 \pm 19.8$  preoperatively to  $25.8 \pm 20.8$  postoperatively ( $p = .04$ ). None of the patients had morbidities (such as nerve injury, delayed tendon ruptures, or tenosynovitis) around the AHPLT donor site. Three patients were very satisfied, two patients were satisfied, and one patient was fair with the results. **Conclusions:** Reconstruction of chronic TA tendon ruptures using a free AHPLT autograft could be successfully performed with satisfactory clinical outcomes and minimal donor site morbidities. Future studies with a larger population size and a comparative group are warranted to confirm these findings.

## Keywords

Anterior half peroneus longus tendon, autograft, chronic tendon rupture, reconstruction, tibialis anterior tendon

Date received: 12 January 2022; accepted: 8 February 2022

## Introduction

Rupture of the tibialis anterior (TA) tendon is a rare injury. Traumatic ruptures may occur as a result of laceration or blunt trauma, while atraumatic ruptures may occur following eccentric loading of a degenerated tendon against a plantarflexed ankle.<sup>1–3</sup> Although the TA tendon is the major dorsiflexor of the ankle joint, when the extensor hallucis longus (EHL) and extensor digitorum longus (EDL) tendons are intact, some degree of ankle dorsiflexion is possible even with the total disruption of the TA tendon, which may delay the diagnosis of TA tendon rupture.<sup>2</sup> Patients

<sup>1</sup>Department of Orthopaedic Surgery, Dongtan Sacred Hospital, Hallym University, Hwaseong, South Korea

<sup>2</sup>Department of Orthopedic Surgery, Ajou University Hospital, Ajou University School of Medicine, Suwon, Republic of Korea

<sup>3</sup>Department of Orthopedic Surgery, Kangnam Sacred Heart Hospital, Hallym University College of Medicine, Seoul, Republic of Korea

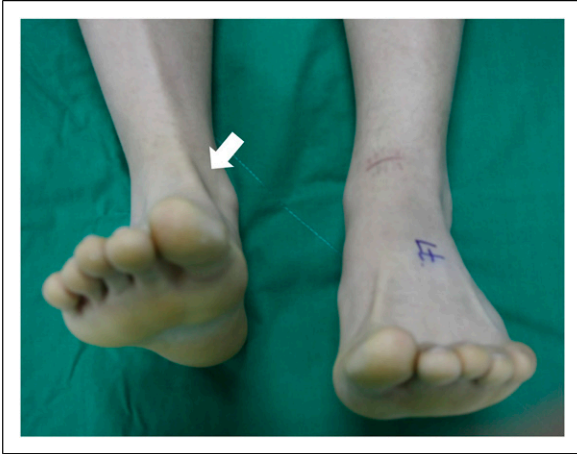\*Sung Jae Kim and Young Uk Park contributed equally to this work as the first authors.

### Corresponding author:

Hyong Nyun Kim, Department of Orthopaedic Surgery, Kangnam Sacred Heart Hospital, Hallym University College of Medicine, 948-1, Dalim-1dong, Youngdeungpo-gu, Seoul 150-950, Republic of Korea.  
Email: [hyongnyun@naver.com](mailto:hyongnyun@naver.com)



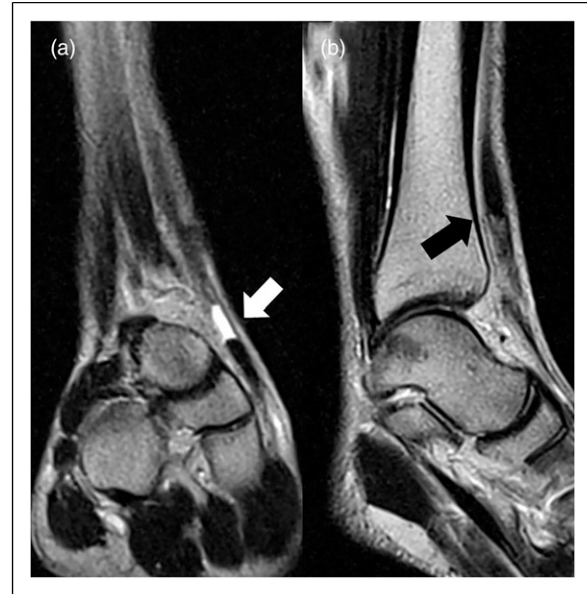Creative Commons Non Commercial CC BY-NC: This article is distributed under the terms of the Creative Commons Attribution-NonCommercial 4.0 License (<https://creativecommons.org/licenses/by-nc/4.0/>) which permits non-commercial use, reproduction and distribution of the work without further permission provided the original work is attributed as specified on the SAGE and Open Access pages (<https://us.sagepub.com/en-us/nam/open-access-at-sage>).



**Figure 1.** Total rupture of TA tendon was not diagnosed after direct laceration on the left anterior ankle because the extensor hallucis longus and the extensor digitorum longus tendon could dorsiflex the ankle joint to some extent. However, after 2 months of the injury, the patient visited the hospital because he could not fully dorsiflex or invert the ankle as compared to the uninjured ankle. The TA tendon in the injured ankle is not prominent compared to that in the uninjured ankle (arrow). TA: tibialis anterior.

may not seek immediate medical attention until they discover a lump (ruptured tendon end) on the dorsum of their foot or ankle or until they experience a functional loss. Doctors may also not diagnose the TA tendon rupture upon physical examination because the EHL and EDL tendons may have compensated for the TA tendon rupture to a certain extent (Figure 1).<sup>4</sup> A delay in the diagnosis of TA tendon rupture may result in a major tendon defect, making a direct repair no longer suitable.<sup>5,6</sup> Several techniques have been introduced to reconstruct the TA tendon rupture, which include the use of an allograft tendon, an autogenous tendon such as the EDL, plantaris or hamstring tendons, or an EHL tendon transfer.<sup>1-4,7,8</sup> Although satisfactory clinical outcomes have been reported with the use of an autogenous tendon, there is still a possibility of donor site morbidity after full-thickness tendon harvest. Because the EHL or EDL tendon also function as a dorsiflexor of the ankle joint, harvesting a tendon from the dorsiflexors may not be advantageous in increasing the dorsiflexion strength.<sup>4</sup> Hamstring tendons are a good autogenous tendon source without much donor site morbidity; therefore, they are widely used for tendon or ligament reconstructions.<sup>9-11</sup> However, pre-cutting of the tendon may occur at the junctures connected to this if surgeons are not familiar with the knee's anatomy.<sup>12</sup> An inadvertent saphenous nerve injury during the harvest procedure may result in numbness around the harvest site.

To the best of our knowledge, the use of a free anterior half of a peroneus longus tendon (AHPLT) autograft for the TA tendon reconstruction has not been reported to date. The



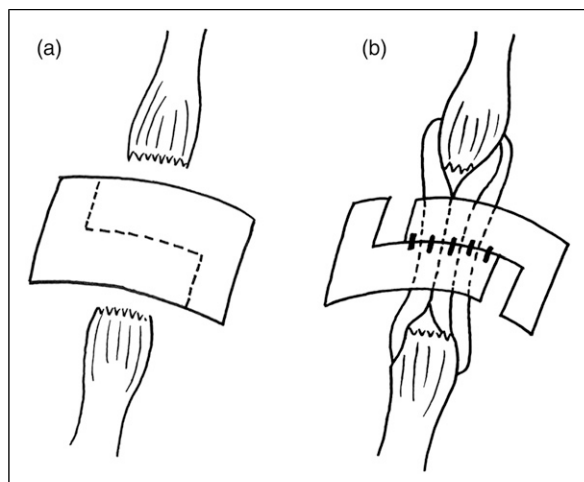
**Figure 2.** Magnetic resonance images show a completely ruptured tibialis anterior tendon. (a) Coronal image shows a tendon defect (white arrow). (b) Sagittal image shows the ruptured tendon end (black arrow) retracted superiorly with regenerated tendon on the distal area.

AHPLT is known to be an acceptable autograft source owing to its strength, safety, and low donor site morbidity; hence, it can also be a good autogenous source for TA tendon reconstruction.<sup>13-15</sup> The peroneus longus tendon (PLT) is superficial in the distal leg and has no juncture and adherence to the surrounding soft tissues; therefore, it can be easily harvested with a tendon stripper near the TA tendon reconstruction site without changing the patient's position or draping.<sup>14,15</sup> As the posterior half of the PLT is left intact after the harvesting, the function of the PLT is preserved. Moreover, the muscle is not retracted, as done in the full-thickness hamstring tendon harvesting. The PLT has potential to regenerate.<sup>15</sup> In a study of 21 patients, the PLT was found to regenerate after partial-thickness harvest upon magnetic resonance imaging (MRI) findings obtained 1 year after AHPLT harvest.<sup>15</sup> In this study, we aimed to describe the surgical technique and present the clinical outcomes of reconstruction of the chronic TA tendon ruptures using an AHPLT autograft.

## Materials and methods

### Subjects

Between September 2014 and April 2019, five patients with chronic TA tendon rupture were surgically treated through TA tendon reconstruction using an AHPLT autograft. Institutional review board approval was obtained from IRB of Hallym University Kangnam Sacred Heart Hospital

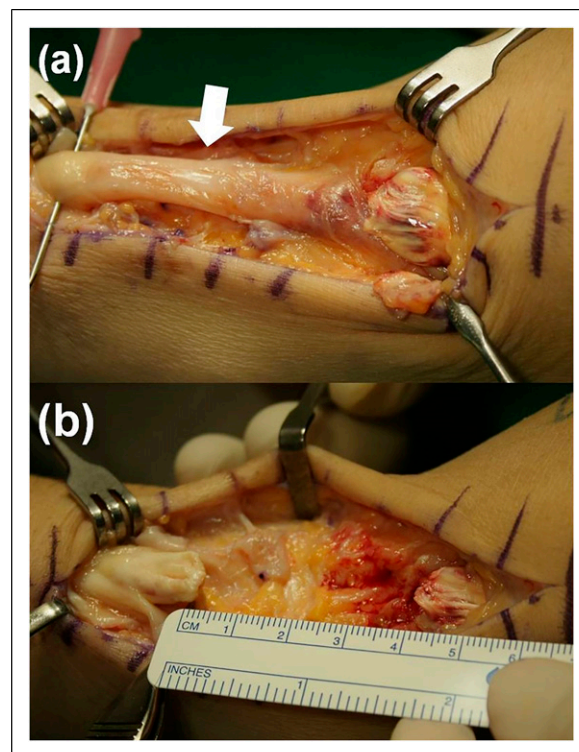


**Figure 3.** (a) When the extensor retinaculum had to be opened because of adhesion, a stepped incision was made. (b) Sometimes, anatomical repair of the retinaculum was not feasible over the reconstructed tendon when the diameter of the reconstructed tendon became thicker than the original diameter of the tibialis anterior tendon. In this case, the extensor retinaculum was repaired through stepped closure with lengthening to minimize constriction and increase tendon excursion.

(reference number: 2020-11-011). Patients provided informed consent and were invited for a final follow-up office visit for the clinical outcome evaluation. Of the patients included, four were men and one was a woman, with a mean age of 43.8 (range: 23–65) years. There were four traumatic ruptures with laceration and one atraumatic rupture. Indication for using the present technique was the chronic TA tendon ruptures with a significant tendon defect that made direct repair unsuitable (Figure 2).

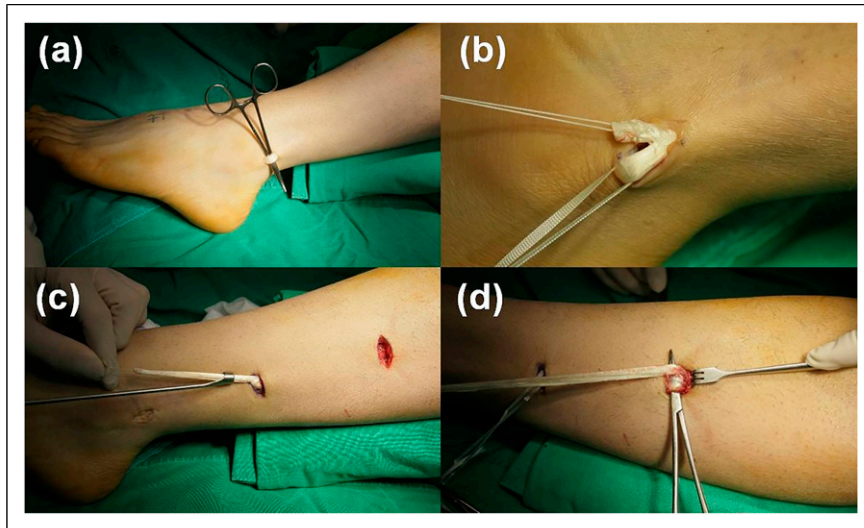
### Operative technique

Patients were placed in the supine position with a thigh tourniquet and under spinal or general anesthesia. A longitudinal incision was made on the anterior ankle on the course of the TA tendon. The extensor retinaculum was preserved whenever possible to prevent bowstringing of the reconstructed tendon. However, the extensor retinaculum was opened through a stepped incision when there were considerable adhesions of the ruptured tendon ends (Figure 3). This enabled subsequent repair of the extensor retinaculum to increase its length and ensure the smooth gliding of the reconstructed TA tendon. Ruptured tendon ends were isolated, while degenerated or the scar tissues were debrided until the healthy tendons were exposed for the reconstruction. The defect size was measured to determine the length of the AHPLT harvesting (Figure 4). The AHPLT was harvested on the ipsilateral ankle without

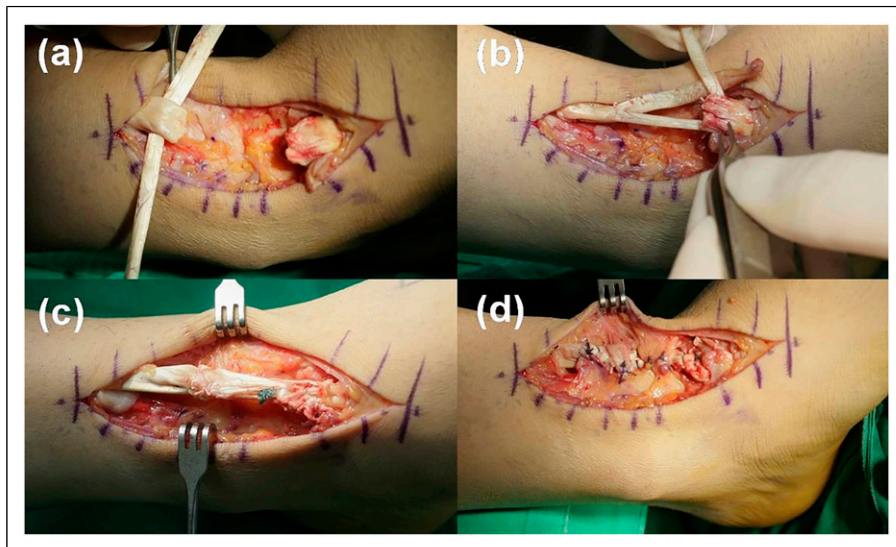


**Figure 4.** (a) Ruptured tendon ends were isolated and the degenerated or scar tissues (arrow) were debrided until healthy tendons were exposed. (b) The defect size was measured to determine the required length of the anterior half of a peroneus longus tendon to be harvested.

changing the patient's position or draping (Figure 5). A 1-cm longitudinal incision was made 3 cm proximal from the distal tip of the fibular on the posterior fibular over the peroneal tendons. Given that the PLT is superficial to the peroneus brevis tendon, it could be easily identified and pulled out from the incision (Figure 5(a)). The anterior half of the tendon was cut, and a whip stitch was made. Then, a tendon stripper (Arthrex Inc., Naples, FL, USA) was introduced over the anterior portion of the PLT and was pushed proximally. When the tendon was pulled from the initial incision, its course became prominent under the skin (Figure 5(a)). A 1.5-cm transverse skin incision was made over the proximal area of the PLT to cut and harvest the tendon. When a graft size of more than 10 cm was required for the reconstruction, we made another incision on the midway toward the proximal incision to check the diameter of the tendon to be harvested and to prevent precutting or over-cutting of the tendon. The AHPLT to be harvested was pulled out from the midway incision, while the diameter of the tendon to be harvested could be adjusted. Thereafter, the tendon stripper was pushed again proximally until the required length was reached (Figure 5(c)). The AHPLT was pulled from the proximal incision and was cut and prepared



**Figure 5.** (a) A 1-cm longitudinal incision was made 3 cm proximal from the distal tip of the fibular on the posterior fibular, and the peroneus longus tendon (PLT) was pulled out. (b) The anterior half of the tendon was cut, and a whip stitch was made. Then, a tendon stripper was introduced over the anterior portion of the PLT and was pushed proximally. (c) When a graft size of more than 10 cm was required for reconstruction, we made a transverse incision on the midway toward the proximal incision to check the diameter of the tendon to be harvested prevent precutting or over-cutting of the tendon. Then, the tendon stripper was pushed again proximally until the required length was achieved. (d) The anterior half of the peroneus longus tendon was pulled from the proximal incision and was cut and prepared for reconstruction.



**Figure 6.** (a) The harvested anterior half of the peroneus longus tendon (AHPLT) was passes through the proximal end of the ruptured anterior tibialis (AT) tendon and sutured. (b) One end of the AHPLT was then passed through the distal end of the ruptured AT tendon and sutured with the ankle in the neutral dorsiflexed position. (c) The other end of the AHPLT was sutured to the distal end of the AT tendon, and the doubled or tripled tendons were sutured together. (d) The retinaculum was repaired with stepped closure with lengthening to minimize constriction and increase tendon excursion.

for the reconstruction (Figure 5(d)). The diameter of the harvested AHPLT was approximately 3.5–4.0 mm; this tendon was usually doubled or tripled to increase the diameter (Figure 6). The AHPLT was passed through the proximal end of the ruptured AT tendon and was sutured

(Figure 6(a)). When the retinaculum was not opened, both ends of the AHPLT were passed under the retinaculum. One end of the AHPLT was then passed through the distal end of the ruptured AT tendon and sutured with the ankle in a neutral dorsiflexed position (Figure 6(b)). The other end of

the AHPLT was sutured to the distal end of the AT tendon and the doubled or tripled tendons were sutured together (Figure 6(c)). In cases wherein not much healthy tendon was left on the distal stump, the Bio-Tenodesis screw (Arthrex Inc., Naples, FL, USA) was used to fix the AHPLT into the footprint of the TA tendon insertion on the medial cuneiform, as described previously.<sup>16</sup> When the extensor retinaculum had been opened before the reconstruction, it was then repaired (Figure 6(d)). However, anatomical repair of the retinaculum was not always feasible because the extensor retinaculum had been shortened over the tendon defect or the diameter of the reconstructed tendon became thicker than the original diameter of the TA tendon when the AHPLT was doubled or tripled. Leaving the retinaculum unrepaired could result in bowstringing, which alters mechanics and causes loss in strength. In this case, the extensor retinaculum was repaired through stepped closure with lengthening to minimize constriction and increase tendon excursion (Figure 3(b)).

A below-knee cast was applied with windows made on the anterior and lateral ankle for the wound dressing. Cast immobilization was used to prevent plantarflexion of the ankle joint, which may cause unnecessary stretching of the reconstructed tendon. Partial weight-bearing in the removable cast was allowed at 6 weeks, while plantarflexion was gradually increased. The removable cast was required until 8–12 weeks postoperatively, depending on the surgeon's perception of the reconstruction quality during surgery and the patient's postoperative condition.

### Clinical outcome assessment

Clinical outcomes were assessed using the 100-mm visual analog scale (VAS) and the Foot Function Index (FFI).<sup>17,18</sup> which were evaluated preoperatively and at 12 months, postoperatively, and during the final follow-up. The 100-mm VAS is a validated self-assessment tool for evaluating pain after surgery.<sup>18</sup> Patients were asked to indicate their current pain severity with a single vertical mark through a 100-mm horizontal VAS bounded by the descriptors "least possible pain" at 0 mm and "worst possible pain" at 100 mm. The FFI is a validated patient-assessed questionnaire comprising the following three subscales: pain, disability, and activity limitations (total score of 100 points with 100 being the worst).<sup>17</sup> The dorsiflexion strength was assessed preoperatively, 12 months postoperatively, and during the final follow-up, according to the modified Medical Research Council (mMRC) scale.<sup>19</sup> The mMRC scale is frequently used to assess muscle strength with substantial inter-rater and intra-rater reliability.<sup>19–21</sup> The mMRC scale grades muscle strength as 0: no contraction; 1: flicker or trace contraction; 2: active movement with gravity eliminated; 2–3: active movement against gravity over less than 50% of the feasible range of motion (ROM); 3: active

movement against gravity over more than 50% of the feasible ROM; 3–4: active movement against resistance over less than 50% of the feasible ROM; 4: active movement against resistance over more than 50% of the feasible ROM; 4–5: active movement against strong resistance over the feasible ROM but distinctly weaker than the contralateral side; and 5: normal power.<sup>19</sup> At the final follow-up, patients were asked to rate their overall satisfaction with their surgical results as "very satisfied," "satisfied," "fair," "dissatisfied," or "very dissatisfied." Donor site morbidity, such as nerve injury, PLT rupture, or tenosynovitis, was evaluated at the final follow-up.

All data were expressed as mean  $\pm$  standard deviation. The Wilcoxon signed-rank test was used to compare pre- and postoperative values using the SPSS software version 21.0 (IBM Corporation, Armonk, NY, USA). Statistical significance was defined at the 5% ( $p < .05$ ) level.

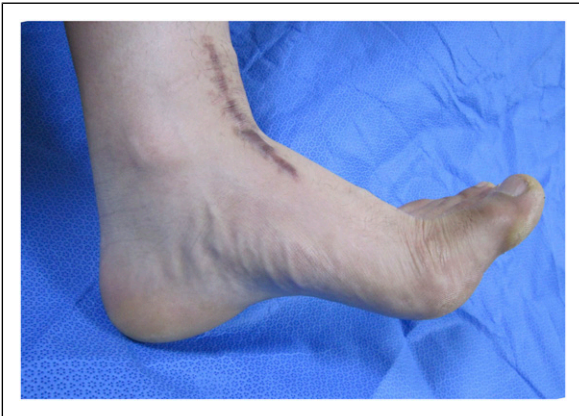### Results

The results are summarized in Table 1. This study included five patients with chronic TA tendon rupture. Among these, the rupture was misdiagnosed as simple laceration on the anterior ankle and neglected after primary skin closure in two patients until they visited the hospital for gait problems with foot slapping and tripping. One patient sustained a deep laceration with total rupture of the TA and EHL tendons and partial rupture of the EDL tendon. Six weeks after the primary repair, the TA and EHL tendons of the patient ruptured again. After debridement of the scar tissue, end-to-end repair was not feasible; therefore, tendon reconstruction was necessary. One patient also had a distal tibial fracture that was treated with minimally invasive plate osteosynthesis. The diagnosis of the TA tendon rupture was delayed until the patient started ambulation because the TA tendon defect at the ankle was not prominent as the ankle was still swollen after the operation; moreover, MRI is not usually taken when the metal plate is still applied to the distal tibia. A superficial peroneal nerve palsy is suspected when weak dorsiflexion of the ankle is present, which may delay the diagnosis of the TA tendon rupture. One patient had received a steroid injection for midfoot arthritis 4 months before diagnosis of the chronic TA tendon rupture; this patient had a mild ankle sprain and felt discomfort 3 weeks before the diagnosis. The mean delay in diagnosis was 7.0 (range: 3–12) weeks. Four patients were followed up until their final assessment, while one patient refused to visit the clinic. Thus, the outcomes assessed 12 months postoperatively were considered as the final outcomes. At a mean follow-up period of 42 (range: 12–70) months, the mean 100-mm VAS score significantly increased from  $38.2 \pm 6.8$  preoperatively to  $17.2 \pm 15.2$  postoperatively ( $p = .03$ ). The mean FFI value also significantly increased from  $39.0 \pm 12.6$  preoperatively to  $18.4 \pm 10.1$  postoperatively

**Table 1.** Details and findings of the five patients in our study.

Case	Sex/Age (years)	Cause of rupture	Delay (week)	Preop FFI	FU (months)	Postop FFI	Postop mMRC dorsiflexion strength <sup>a</sup>	Subjective satisfaction
1	M/23	Neglected after laceration	8	37	77	11	5	Very satisfied
2	M/45	Rerupture after laceration	6	78	12	24	5	Very satisfied
3	F/61	Combined with distal tibial fracture	12	67	53	36	4	Satisfied
4	M/25	Neglected after laceration	6	31	45	3	5	Very satisfied
5	M/65	Rupture after steroid injection	3	56	27	55	3–4	Satisfied

<sup>a</sup>mMRC muscle strength scale was graded as 0: no contraction; 1: flicker or trace contraction; 2: active movement with gravity eliminated; 2–3: active movement against gravity over less than 50% of the feasible ROM; 3: active movement against gravity over more than 50% of the feasible ROM; 3–4: active movement against resistance over less than 50% of the feasible ROM; 4: active movement against resistance over more than 50% of the feasible ROM; 4–5: active movement against strong resistance over the feasible ROM but distinctly weaker than the contralateral side; and 5: normal power.<sup>19</sup> mMRC: modified Medical Research Council; FFI: Foot Function Index<sup>17</sup>; M: male; F: female.



**Figure 7.** Patients could dorsiflex the ankle against strong resistance compared to that noted for the contralateral uninjured ankle.

( $p = .048$ ). Dorsiflexion muscle strength according to the mMRC scale was 5 for three patients, 4–5 for one, and 4 for one (Figure 7). Three patients were very satisfied, two patients were satisfied, and one patient was fair with the outcomes. One patient had wound dehiscence on the reconstruction site that required a local flap and delayed closure. However, none of the patients had morbidity around the AHPLT donor site. The datasets used and analyzed during the present study are available from the corresponding author upon reasonable request.

## Discussion

The most important finding of the present study was that reconstruction of chronic TA tendon rupture could be successfully performed with the use of a free AHPLT

autograft. Among various autogenous tendon sources for reconstruction of the TA tendon, the AHPLT may be the most advantageous one among others, with respect to the ease of harvesting without the need to change a patient's position and the fact that it can be harvested near the reconstruction site with minimum donor site morbidity. Because the PLT is superficial in the distal leg and has no juncture and adherence to the surrounding soft tissues, it may be easily harvested using a tendon stripper near the TA tendon reconstruction site.<sup>14,15</sup> When the tendon is pulled, the course of the tendon can be easily identified under the skin, which makes the harvesting procedure relatively easier. In the present study, the AHPLT with a diameter of 3.5–4 mm and a length of 15 cm could be easily harvested without precutting and could be doubled or tripled in size for reconstruction. None of the patients reported discomfort around the harvesting site, and no donor site morbidity was noted. In a previous study of 30 patients (31 cases) with chronic ankle instability who underwent lateral ankle ligament reconstruction using an AHPLT autograft, no significant decrease in the peroneus longus strength was demonstrated, while donor site morbidity such as delayed tendon ruptures, tendinopathy, or tendosynovitis, was not noted.<sup>13</sup> In another previous study of 92 patients who underwent various knee ligament reconstructions using an AHPLT autograft, no significant impairment of the foot and ankle function was demonstrated; thus, this study reported that the AHPLT can be safely harvested.<sup>14</sup> Minimal donor site morbidity may be due to the posterior half of the PLT being left intact after the AHPLT harvest, which consequently preserves the function of the PLT and does not retract the muscle, as observed in full-thickness tendon harvesting. In addition, the posterior half of the PLT can guide tendon regeneration.<sup>15</sup> In a previous study of 21

patients, the PLT was found to be regenerated after the AHPLT harvest upon MRI performed 1 year after the harvest.<sup>15</sup> In recent years, the use of the AHPLT for ligament and tendon reconstruction has been gaining popularity, being applied not only for foot, ankle, or knee reconstruction but also for shoulder coracoclavicular ligament reconstruction.<sup>13,15,20</sup> Therefore, we believe that it can be a good autogenous tendon source for TA tendon reconstruction.

Historically, EHL tendon transfer has been the most common reconstructive solution for chronic TA tendon rupture.<sup>21–24</sup> The EDL tendon also has been used as an autogenous source for reconstruction, as it passes next to the TA tendon and can be harvested easily using the same incision as that for the reconstruction.<sup>3,8–10,22</sup> However, the EHL and EDL tendons are also ankle dorsiflexors; therefore, harvesting a tendon of another ankle dorsiflexor may not be advantageous to increase the dorsiflexion strength. In a recent systemic review and meta-analysis with more than 23 studies that included 134 surgically treated TA tendon ruptures, the use of the EHL tendon was associated with the worse outcome potential compared to that noted with other surgical strategies.<sup>25</sup> Therefore, harvesting from an ankle plantarflexor such as the PLT may be more advantageous compared to harvesting from an ankle dorsiflexor to reconstruct the TA tendon.

Hamstring tendons are the most widely used autograft tendons for ligament and tendon reconstruction.<sup>9–11</sup> However, for foot and ankle surgeons who are unfamiliar with the local anatomy around the knee, precutting of the tendon may occur at junctures connected to it; therefore, some surgeons prefer to prepare an allograft in the operating room refrigerator in case of a harvesting failure.<sup>12,26</sup> Because a full-thickness tendon is harvested, the continuity of the tendon is disrupted, while the muscle of donor tendon becomes retracted; atrophy takes place thereafter.<sup>27</sup> In a long-term study following a hamstring tendon harvest, fatty infiltration and muscle atrophy were not recovered.<sup>27</sup> However, the use of the AHPLT may prevent muscle retraction. The biomechanical property of the AHPLT is known to be similar to that of hamstring tendons. In a biomechanical study on 20 cadaveric specimens, the average failure load of the AHPLT was 97.69% and 147.94% for the semitendinosus and the gracilis tendon, respectively.<sup>14</sup> The hamstring tendon can be successfully used for reconstruction of chronic TA tendon rupture; therefore, we believe that the AHPLT can also be considered as an autogenous graft source for reconstruction, especially for surgeons who are unfamiliar with knee anatomy and hamstring tendon harvesting.<sup>28,29</sup>

This study has several limitations. First, it has a retrospective and non-comparative design and includes a small number of patients. However, chronic TA tendon rupture is rare; thus, having only a small number of subjects was inevitable. Another limitation is that the dorsiflexion

strength was not measured accurately using a dynamometer and was only checked manually; therefore, subtle differences in weakness may have not been detected because of this. Moreover, we cannot recommend the current technique as the preferred method for TA tendon reconstruction due to the small number of subjects and the lack of a comparative study group. However, we found that TA tendon reconstruction using the AHPLT can be considered for minimal donor site morbidity. A future study with a larger population size and a comparative group may confirm our findings.

## Conclusion

Reconstruction of chronic TA tendon ruptures using the free AHPLT autograft could be successfully performed with satisfactory clinical outcomes and minimal donor site morbidity.

## Declaration of conflicting interests

The author(s) declared no potential conflicts of interest with respect to the research, authorship, and/or publication of this article.

## Funding

The author(s) received no financial support for the research, authorship, and/or publication of this article.

## Ethical approval

This study was approved by Hallym University Kangnam Sacred Heart Hospital Institutional Review Board (IRB number: 2020-11-011).

## Informed consent

Informed consent was received from all the patients of this study.

## Data availability

The datasets used and analyzed during the current study are available from the corresponding author on reasonable request.

## ORCID iD

Hyong Nyun Kim  <https://orcid.org/0000-0001-5934-0665>

## References

1. Mao H and Xu G. Soft tissue repair for tibialis anterior tendon ruptures using plate and screw fixation technique in combination with anterolateral thigh flaps transplantation. *J Orthop Surg Res* 2015; 10: 143. DOI: [10.1186/s13018-015-0278-5](https://doi.org/10.1186/s13018-015-0278-5).
2. Burton A and Aydogan U. Repair of chronic tibialis anterior tendon rupture with a major defect using gracilis allograft. *Foot Ankle Spec* 2016; 9(4): 345–350. DOI: [10.1177/1938640015624757](https://doi.org/10.1177/1938640015624757).

3. Sammarco VJ, Sammarco GJ, Henning C, et al. Surgical repair of acute and chronic tibialis anterior tendon ruptures. *J Bone Joint Surg Am* 2009; 91(2): 325–332. DOI: [10.2106/JBJS.G.01386](https://doi.org/10.2106/JBJS.G.01386).
4. Wong MWN. Traumatic tibialis anterior tendon rupture-delayed repair with free sliding tibialis anterior tendon graft. *Injury* 2004; 35(9): 940–944. DOI: [10.1016/S0020-1383\(03\)00168-2](https://doi.org/10.1016/S0020-1383(03)00168-2).
5. Liu W-C, Chang C-H, Lu C-C, et al. Reconstruction of massive knee defects with extensor mechanism deficiency through concurrent anterolateral thigh flap and autogenous hamstring tendon: a report of two cases. *J Orthop Surg (Hong Kong)* 2020; 28(2): 2309499020935994. DOI: [10.1177/2309499020935994](https://doi.org/10.1177/2309499020935994).
6. Zhou L, Wei J, Liu L, et al. Composite sural neurocutaneous flap with gastrocnemius tendon for repairing defects of achilles tendon and overlying soft tissue. *J Orthop Surg (Hong Kong)* 2020; 28(3): 2309499020971863. DOI: [10.1177/2309499020971863](https://doi.org/10.1177/2309499020971863).
7. Fraissler L, Horas K, Bölch S, et al. Extensor hallucis longus-transfer for tibialis anterior tendon rupture repair. *Oper Orthop Traumatol* 2019; 31(2): 143–148. DOI: [10.1007/s00064-018-0571-7](https://doi.org/10.1007/s00064-018-0571-7).
8. Patel R and Fallat L. Surgical techniques for repair of atraumatic tibialis anterior tendon ruptures: a report of two cases. *J Foot Ankle Surg* 2017; 56(6): 1343–1349. DOI: [10.1053/j.jfas.2017.06.024](https://doi.org/10.1053/j.jfas.2017.06.024).
9. Maffulli N, Loppini M, Longo UG, et al. Minimally invasive reconstruction of chronic achilles tendon ruptures using the ipsilateral free semitendinosus tendon graft and interference screw fixation. *Am J Sports Med* 2013; 41(5): 1100–1107. DOI: [10.1177/0363546513479017](https://doi.org/10.1177/0363546513479017).
10. Maffulli N, Spiezia F, Testa V, et al. Free gracilis tendon graft for reconstruction of chronic tears of the achilles tendon. *J Bone Joint Surg Am* 2012; 94(10): 906–910. DOI: [10.2106/JBJS.K.00869](https://doi.org/10.2106/JBJS.K.00869).
11. Lee DW, Shim JC, Yang SJ, et al. Functional effects of single semitendinosus tendon harvesting in anatomic anterior cruciate ligament reconstruction: comparison of single versus dual hamstring harvesting. *Clin Orthop Surg* 2019; 11(1): 60–72. DOI: [10.4055/cios.2019.11.1.60](https://doi.org/10.4055/cios.2019.11.1.60).
12. Yasin MN, Charalambous CP, Mills SP, et al. Accessory bands of the hamstring tendons: a clinical anatomical study. *Clin Anat* 2010; 23(7): 862–865. DOI: [10.1002/ca.21020](https://doi.org/10.1002/ca.21020).
13. Park CH and Lee W-C. Donor site morbidity after lateral ankle ligament reconstruction using the anterior half of the peroneus longus tendon autograft. *Am J Sports Med* 2017; 45(4): 922–928. DOI: [10.1177/0363546516675167](https://doi.org/10.1177/0363546516675167).
14. Zhao J and Huangfu X. The biomechanical and clinical application of using the anterior half of the peroneus longus tendon as an autograft source. *Am J Sports Med* 2012; 40(3): 662–671. DOI: [10.1177/0363546511428782](https://doi.org/10.1177/0363546511428782).
15. Lee HW, Wang C, Bae TS, et al. Tendon regeneration after partial-thickness peroneus longus tendon harvesting: magnetic resonance imaging evaluation and in vivo animal study. *Am J Sports Med* 2020; 48(10): 2499–2509. DOI: [10.1177/0363546520933628](https://doi.org/10.1177/0363546520933628).
16. Willegger M, Seyidova N, Schuh R, et al. Anatomical footprint of the tibialis anterior tendon: surgical implications for foot and ankle reconstructions. *Biomed Res Int* 2017; 2017: 9542125. DOI: [10.1155/2017/9542125](https://doi.org/10.1155/2017/9542125).
17. Budiman-Mak E, Conrad KJ and Roach KE. The foot function index: a measure of foot pain and disability. *J Clin Epidemiol* 1991; 44(6): 561–570.
18. Carlsson AM. Assessment of chronic pain. I. Aspects of the reliability and validity of the visual analogue scale. *Pain* 1983; 16(1): 87–101.
19. Paternostro-Sluga T, Grim-Stieger M, Posch M, et al. Reliability and validity of the medical research council (MRC) scale and a modified scale for testing muscle strength in patients with radial palsy. *J Rehabil Med* 2008; 40(8): 665–671. DOI: [10.2340/16501977-0235](https://doi.org/10.2340/16501977-0235).
20. Zhu Y, Hsueh P, Zeng B, et al. A prospective study of coracoclavicular ligament reconstruction with autogenous peroneus longus tendon for acromioclavicular joint dislocations. *J Shoulder Elbow Surg* 2018; 27(6): e178–e188.
21. Chen J, Kadakia R, Akoh CC, et al. Management of anterior tibialis tendon ruptures. *J Am Acad Orthop Surg* 2021; 29: 691–701. DOI: [10.5435/JAAOS-D-20-00802](https://doi.org/10.5435/JAAOS-D-20-00802).
22. Ellington JK, McCormick J, Marion C, et al. Surgical outcome following tibialis anterior tendon repair. *Foot Ankle Int* 2010; 31(5): 412–417. DOI: [10.3113/FAI.2010.0412](https://doi.org/10.3113/FAI.2010.0412).
23. Christman-Skieller C, Merz MK and Tansey JP. A systematic review of tibialis anterior tendon rupture treatments and outcomes. *Am J Orthop (Belle Mead NJ)* 2015; 44(4): E94–E99.
24. Negrine JP. Tibialis anterior rupture: acute and chronic. *Foot Ankle Clin* 2007; 12(4): 569–572. DOI: [10.1016/j.fcl.2007.07.004](https://doi.org/10.1016/j.fcl.2007.07.004).
25. Tickner A, Thorng S, Martin M, et al. Management of isolated anterior tibial tendon rupture: a systematic review and meta-analysis. *J Foot Ankle Surg* 2019; 58(2): 213–220. DOI: [10.1053/j.jfas.2018.08.001](https://doi.org/10.1053/j.jfas.2018.08.001).
26. Prodromos CC. Posterior mini-incision hamstring harvest. *Sports Med Arthrosc Rev* 2010; 18(1): 12–14. DOI: [10.1097/JSA.0b013e3181bf661d](https://doi.org/10.1097/JSA.0b013e3181bf661d).
27. Snow BJ, Wilcox JJ, Burks RT, et al. Evaluation of muscle size and fatty infiltration with MRI nine to eleven years following hamstring harvest for ACL reconstruction. *J Bone Joint Surg Am* 2012; 94(14): 1274–1282.
28. Michels F, Van Der Bauwhede J, Oosterlinck D, et al. Minimally invasive repair of the tibialis anterior tendon using a semitendinosus autograft. *Foot Ankle Int* 2014; 35(3): 264–271. DOI: [10.1177/1071100713517096](https://doi.org/10.1177/1071100713517096).
29. Stavrou P and Symeonidis PD. Gracilis tendon graft for tibialis anterior tendon reconstruction: a report of two cases. *Foot Ankle Int* 2008; 29(7): 742–745. DOI: [10.3113/FAI.2008.0742](https://doi.org/10.3113/FAI.2008.0742).