

# Benefits of Early Systemic Corticosteroid in Clinical Deterioration of Post-COVID-19 Interstitial Lung Disease

<https://doi.org/10.4046/trd.2022.0072>  
 ISSN: 1738-3536(Print)/  
 2005-6184(Online)  
 Tuberc Respir Dis 2022;85:358-360

Tai Joon An, M.D., Ph.D.<sup>1</sup>, Ye Jin Lee, M.D.<sup>2</sup>, Ji Eun Park, M.D.<sup>3</sup>, Eung Gu Lee, M.D.<sup>4</sup>, Youlim Kim, M.D., Ph.D.<sup>5</sup>, Sung-Yoon Kang, M.D., Ph.D.<sup>6</sup>, Hyonsoo Joo, M.D., Ph.D.<sup>7</sup> and Joon Young Choi, M.D., Ph.D.<sup>8</sup>

<sup>1</sup>Division of Pulmonary and Critical Care Medicine, Department of Internal Medicine, Yeouido St. Mary's Hospital, College of Medicine, The Catholic University of Korea, Seoul, <sup>2</sup>Division of Pulmonary and Critical Care Medicine, Department of Internal Medicine, Seoul National University Hospital, Seoul, <sup>3</sup>Department of Pulmonary and Critical Care Medicine, Ajou University School of Medicine, Suwon, <sup>4</sup>Division of Pulmonary and Critical Care Medicine, Department of Internal Medicine, Bucheon St. Mary's Hospital, College of Medicine, The Catholic University of Korea, Seoul, <sup>5</sup>Division of Pulmonary and Allergy, Department of Internal Medicine, Konkuk University Medical Center, Konkuk University School of Medicine, Seoul, <sup>6</sup>Division of Pulmonology and Allergy, Department of Internal Medicine, Gachon University Gil Medical Center, Incheon, <sup>7</sup>Division of Pulmonary and Critical Care Medicine, Department of Internal Medicine, Uijeongbu St. Mary's Hospital, College of Medicine, The Catholic University of Korea, Seoul, <sup>8</sup>Division of Pulmonary and Critical Care Medicine, Department of Internal Medicine, Incheon St. Mary's Hospital, College of Medicine, The Catholic University of Korea, Seoul, Republic of Korea

With its rapid spread, coronavirus disease 2019 (COVID-19), a novel coronavirus disease, has become a global health problem. More than 507 million confirmed cases and over 6 million fatalities had been reported by April 2022<sup>1</sup>. Various types of clinical deterioration ranging from a minor common cold to severe respiratory failure have been reported in association with this disease<sup>2</sup>. In an observation study, interstitial lung disease (ILD) was observed in chest computed tomography images of 60% of patients with COVID-19<sup>3</sup>. There is currently no consensus regarding optimal management of patients who show post COVID-19 interstitial change, and only one clinical trial is ongoing<sup>4</sup>. The aim of this study was to focus on the role of systemic corticosteroids in patients with post COVID-19 ILD.

This multicenter retrospective study was conducted in order to analyze patients with post COVID-19 ILD, who were enrolled from eight medical centers in South Korea from July 2021 to April 2022. The definition of post COVID-19 ILD was based on radiologic findings of ILD (including ground glass opacities, reticulation, and consolidation) at least one week after the acute phase of COVID-19 pneumonia, according to physicians' diagnosis. Data were extracted from electronic medical records from each center. General characteristics including age, sex, body mass index (BMI), hospital days, comorbidities, smoking history, symptoms, vital signs, laboratory findings, oxygen requirements, radiologic findings, intensive care unit (ICU) stay, and medications were collected. Deterioration on a chest X-ray (CXR) was defined as worsening of a CXR image after admission for 48 hours. Clinical deterioration was defined as composite outcomes including CXR deteriorations, administration/escalation of antibiotics and/or systemic corticosteroids, or oxygen supplement 48 hours or later after hospitalization. A comparison of clinical characteristics and deterioration between corticosteroid non-users and users was performed. Evaluation of the risk of clinical deterioration according to initial steroid use was performed using a binomial regression model, with adjustment for age, sex, and O<sub>2</sub> demands. Evaluation of variables associated with clinical deterioration was also performed using each regression model.

Finally, a total of 46 patients who showed no evidence of COVID-19 reactivation were enrolled and analyzed. The mean duration from the date COVID-19 was confirmed to enrollment was 17.7±8.9 days. Thirteen patients were steroid non-users,



Copyright © 2022 The Korean Academy of Tuberculosis and Respiratory Diseases

**Address for correspondence**  
**Joon Young Choi, M.D., Ph.D.**  
 Division of Pulmonary and Critical Care Medicine, Department of Internal Medicine, Incheon St. Mary's Hospital, College of Medicine, The Catholic University of Korea, 56 Dongsu-ro, Bupyeong-gu, Incheon 21431, Republic of Korea  
**Phone** 82-32-280-7441  
**Fax** 82-32-280-5748  
**E-mail** [tawoe@naver.com](mailto:tawoe@naver.com)  
**Received** May. 9, 2022  
**Revised** Jun. 16, 2022  
**Accepted** Aug. 6, 2022  
**Published online** Aug. 11, 2022



© It is identical to the Creative Commons Attribution Non-Commercial License (<http://creativecommons.org/licenses/by-nc/4.0/>).

and 33 patients were steroid users. No significant differences in age, sex, BMI, smoking history, comorbidities, symptoms, white blood cell count, C-reactive protein, hospital days, oxygen supplement, radiologic findings, use of antibiotics, ICU admission, and steroid use day were observed between corticosteroid users and non-users. Significant differences in the administration of antibiotics (38.5% vs. 6.1%,  $p=0.022$ , respectively) and corticosteroids were observed after 48 hours (41.7% vs. 3.0%,  $p<0.01$ ). No significant difference in oxygen supplement (23.1% vs. 15.2%,  $p=0.836$ ) or CXR deterioration (38.5% vs. 9.1%,  $p=0.053$ ) was observed between the two groups. Using a binomial regression model, a more favorable outcome regarding clinical deterioration (odds ratio [OR], 0.03; 95% confidence interval [CI], 0.02–0.78), adding antibiotics (OR, 0.05; 95% CI, 0.01–0.49), adding corticosteroid (OR, 0.05; 95% CI, 0.00–0.61), and CXR deterioration (OR, 0.09; 95% CI, 0.01–0.66) was observed for steroid users (Figure 1).

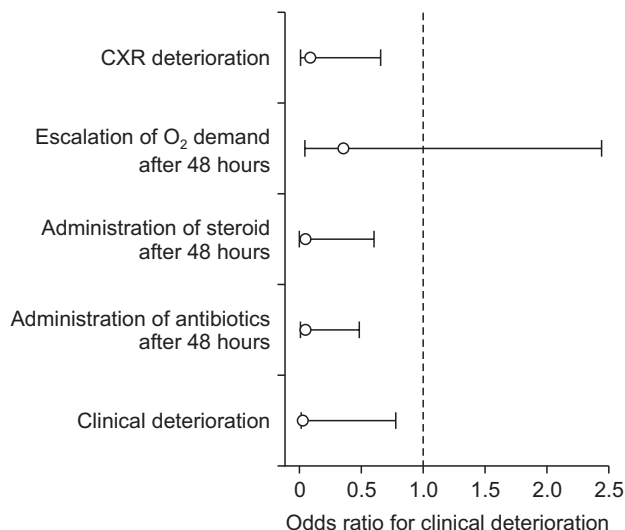
Inflammatory ILD and lung fibrosis, which are severe pulmonary sequelae of COVID-19, have been an increasing concern, and there is no proven treatment. Antifibrotic therapy or corticosteroids have emerged as potential options for treatment of post-COVID-19 pulmonary fibrosis. Myall et al.<sup>5</sup> reported on the clinical effect of corticosteroids in treatment of persistent inflammatory ILD after COVID-19. Ahmad et al.<sup>6</sup> reported on the potential value of antifibrotic therapy in patients with post-COVID-19 inflammatory ILD. However, there is a lack of data regarding the development of acute exacerbation (AE) in post-COVID-19 patients in stable

condition without the use of corticosteroids. We suggest the potential for use of systemic corticosteroids as an initial choice in management of AE in patients with post-COVID-19 inflammatory ILD. Regarding prevention of clinical deterioration and reducing the need for further therapy by antibiotics and corticosteroids, significant clinical benefits have been demonstrated in these patients with use of initial systemic corticosteroids.

Many studies regarding persistent lung damage or ILD after COVID-19 infection reported that a good response to this condition was achieved with use of systemic corticosteroid<sup>5</sup>. Various stages of lung fibrosis, including migration of inflammatory cells or proliferation of fibroblasts were observed in association with post-COVID-19 inflammatory ILD<sup>7,8</sup>. In addition, according to some studies they were classified radiologically or histopathologically as organizing pneumonia<sup>9,10</sup>. A good response was usually observed after treatment with systemic corticosteroid. A similar pattern of radiologic findings of post-COVID-19 ILD was observed for the patients enrolled in this study, unless, in comparison, these patients did not show earlier worsening of the lung condition after COVID-19 infection. We assumed that the reason for the good response to initial treatment with systemic corticosteroid might be associated with the similar condition reported in the above-mentioned articles.

Therefore, we recommend the administration of systemic corticosteroids in AE patients who have overcome acute COVID-19 infection. Even though the reactivation of COVID-19 is considered simultaneously, initial use of corticosteroids is reasonable because it is a primary treatment for severe cases of COVID.

**Figure 1.** Risk of clinical deterioration according to early systemic corticosteroid use. CXR: chest X-ray.



## Authors' Contributions

Conceptualization: An TJ, Kim Y, Choi JY. Methodology: An TJ, Kim Y, Joo H, Choi JY. Investigation: An TJ, Lee YJ, Park JE, Lee EG, Kim Y, Kang SY, Joo H, Choi JY. Writing - original draft preparation: An TJ, Choi JY. Writing - review and editing: An TJ, Lee YJ, Park JE, Lee EG, Kim Y, Kang SY, Joo H, Choi JY. Approval of final manuscript: all authors.

## Conflicts of Interest

No potential conflict of interest relevant to this article was reported.

## Funding

No funding to declare.

## References

1. WHO coronavirus (COVID-19) dashboard [Internet]. Geneva: World Health Organization; 2022 [cited 2022 May 1]. Available from: <https://covid19.who.int>.
2. Rothan HA, Byrareddy SN. The epidemiology and pathogenesis of coronavirus disease (COVID-19) outbreak. *J Autoimmun* 2020;109:102433.
3. Li X, Shen C, Wang L, Majumder S, Zhang D, Deen MJ, et al. Pulmonary fibrosis and its related factors in discharged patients with new corona virus pneumonia: a cohort study. *Respir Res* 2021;22:203.
4. Bazdyrev E, Rusina P, Panova M, Novikov F, Grishagin I, Nebolsin V. Lung fibrosis after COVID-19: treatment prospects. *Pharmaceuticals (Basel)* 2021;14:807.
5. Myall KJ, Mukherjee B, Castanheira AM, Lam JL, Benedetti G, Mak SM, et al. Persistent post-COVID-19 interstitial lung disease: an observational study of corticosteroid treatment. *Ann Am Thorac Soc* 2021;18:799-806.
6. Ahmad K, Srinivas SV, Century RB, Abu-Hamda E, Libre EA. A potential role for antifibrotic use in post-COVID-19 pulmonary fibrosis. *Am J Respir Crit Care Med* 2021;203:A4091.
7. Ambardar SR, Hightower SL, Huprikar NA, Chung KK, Singhal A, Collen JF. Post-COVID-19 pulmonary fibrosis: novel sequelae of the current pandemic. *J Clin Med* 2021;10:2452.
8. Giacomelli C, Piccarducci R, Marchetti L, Romei C, Martini C. Pulmonary fibrosis from molecular mechanisms to therapeutic interventions: lessons from post-COVID-19 patients. *Biochem Pharmacol* 2021;193:114812.
9. Bradley BT, Maioli H, Johnston R, Chaudhry I, Fink SL, Xu H, et al. Histopathology and ultrastructural findings of fatal COVID-19 infections in Washington State: a case series. *Lancet* 2020;396:320-32.
10. Pan F, Ye T, Sun P, Gui S, Liang B, Li L, et al. Time course of lung changes at chest CT during recovery from coronavirus disease 2019 (COVID-19). *Radiology* 2020;295:715-21.