

Parasitic leiomyoma in the trocar site after laparoscopic myomectomy: A case report

Chul Kyu Roh, Hyuk-Jae Kwon, Min Jung Jung

Specialty type: Medicine, research and experimental

Provenance and peer review:

Unsolicited article; Externally peer reviewed.

Peer-review model: Single blind

Peer-review report's scientific quality classification

Grade A (Excellent): A

Grade B (Very good): B

Grade C (Good): 0

Grade D (Fair): 0

Grade E (Poor): 0

P-Reviewer: Bhardwaj R, Mallis P

Received: November 11, 2021

Peer-review started: November 11, 2021

First decision: January 11, 2022

Revised: January 13, 2022

Accepted: February 15, 2022

Article in press: February 15, 2022

Published online: March 26, 2022



Chul Kyu Roh, Department of Surgery, National Police Hospital, Seoul 05715, South Korea

Hyuk-Jae Kwon, Department of Surgery, Ajou University School of Medicine, Suwon 16499, South Korea

Min Jung Jung, Department of Pathology, College of Medicine, The Catholic University of Korea, Seoul 06591, South Korea

Corresponding author: Min Jung Jung, MD, Assistant Professor, Department of Pathology, College of Medicine, The Catholic University of Korea, 327, Sosa-ro, Wonmi-gu, Seoul 06591, South Korea. sobac80@hotmail.com

Abstract

BACKGROUND

Laparoscopic myomectomy is increasingly used for resecting gynecological tumors. Leiomyomas require morcellation for retrieval from the peritoneal cavity. However, morcellated fragments may implant on the peritoneal cavity during retrieval. These fragments may receive a new blood supply from an adjacent structure and develop into parasitic leiomyomas. Parasitic leiomyomas can occur spontaneously or iatrogenically; however, trocar-site implantation is an iatrogenic complication of laparoscopic uterine surgery. We describe a parasitic leiomyoma in the trocar-site after laparoscopic myomectomy with power morcellation.

CASE SUMMARY

A 50-year-old woman presented with a palpable abdominal mass without significant medical history. The patient had no related symptoms, such as abdominal pain. Computed tomography findings revealed a well-defined contrast-enhancing mass measuring 2.2 cm, and located on the trocar site of the left abdominal wall. She had undergone laparoscopic removal of uterine fibroids with power morcellation six years ago. The differential diagnosis included endometriosis and neurogenic tumors, such as neurofibroma. The radiologic diagnosis was a desmoid tumor, and surgical excision of the mass on the abdominal wall was successfully performed. The patient recovered from the surgery without complications. Histopathological examination revealed that the specimen resected from the trocar site was a uterine leiomyoma.

CONCLUSION

Clinicians should consider the risks and benefits of laparoscopic *vs* laparotomic myomectomy for gynecological tumors. Considerable caution must be exercised

for morcellation to avoid excessive tissue fragmentation.

Key Words: Laparoscopic myomectomy; Parasitic leiomyoma; Trocar site; Implantation; Morcellation; Case report

©The Author(s) 2022. Published by Baishideng Publishing Group Inc. All rights reserved.

Core Tip: A 50-year-old female presented with a palpable mass on the left quadrant of the abdomen after laparoscopic myomectomy using power morcellation. We treated the mass by surgical excision. No other complications were observed during follow-up. According to our findings, parasitic leiomyoma may be developed in the previous trocar-site following laparoscopic morcellation. Parasitic leiomyoma is a late complication of laparoscopic myomectomy. Caution should be exercised when performing laparoscopic myomectomy or hysterectomy using power morcellation.

Citation: Roh CK, Kwon HJ, Jung MJ. Parasitic leiomyoma in the trocar site after laparoscopic myomectomy: A case report. *World J Clin Cases* 2022; 10(9): 2895-2900

URL: <https://www.wjgnet.com/2307-8960/full/v10/i9/2895.htm>

DOI: <https://dx.doi.org/10.12998/wjcc.v10.i9.2895>

INTRODUCTION

Uterine myoma is the most common benign neoplasm of the female genitalia. However, most patients with uterine myoma are asymptomatic, despite the relatively high prevalence[1,2]. A variety of treatment modalities, such as medical or surgical interventions have been used for symptomatic patients. As for surgical management, laparotomy or minimally invasive surgery may be preferred[3].

Since the introduction of laparoscopic hysterectomy in 1989, several laparoscopic surgical tools have been developed to broaden the scope of minimally invasive pelvic surgery and to facilitate surgeons[4]. Several devices for laparoscopy are also used for the removal of large tumors *via* small incisions, enabling laparoscopic hysterectomy and laparoscopic myomectomy.

The increased use of laparoscopic power morcellators has allowed the removal of large leiomyomas through small incisions with benefits, such as reduced bleeding, shorter hospital stays, and shorter recovery times[4,5]. Fragmentation of myoma with a morcellator can result in peritoneal dissemination, which can develop into a parasitic leiomyoma if not identified during surgery[1].

Parasitic myoma is defined as the ectopic implantation of uterine fibroids[6]. They obtain their blood supply through new blood vessels coming from adjacent organs. Since the introduction of electromechanical tissue morcellator, many studies have reported the occurrence of parasitic myomas after morcellation. This is a rare late sequela of laparoscopic morcellation procedures[7]. The prevalence of parasitic leiomyomas is estimated to be 0.07% after laparoscopically removing the uterine leiomyoma[8]. As for parasitic leiomyomas, only a few studies have reported trocar-site implantation of parasitic leiomyomas [9-12].

Trocar-site implantation is defined as tumor recurrence at the abdominal wall within the trocar sites, following laparoscopic examination for malignant diseases[13]. It is not metastasis but rather the occurrence of a residual tumor that has not been resected from a previous surgery. Since the pathophysiology is not clear, the disease is rare and difficult to manage. Herein, we present a case of trocar-site implantation of a parasitic myoma after laparoscopic myomectomy with power morcellation.

CASE PRESENTATION

Chief complaints

A 50-year-old woman was referred to our outpatient clinic, owing to the presence of a mass on the left side of the lower abdominal wall.

History of present illness

The patient had no recent history of trauma or abdominal injuries, and did not complain of any abdominal symptoms associated with the mass.

History of past illness

The patient had undergone laparoscopic myomectomy for uterine myoma six years ago; however, she reported no past medical, psychological, or pharmacological history.

Personal and family history

The patient could not remember any remarkable medical history of her parents or siblings.

Physical examination

Physical examination revealed the presence of a palpable mass in the left lower quadrant, overlying the previous laparoscopic trocar site. There was no localized tenderness over the left lower quadrant.

Laboratory examinations

Initial laboratory tests were within normal limits as follows: white blood cell count, 3900/ μ L; hemoglobin level, 12.3 g/dL; and platelet count, 217000/ μ L. Other routine blood chemistry tests, such as renal panel, hepatic panel, pancreatic enzymes, and coagulation test were also within the normal limits.

Imaging examinations

Abdominal computed tomography demonstrated a 2.2-cm well-defined contrast-enhancing mass on the left side of the abdominal wall beside the rectus muscle. There were no remarkable findings in the upper abdominal solid organ. The radiological diagnosis was a desmoid tumor, and the differential diagnosis included endometriosis and neurogenic tumors, such as neurofibroma (Figure 1).

FINAL DIAGNOSIS

The final diagnosis was a leiomyoma. Histopathological assessment after the surgery revealed that the fragment of brownish firm tissue measured 2.6 cm \times 2.0 cm \times 1.2 cm. Immunohistochemistry analysis for actin showed a positive result, and the final diagnosis was leiomyoma.

TREATMENT

We performed surgical excision of the mass. After the skin incision, we approached the mass, which was located between the rectus muscle and aponeurosis of the external oblique muscle. The surgery took approximately 27 min from the skin incision to wound closure without intraoperative complications. The patient was discharged on the operative day without any complications.

OUTCOME AND FOLLOW-UP

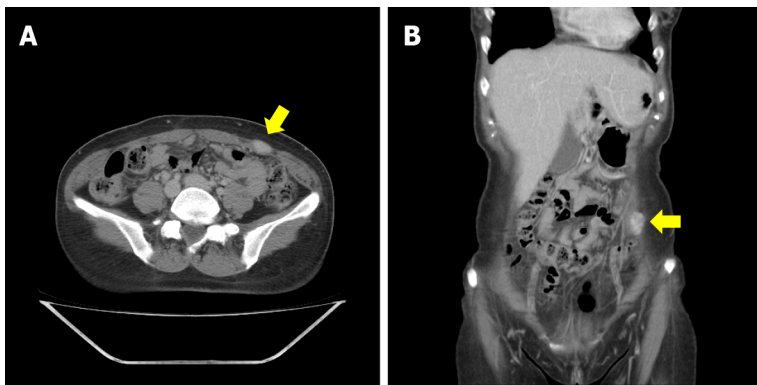
The patient recovered from the surgery without complications, and no other complications were observed during follow-up.

DISCUSSION

After laparoscopic myomectomy for multiple myomas with power morcellation, the patient developed trocar-site implantation of a parasitic leiomyoma without recurrence of intraperitoneal parasitic leiomyoma.

Laparoscopic myomectomy and hysterectomy are increasingly used to treat gynecological tumors[4]. Power morcellators are often used to fragment bulky lesions, such as uterine myomas. Some of the small fragments may unintentionally settle in the peritoneal cavity and be implanted[14]. They receive vascular supply from the adjacent structures and develop into a parasitic leiomyoma[15]. Parasitic leiomyoma is a rare late sequela after laparoscopic myomectomy using power morcellation; the reported incidence is 0.2% to 1.25%, and diagnosis interval is four years (median)[8]. It is unclear why parasitic leiomyomas develop in only a few patients who undergo laparoscopic myomectomy or hysterectomy. A large-scale prospective study is warranted to determine the incidence and risk factors for parasitic leiomyomas after laparoscopic myomectomy or hysterectomy using power morcellation.

The clinical feature of parasitic leiomyoma depends on the site of recurrence and is generally nonspecific. Parasitic leiomyomas are commonly seen in the abdominal cavity, such as small/large bowel, bladder, and vaginal stump[16,17]. However, to date, few cases of trocar-site implantation of a



DOI: 10.12998/wjcc.v10.i9.2895 Copyright ©The Author(s) 2022.

Figure 1 Abdominal computed tomography. Images of both views show a contrast-enhancing mass on the left abdominal wall (yellow arrow). A: Coronal view; B: Axial view.

parasitic myoma after laparoscopic morcellation have been reported[9-12]. Most patients with trocar-site parasitic leiomyoma are asymptomatic, especially when parasitic leiomyomas are discovered incidentally during other investigations or procedures. On the other hand, in patients with symptoms, the most common symptoms are abdominal pain and a palpable mass.

Measurement of tumor markers was not considered since our patient had no radiologic pelvic ascites, and the lesion was improbable to be malignant given a history of laparoscopic myomectomy. CA-125 is occasionally elevated in large parasitic leiomyomas. However, the current use of CA-125 as a biomarker for the diagnosis, differentiation and surveillance of parasitic leiomyoma is controversial and not recommended. However, if a malignancy, such as a leiomyosarcoma is suspected, measurement of tumor markers could be helpful for treatment and follow-up, especially when the level of the marker is initially elevated[18]. Treatment includes surgical resection of the parasitic leiomyoma. When the parasitic leiomyoma is in other organs, a multidisciplinary approach is recommended whenever possible. However, in this case, since the mass was located on the anterior abdominal wall of the previous trocar site, a multidisciplinary approach was not required. Thus, resection was performed by laparotomy.

Power morcellation during laparoscopic myomectomy is considered a factor in the pathogenesis of iatrogenic parasitic leiomyoma[19]. In this case, parasitic leiomyoma of the abdominal wall supports this hypothesis, as the parietal peritoneum anatomically attaches to and protects the abdominal wall. During unconfined morcellation, small myoma fragments may inadvertently disperse into the abdominal cavity and regrow as parasitic leiomyomas. Morcellation should be avoided when malignancy is suspected. In 2014, the United States Food and Drug Administration (U.S. FDA) released the safety statement for laparoscopic power morcellation as follows: U.S. FDA recommended avoiding laparoscopic power morcellation for hysterectomies or myomectomies because of the risk of occult uterine sarcomas spreading[20]. Likewise, this warning should be taken seriously for benign uterine tumor removal during laparoscopic surgery.

Surgeons must perform a meticulous examination to avoid tissue residue and abundant peritoneal lavage. Various alternatives have been suggested to reduce the risk of parasitic leiomyoma after laparoscopic power morcellation[21]. One of them is performing morcellation using a containment bag. This method can reduce the spread of the morcellated fragments. However, the protected manual in-bag morcellation technique is still controversial for the spread that cannot be ignored at the microscopic level[22]. Furthermore, small tissue of the myoma may be dispersed intraperitoneally during myomectomy or hysterectomy before bagging[23]. Therefore, it is necessary to cautiously examine the peritoneal cavity after laparoscopic morcellation to ensure that no small tissue fragments remain, although this approach might be incomplete for removal of all myoma fragments. Although laparoscopic surgery established better patient outcomes, care must be taken to prevent the spread of occult sarcomas, which may be closely related to survival[24].

CONCLUSION

Trocar-site implantation of a parasitic leiomyoma is a rare late complication after laparoscopic myomectomy or hysterectomy using power morcellation. Clinicians should explain to the patient the benefits and risks of the laparoscopic approach using morcellation. Moreover, efforts should be made to examine the abdominal cavity to retrieve all myoma fragments. Power morcellation during laparoscopic myomectomy should always be performed in a containment bag whenever possible to prevent excessive tissue fragmentation.

FOOTNOTES

Author contributions: Kwon HJ and Roh CK drafted the paper; Roh CK and Jung MJ revised the manuscript; Kwon HJ and Roh CK collected patient's information; Roh CK performed the treatment for this patient.

Informed consent statement: This case report was approved by our institutional review board (Approval No. AJIRB-MED-EXP-21-424), who waived the requirement for informed consent because of full anonymization of patient information. However, written informed consent was obtained from the patient.

Conflict-of-interest statement: The authors declare that they have no conflict of interest.

CARE Checklist (2016) statement: The authors have read the CARE Checklist (2016), and the manuscript was prepared and revised according to the CARE Checklist (2016).

Open-Access: This article is an open-access article that was selected by an in-house editor and fully peer-reviewed by external reviewers. It is distributed in accordance with the Creative Commons Attribution NonCommercial (CC BY-NC 4.0) license, which permits others to distribute, remix, adapt, build upon this work non-commercially, and license their derivative works on different terms, provided the original work is properly cited and the use is non-commercial. See: <https://creativecommons.org/licenses/by-nc/4.0/>

Country/Territory of origin: South Korea

ORCID number: Chul Kyu Roh [0000-0003-2254-6146](https://orcid.org/0000-0003-2254-6146); Hyuk-Jae Kwon [0000-0003-1821-6515](https://orcid.org/0000-0003-1821-6515); Min Jung Jung [0000-0001-8870-5475](https://orcid.org/0000-0001-8870-5475).

S-Editor: Gao CC

L-Editor: A

P-Editor: Gao CC

REFERENCES

- Cohen A, Tulandi T. Long-term sequelae of unconfined morcellation during laparoscopic gynecological surgery. *Maturitas* 2017; **97**: 1-5 [PMID: [28159054](https://pubmed.ncbi.nlm.nih.gov/28159054/) DOI: [10.1016/j.maturitas.2016.11.007](https://doi.org/10.1016/j.maturitas.2016.11.007)]
- Leren V, Langebrekke A, Qvigstad E. Parasitic leiomyomas after laparoscopic surgery with morcellation. *Acta Obstet Gynecol Scand* 2012; **91**: 1233-1236 [PMID: [22574911](https://pubmed.ncbi.nlm.nih.gov/22574911/) DOI: [10.1111/j.1600-0412.2012.01453.x](https://doi.org/10.1111/j.1600-0412.2012.01453.x)]
- Bhave Chittawar P, Franik S, Pouwer AW, Farquhar C. Minimally invasive surgical techniques vs open myomectomy for uterine fibroids. *Cochrane Database Syst Rev* 2014; CD004638 [PMID: [25331441](https://pubmed.ncbi.nlm.nih.gov/25331441/) DOI: [10.1002/14651858.CD004638.pub3](https://doi.org/10.1002/14651858.CD004638.pub3)]
- Seinera P, Arisio R, Decko A, Farina C, Crana F. Laparoscopic myomectomy: indications, surgical technique and complications. *Hum Reprod* 1997; **12**: 1927-1930 [PMID: [9363708](https://pubmed.ncbi.nlm.nih.gov/9363708/) DOI: [10.1093/humrep/12.9.1927](https://doi.org/10.1093/humrep/12.9.1927)]
- Van der Meulen JF, Pijnenborg JM, Boomsma CM, Verberg MF, Geomini PM, Bongers MY. Parasitic myoma after laparoscopic morcellation: a systematic review of the literature. *BJOG* 2016; **123**: 69-75 [PMID: [26234998](https://pubmed.ncbi.nlm.nih.gov/26234998/) DOI: [10.1111/1471-0528.13541](https://doi.org/10.1111/1471-0528.13541)]
- LaCoursiere DY, Kennedy J, Hoffman CP. Retained fragments after total laparoscopic hysterectomy. *J Minim Invasive Gynecol* 2005; **12**: 67-69 [PMID: [15904602](https://pubmed.ncbi.nlm.nih.gov/15904602/) DOI: [10.1016/j.jmig.2004.12.021](https://doi.org/10.1016/j.jmig.2004.12.021)]
- Yoshida A, Nii S, Matsushita H, Morii Y, Watanabe K, Wakatsuki A. Parasitic myoma in women after laparoscopic myomectomy: A late sequela of morcellation? *J Obstet Gynaecol* 2015; **35**: 322-323 [PMID: [25111124](https://pubmed.ncbi.nlm.nih.gov/25111124/) DOI: [10.3109/01443615.2014.948404](https://doi.org/10.3109/01443615.2014.948404)]
- Lu B, Xu J, Pan Z. Iatrogenic parasitic leiomyoma and leiomyomatosis peritonealis disseminata following uterine morcellation. *J Obstet Gynaecol Res* 2016; **42**: 990-999 [PMID: [27125448](https://pubmed.ncbi.nlm.nih.gov/27125448/) DOI: [10.1111/jog.13011](https://doi.org/10.1111/jog.13011)]
- Ostrzenski A. Uterine leiomyoma particle growing in an abdominal-wall incision after laparoscopic retrieval. *Obstet Gynecol* 1997; **89**: 853-854 [PMID: [9166349](https://pubmed.ncbi.nlm.nih.gov/9166349/) DOI: [10.1016/s0029-7844\(97\)81428-7](https://doi.org/10.1016/s0029-7844(97)81428-7)]
- Moon HS, Koo JS, Park SH, Park GS, Choi JG, Kim SG. Parasitic leiomyoma in the abdominal wall after laparoscopic myomectomy. *Fertil Steril* 2008; **90**: 1201.e1-1201.e2 [PMID: [18410930](https://pubmed.ncbi.nlm.nih.gov/18410930/) DOI: [10.1016/j.fertnstert.2007.08.068](https://doi.org/10.1016/j.fertnstert.2007.08.068)]
- Oindi FM, Mutiso SK, Obura T. Port site parasitic leiomyoma after laparoscopic myomectomy: a case report and review of the literature. *J Med Case Rep* 2018; **12**: 339 [PMID: [30428912](https://pubmed.ncbi.nlm.nih.gov/30428912/) DOI: [10.1186/s13256-018-1873-y](https://doi.org/10.1186/s13256-018-1873-y)]
- Kai K, Aoyagi Y, Nishida M, Arakane M, Kawano Y, Narahara H. Port-site implantation of parasitic leiomyoma after laparoscopic myomectomy and its histopathology. *SAGE Open Med Case Rep* 2020; **8**: 2050313X20959223 [PMID: [32995003](https://pubmed.ncbi.nlm.nih.gov/32995003/) DOI: [10.1177/2050313X20959223](https://doi.org/10.1177/2050313X20959223)]
- Reymond MA, Schneider C, Kastl S, Hohenberger W, Köckerling F. The pathogenesis of port-site recurrences. *J Gastrointest Surg* 1998; **2**: 406-414 [PMID: [9843599](https://pubmed.ncbi.nlm.nih.gov/9843599/) DOI: [10.1016/s1091-255x\(98\)80030-9](https://doi.org/10.1016/s1091-255x(98)80030-9)]
- Tulandi T, Leung A, Jan N. Nonmalignant Sequelae of Unconfined Morcellation at Laparoscopic Hysterectomy or Myomectomy. *J Minim Invasive Gynecol* 2016; **23**: 331-337 [PMID: [26802909](https://pubmed.ncbi.nlm.nih.gov/26802909/) DOI: [10.1016/j.jmig.2016.01.017](https://doi.org/10.1016/j.jmig.2016.01.017)]
- Huang PS, Chang WC, Huang SC. Iatrogenic parasitic myoma: a case report and review of the literature. *Taiwan J Obstet Gynecol* 2014; **53**: 392-396 [PMID: [25286798](https://pubmed.ncbi.nlm.nih.gov/25286798/) DOI: [10.1016/j.tjog.2013.11.007](https://doi.org/10.1016/j.tjog.2013.11.007)]
- Donnez J, Smets M, Polet R, Bassil S, Nisolle M. LASH: laparoscopic supracervical (subtotal) hysterectomy. *Zentralbl*

- Gynakol* 1995; **117**: 629-632 [PMID: 8585357]
- 17 **Hutchins FL Jr**, Reinoehl EM. Retained myoma after laparoscopic supracervical hysterectomy with morcellation. *J Am Assoc Gynecol Laparosc* 1998; **5**: 293-295 [PMID: 9668153 DOI: 10.1016/s1074-3804(98)80035-2]
- 18 **Levy G**, Hill MJ, Plowden TC, Catherino WH, Armstrong AY. Biomarkers in uterine leiomyoma. *Fertil Steril* 2013; **99**: 1146-1152 [PMID: 23200685 DOI: 10.1016/j.fertnstert.2012.10.048]
- 19 **Lete I**, González J, Ugarte L, Barbadillo N, Lapuente O, Álvarez-Sala J. Parasitic leiomyomas: a systematic review. *Eur J Obstet Gynecol Reprod Biol* 2016; **203**: 250-259 [PMID: 27359081 DOI: 10.1016/j.ejogrb.2016.05.025]
- 20 **Food and Drug Administration**. Quantitative assessment of the prevalence of unsuspected uterine sarcoma in women undergoing treatment of uterine fibroids. [cited 17 April 2014]. In: Food and Drug Administration [Internet]. Available from: <https://www.fda.gov/media/88703/download>
- 21 **Wong M**, De Wilde RL, Isaacson K. Reducing the spread of occult uterine sarcoma at the time of minimally invasive gynecologic surgery. *Arch Gynecol Obstet* 2018; **297**: 285-293 [PMID: 29128980 DOI: 10.1007/s00404-017-4575-6]
- 22 **Cohen SL**, Morris SN, Brown DN, Greenberg JA, Walsh BW, Gargiulo AR, Isaacson KB, Wright KN, Srouji SS, Anchan RM, Vogell AB, Einarsson JI. Contained tissue extraction using power morcellation: prospective evaluation of leakage parameters. *Am J Obstet Gynecol* 2016; **214**: 257.e1-257.e6 [PMID: 26348384 DOI: 10.1016/j.ajog.2015.08.076]
- 23 **Parker W**. Parasitic myomas may be more common than we think. *BJOG* 2016; **123**: 76 [PMID: 26335152 DOI: 10.1111/1471-0528.13573]
- 24 **Bretthauer M**, Goderstad JM, Löberg M, Emilsson L, Ye W, Adami HO, Kalager M. Uterine morcellation and survival in uterine sarcomas. *Eur J Cancer* 2018; **101**: 62-68 [PMID: 30025231 DOI: 10.1016/j.ejca.2018.06.007]



Published by **Baishideng Publishing Group Inc**
7041 Koll Center Parkway, Suite 160, Pleasanton, CA 94566, USA

Telephone: +1-925-3991568

E-mail: bpgoffice@wjgnet.com

Help Desk: <https://www.f6publishing.com/helpdesk>

<https://www.wjgnet.com>

