

Visual Diagnosis in Emergency Medicine

A CHILD WITH PYOMYOSITIS OF THE ABDOMINAL WALL DETECTED WITH POINT-OF-CARE ULTRASOUND

Yura Ko, MD,* Jae Sung Yun, MD,†‡ and Jung Heon Kim, MD*

*Department of Emergency Medicine, Ajou University School of Medicine, Suwon, Republic of Korea, †Department of Radiology, Ajou University School of Medicine, Suwon, Republic of Korea, and ‡Musculoskeletal Imaging Laboratory, Ajou University Medical Center, Suwon, Republic of Korea

Reprint Address: Jung Heon Kim, MD, Department of Emergency Medicine, Ajou University School of Medicine, 164 World cup-ro, Yeongtong-gu, Suwon 16499, Republic of Korea

INTRODUCTION

Pyomyositis is a primary bacterial infection of the skeletal muscles, presenting with fever and muscle pain. The pelvis and legs are often involved, but in 1.6–3%, the abdominal wall is also affected (1–3). The etiology may be related to transient bacteremia (chiefly, *Staphylococcus aureus*) and muscle injury (20%–50%) (1,4). This entity shows three stages (1,3,4). During the first or second weeks, bacteria invade the muscles, causing subtle pain without abscess. An abscess then develops during the second and third weeks, when most diagnoses are obtained. Later, poorly treated abscess may lead to sepsis.

We report a pediatric case of pyomyositis of the abdominal wall, diagnosis of which was facilitated by use of point-of-care ultrasound (POCUS).

CASE REPORT

A previously healthy 12-year-old girl presented to the Emergency Department with 1-day history of right pelvic pain and fever. No other symptoms or skin lesions were noted. The girl denied any recent trauma, strenuous exercise, or medical procedure. She was alert and well looking, and the initial vital signs were as follows: blood pressure

122/81 mm Hg, heart rate 142 beats/min, respiratory rate 20 breaths/min, and temperature 38.5°C. The pain was localized just medial to the right anterior superior iliac spine, with minimal tenderness. We noted the absence of abdominal tenderness and no limited hip motion.

White blood cell count, erythrocyte sedimentation rate, and concentration of C-reactive protein (CRP) were $9.3 \times 10^3/\mu\text{L}$ (reference value, 3.4–10.6) with 81.2% neutrophils (33.0–74.0), 2 mm/h (<25), and 0.7 mg/dL (<0.5), respectively. Serum electrolytes, glucose, creatinine, aminotransferases, and urinalysis were within normal limits. No fracture, intestinal perforation, or obstruction were noted on plain radiographs. The left and right hip joint effusions were measured as 23 and 27 mm in depth, respectively (reference value of difference, < 2 mm), on POCUS using HM70 A (Samsung Medison, Seongnam, Korea) (5). Abdominopelvic computed tomography was negative for appendicitis, abscess, and tumor. She was presumed to have a viral infection-related myalgia, and discharged.

Three days later, the girl returned to us with worsening pain and persistent fever. Her appearance remained good, and the vital signs at this point were as follows: blood pressure 138/78 mm Hg, heart rate 130 beats/min, respiratory rate 20 breaths/min, and temperature 37.8°C. The painful region had widened, and tenderness became

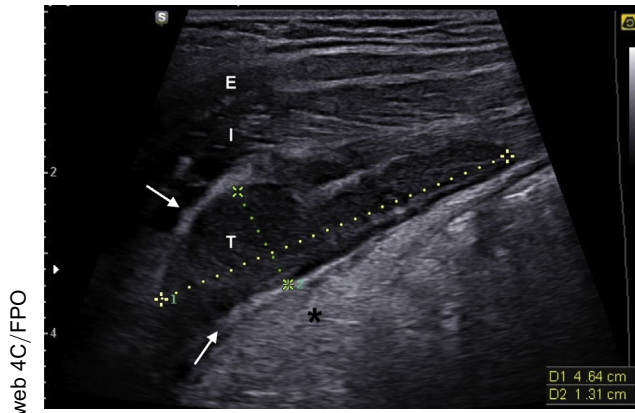


Figure 1. Transverse scan with a linear transducer showing a 46×13 mm-sized (dotted calipers), well-demarcated, ovoid, slightly hypoechoic lesion in the right transversus abdominis muscle, suggesting an intramuscular phlegmon or early abscess. Despite the lack of definite fluid inside the lesion, the possibility of early abscess is supported by the posterior acoustic enhancement (asterisk). The inflamed fascia of the muscle appears echogenic (arrows). E indicates the external oblique; I, the internal oblique; and T, the transversus abdominis.

more prominent. Concentrations of CRP and creatine kinase were 2.4 mg/dL and 60 U/L (reference value, 26–192), respectively.

With suspicion of an abscess of the abdominal wall, we performed POCUS on the painful region using the aforementioned device. This examination showed an abscess in the right transversus abdominis muscle (Figure 1) (c.f., see the left side in Supplementary Figure 1, available online). No foreign body, mass, or fascial violation was observed. On the same day, a radiologist confirmed that the lesion was an abscess (Supplementary Figure 2, available online).

With a presumptive diagnosis of pyomyositis, the girl was hospitalized in the surgical ward and received intravenous antibiotics. On day 2, pelvic magnetic resonance imaging (MRI) showed pyomyositis with secondary osteomyelitis of the right ilium (Figure 2). On the following day, ultrasound-guided needle aspiration of the abscess was performed (Figure 3). Culture of the aspirated pus identified methicillin-susceptible *S. aureus*, and blood culture showed no growth after 5 days. On day 6 she was discharged uneventfully.

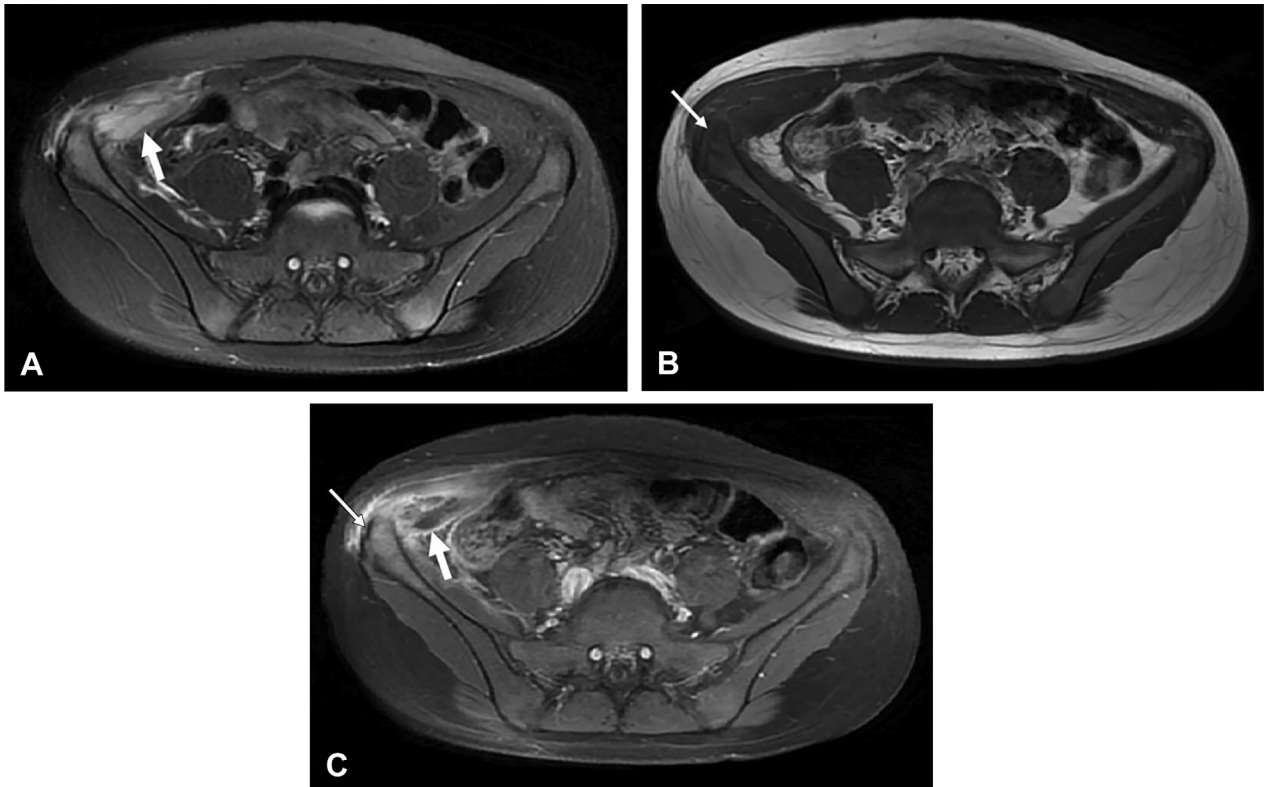


Figure 2. Findings of magnetic resonance imaging, suggesting pyomyositis of the right transversus abdominis muscle with concomitant osteomyelitis of the adjacent ilium. (A) Axial fat-suppressed T2-weighted image shows fluid collection with swelling in the muscle (thick arrow). (B) Axial T1-weighted image shows decreased signal in the adjacent ilium (thin arrow). (C) Axial contrast-enhanced fat-suppressed T1-weighted image shows inhomogeneous enhancement, suggesting an intramuscular abscess (thick arrow). Mild enhancement is also seen in the adjacent ilium (thin arrow), and is considered the osteomyelitis.

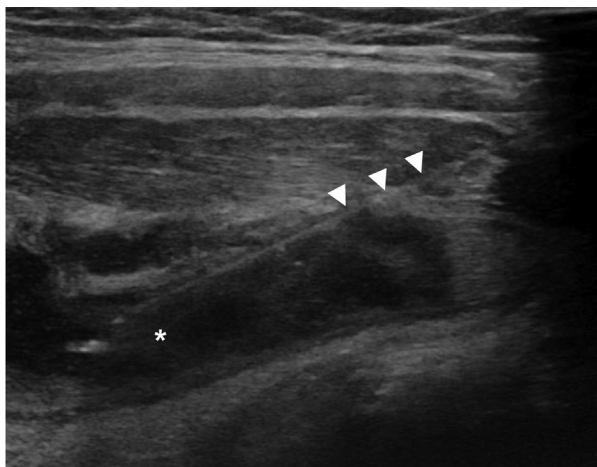


Figure 3. Ultrasound-guided needle aspiration of the abscess performed by a radiologist on day 3. It shows a needle (arrowheads) inserted into the fluid in a larger amount (asterisk) than in Figure 1.

DISCUSSION

This case points to the usefulness of POCUS in screening for pyomyositis of the abdominal wall. This entity has a broad list of differential diagnoses, including appendicitis, iliopsoas abscess, septic arthritis, pelvic inflammatory disease, tumors, and avulsion fractures of the pelvis. Although MRI is a preferred modality, it requires a long scan time and sedation, and its availability is limited in emergency settings (1,4,6). Meanwhile, POCUS is a useful screening tool for emergency physicians because it is quick, noninvasive, and repeatable (1,4,6). By using this tool to screen for pyomyositis, MRI can be performed in anatomically focused areas. The strengths of POCUS may be more highlighted by the superficial location of lesions, abscess formation at the second stage, and need for ruling out surgical emergencies, as in our case.

POCUS was useful and technically easy in this case. A 3–16-MHz linear transducer was placed just medial to the right anterior superior iliac spine with the case patient in the supine position and with the indicator on her right side. Subsequently, the lesion was found within several minutes, with minimal pressure on the abdomen. Given

the lack of abnormalities on computed tomography performed at the first visit, we did not evaluate the intraperitoneal structures using a curvilinear transducer. Although the screening efficacy of POCUS in children with pyomyositis has been reported, most cases have focused on lesions of the extremities (6–8).

The case patient obtained the correct diagnosis 4 days after the onset of symptoms. This delay might stem from the subtle initial manifestations, minimally elevated CRP concentration, and preferential suspicion of surgical emergencies at the first visit. The delayed diagnosis complicated osteomyelitis (3,9). However, the timing of diagnosis was within the expected range because abscess formation takes about 2 weeks. In fact, correct diagnosis may take an average of 10 days (2).

Pyomyositis of the abdominal wall is difficult to detect in emergency settings due to the broad list of differentials. POCUS, a screening tool for the entity, may be useful in selecting candidates for MRI for correct diagnosis.

APPENDIX ASUPPLEMENTARY DATA

Supplementary data related to this article can be found at <https://doi.org/10.1016/j.jemermed.2021.01.011>.

REFERENCES

1. Verma S. Pyomyositis in children. *Curr Infect Dis Rep* 2016;18:12.
2. Bickels J, Ben-Sira L, Kessler A, Wientroub S. Primary pyomyositis. *J Bone Joint Surg Am* 2002;84:2277–86.
3. Verma S, Singhi SC, Marwaha RK, Singhi P, Singh S, Singh M. Tropical pyomyositis in children: 10 years experience of a tertiary care hospital in northern India. *J Trop Pediatr* 2013;59:243–5.
4. Chauhan S, Jain S, Varma S, Chauhan SS. Tropical pyomyositis (myositis tropicans): current perspective. *Postgrad Med J* 2004;80:267–70.
5. Takundwa P, Chen L, Malik RN. Evaluation of hip pain and management of toxic synovitis in the ultrasound era. *Pediatr Emerg Care* 2021;37:34–8.
6. Farrell G, Berona K, Kang T. Point-of-care ultrasound in pyomyositis: a case series. *Am J Emerg Med* 2018;36:881–4.
7. Levitt DL, Byer R, Miller AF. Point-of-care ultrasound to diagnose pyomyositis in a child. *Pediatr Emerg Care* 2019;35:69–71.
8. Park E, Chilstrom M. Diagnosis of pyomyositis in a pediatric patient with point-of-care ultrasound. *West J Emerg Med* 2016;17:464–5.
9. Pannaraj PS, Hulten KG, Gonzalez BE, Mason EO Jr, Kaplan SL. Infective pyomyositis and myositis in children in the era of community-acquired, methicillin-resistant *Staphylococcus aureus* infection. *Clin Infect Dis* 2006;43:953–60.