



Minimally Invasive Treatment for Benign Parathyroid Lesions: Treatment Efficacy and Safety Based on Nodule Characteristics

Eun Ju Ha, MD¹, Jung Hwan Baek, MD², Sun Mi Baek, MD³

¹Department of Radiology, Ajou University School of Medicine, Suwon, Korea; ²Department of Radiology and Research Institute of Radiology, Asan Medical Center, University of Ulsan College of Medicine, Seoul, Korea; ³Department of Radiology, Haeundae Sharing and Happiness Hospital, Busan, Korea

Objective: This study aimed to evaluate the efficacy and safety of ultrasound (US)-guided minimally invasive treatment in patients with parathyroid lesions.

Materials and Methods: This study included 27 patients who had undergone US-guided radiofrequency ablation (RFA) or ethanol ablation (EA) for parathyroid lesions between January 2010 and 2018. RFA was performed in 19 patients with primary hyperparathyroidism (PHPT, n = 11) or secondary hyperparathyroidism (SHPT, n = 8), and EA was performed in eight patients with symptomatic nonfunctioning parathyroid cysts (SNPCs). Nodule size, volume, serum parathyroid hormone (PTH) and calcium levels were recorded before and after treatment. Complications were evaluated during and after treatment.

Results: In patients with PHPT, significant reductions in size and volume were noted after RFA at 6- and 12-month follow-up (all, $p < 0.05$). Seven nodules nearly completely disappeared (residual volume < 0.1 mL); serum PTH and calcium levels were reduced to normal ranges (7/11, 63.6%). Four patients experienced partial reductions of serum PTH and calcium levels (4/11, 36.4%). In patients with SHPT, three experienced therapeutic response of serum PTH (3/8, 37.5%), while five showed persistent hyperparathyroidism (5/8, 62.5%) within 6 months after RFA. In patients with SNPCs, EA resulted in significant reductions in cyst size and volume (all, $p < 0.05$) at the last follow-up. A total of four complications (two transient hypocalcemia [RFA], one permanent [RFA], and one transient [EA] hoarseness) were observed.

Conclusion: Minimally invasive treatments, such as RFA and EA, may serve as therapeutic alternatives for patients with PHPT or SNPCs; they may have limited usefulness in patients with SHPT.

Keywords: Parathyroid neoplasms; Parathyroid cyst; Radiofrequency ablation; Sclerotherapy

INTRODUCTION

Hyperparathyroidism is a common clinical entity characterized by elevated parathyroid hormone (PTH) levels in the blood. This results from a disorder either

within the parathyroid glands (primary hyperparathyroidism [PHPT]) or outside the parathyroid glands (secondary hyperparathyroidism [SHPT]) (1, 2). Since functional abnormalities including a high incidence of renal stones, severe bone disease, fractures, neuromuscular syndrome, or cardiovascular disease are common, patients with symptomatic hyperparathyroidism require treatment. Nonfunctioning parathyroid cysts are true cysts and are typically asymptomatic. However, large cysts can cause symptoms and require treatment (3).

Surgical parathyroidectomy is the standard treatment for patients with symptomatic PHPT (1). Although current drugs can reduce and normalize calcium levels in patients with SHPT, patients with severe hyperparathyroidism who fail to respond to medications require surgery (4). Simple

Received: January 17, 2020 **Revised:** April 17, 2020

Accepted: April 24, 2020

Corresponding author: Jung Hwan Baek, MD, Department of Radiology and Research Institute of Radiology, Asan Medical Center, University of Ulsan College of Medicine, 88 Olympic-ro 43-gil, Songpa-gu, Seoul 05505, Korea.

• E-mail: radbaek@naver.com

This is an Open Access article distributed under the terms of the Creative Commons Attribution Non-Commercial License (<https://creativecommons.org/licenses/by-nc/4.0>) which permits unrestricted non-commercial use, distribution, and reproduction in any medium, provided the original work is properly cited.

aspiration has been used as an initial diagnosis and treatment for symptomatic nonfunctioning parathyroid cysts (SNPCs); however, recurrence has been also reported in 66.7% and required additional treatment (3). Although surgery is generally safe, postoperative morbidity and mortality have been reported, specifically in elderly patients and in patients with other concurrent chronic diseases. Additionally, some patients with symptomatic hyperparathyroidism or SNPC either refuse surgery or are unsuitable candidates for surgery (5). Therefore, ultrasound (US)-guided minimally invasive treatments, such as radiofrequency ablation (RFA) and ethanol ablation (EA), have been suggested as alternative treatments to surgery for benign parathyroid lesions in patients who are ineligible for surgery (3, 6-22). This study aimed to evaluate the treatment efficacy and safety of US-guided RFA and EA in patients with parathyroid lesions based on nodule characteristics.

MATERIALS AND METHODS

The protocol of this study was approved by the Ethics Committees of the Institutional Review Boards of the three participating hospitals. Written informed consent was obtained from all patients before they underwent RFA or EA.

Patients

Between January 2010 and 2018, 28 patients with parathyroid lesions were eligible for RFA or EA in the three participating hospitals (Asan Medical Center, Haeundae Sharing and Happiness Hospital, and Ajou University Medical Center). RFA was performed in 11 patients with PHPT and 8 patients with SHPT. EA was performed in 9 patients with SNPCs. One patient was lost to follow-up after EA, and 27 patients were finally included in this study.

The criteria for performing RFA in patients with PHPT or SHPT were as follows: 1) PTH levels above the upper limit of the normal range (65 pg/mL); 2) positive technetium (99mTc)-sestamibi scan results and/or US examination results, and 3) refusal or ineligibility for surgery. The criteria for performing EA in patients with parathyroid cysts were as follows: 1) nonfunctioning parathyroid cysts without solid components, 2) cosmetic and/or pressure symptoms related to parathyroid cysts, and 3) recurrence after simple aspiration. We excluded parathyroid lesions with suspicious sonographic features (irregular shape, non-circumscribed margin, and local invasion) to rule out the

possibility of malignancy. We also excluded patients with history of thyroid or parathyroid surgery.

Preprocedural Assessment

US was performed in all patients before RFA or EA. Three radiologists, who had 22, 19, and 14 years of clinical experience, respectively, in performing and evaluating neck US images, performed all US examinations with one of the three US systems: an iU22 ultrasound machine (Philips Healthcare), an RS 80 (Samsung Medison Co., Ltd.), or an EUB-7500 HV (Hitachi Medical Systems). All three US systems were equipped with a high-frequency linear probe (5–14 MHz). The index nodule volume was calculated as $V = \pi abc/6$, where V is the volume, a is the largest diameter, and b and c are the other two perpendicular diameters. Biochemical data, including serum PTH and calcium levels, were collected from the patients before ablation.

Ablation Procedures

Both RFA and EA were performed in an outpatient setting. Each patient was placed in a supine position with the neck extended. After sterilization, vessels located along the approach route were identified, and 2% lidocaine was injected at the site of skin puncture. All procedures were performed by one of the three radiologists who had evaluated the preprocedural US images.

For RFA, an 18- or 19-gauge monopolar modified internally cooled electrode (VIVA, STARmed) with a 0.38-, 0.5-, 0.7-, or 1.0-cm active tip was used together with a radiofrequency generator (VIVA RF generator, STARmed) and a peristaltic pump (VIVA pump, STARmed). A 5% dextrose solution was injected to create a hydrodissection around the lesion. Subsequently, the ablation needle was inserted into the parathyroid lesions under US guidance. Ablation was performed with 10–70 W of radiofrequency power according to the size of the treated nodule and active tip. During the procedure, continuous slow injection of a 5% dextrose solution was performed to prevent thermal injury to the critical structures, including the recurrent laryngeal nerve (RLN), esophagus, and trachea. Ablation was terminated when the entire target lesion was covered with hyperechoic microbubbles. In patients with SHPT, one or more of the dominant parathyroid nodules was ablated based on the 99mTc-sestamibi scan and US results.

For EA, an 18-gauge needle was inserted via the normal thyroid tissue to minimize leakage of ethanol outside of the cyst. Following aspiration of cystic fluid, 99% sterile

ethanol was injected through the same needle. The amount of injected ethanol was less than 50% of the aspirated fluid volume. After 5–10 minutes with the needle in place, the injected ethanol was removed completely, and the needle was withdrawn.

Complications were evaluated both during and immediately after the procedure. Each patient was observed for 2 hours after RFA and for 30 minutes after EA in the hospital.

Follow-Up and Outcome Assessment

Patients were followed up at 1, 6, and 12 months after the procedure. Changes in the size and volume of the treated nodule and in the biochemical data, including serum PTH and calcium levels, were calculated at each follow-up period. Adverse events that were observed during the follow-up period were noted. Patients with persistent hyperparathyroidism and residual undertreated vital gland present on US a few months (generally, 1–3 months) after treatment were advised to consider a second ablation.

In patients with PHPT, the criteria for a complete response were defined as serum PTH and calcium levels reduced to within normal ranges (< 65 pg/mL for PTH and 8.5–10.3 mg/dL for calcium) at the last follow-up. The criteria for a partial response were as follows: reduced serum PTH levels that remained above the upper limit of normal (> 65 pg/mL) or serum calcium levels that remain above the upper limit of normal (> 10.3 mg/dL) after treatment. The criteria for persistent disease were as follows: serum PTH or calcium levels after treatment that were unchanged or above baseline levels measured before treatment (10).

In patients with SHPT, the criteria for a therapeutic response were as follows: serum PTH levels that had decreased to the target range (130–585 pg/mL) and remained within that range for 6 months (4). The criteria for no response were as follows: serum PTH levels outside

the target range or higher than baseline levels (measured before treatment) within 6 months after RFA (4). In patients with SNPC, treatment outcome was assessed using the volume reduction ratio (VRR) after EA.

Statistical Analyses

Statistical analyses were performed using the Statistical Package for the Social Sciences (SPSS) for Windows statistical software package version 23.0 (IBM Corp.). The Wilcoxon signed-rank test was used to compare nodule size, volumes, and biochemical data before treatment and at the last follow-up after treatment. Continuous variables are presented as mean \pm standard deviation, and categorical variables are presented as frequency. *P* values < 0.05 were considered statistically significant.

RESULTS

Patient Demographics and Clinical Characteristics

The baseline clinical and treatment characteristics of the patients are summarized in Table 1. In the PHPT group, RFA was performed in 11 patients with the mean follow-up duration of 13.6 ± 18.7 months (range, 3–69 months). The mean serum PTH level was 190.2 ± 205.0 pg/mL (range, 67.9–784 pg/mL), and the mean serum calcium level was 10.6 ± 0.6 mg/dL (range, 9.5–11.5 mg/dL). Ten patients underwent one treatment session, while one patient underwent two treatment sessions. In the SHPT group, RFA was performed in eight patients with the mean follow-up duration of 25.9 ± 29.7 months (range, 9–98 months) (one [*n* = 3], two [*n* = 2], or three [*n* = 3] lesions with parathyroid hyperplasia). The mean serum PTH level was 950.4 ± 470.1 pg/mL (range, 380–1977 pg/mL), and the mean serum calcium level was 9.8 ± 1.0 mg/dL (range, 9.3–12.1 mg/dL). Patients underwent one to three treatment sessions per nodule (mean, 1.6 ± 0.9).

Table 1. Clinical and Treatment Characteristics of Patients with Parathyroid Lesions Included in this Study

	PHPT (n = 11)	SHPT (n = 8)	SNPCs (n = 8)
Age (years)	64.8 \pm 15.0	61.6 \pm 17.3	49.0 \pm 12.3
Sex (male:female)	2:9	3:5	2:6
Size (cm)	2.0 \pm 0.9 (0.6–3.8)	1.7 \pm 0.7 (0.9–2.7)	4.4 \pm 1.1 (3.0–5.6)
Volume (mL)	1.2 \pm 1.0 (0.1–3.3)	1.4 \pm 1.4 (0.2–5.7)	19.3 \pm 11.9 (4.1–37.3)
Treatment sessions per nodule	1.1 \pm 0.3	1.6 \pm 0.9	1.0 \pm 0.0
Ablation time per nodule (min)	3.7 \pm 3.4	3.3 \pm 1.3	5–10
Treatment method	Radiofrequency ablation	Radiofrequency ablation	Ethanol ablation

Values are shown as mean \pm standard deviation unless otherwise indicated. Numbers in parenthesis are ranges. PHPT = primary hyperparathyroidism, SHPT = secondary hyperparathyroidism, SNPCs = symptomatic nonfunctioning parathyroid cyst

EA was performed in eight patients with SNPCs. The mean follow-up duration was 5.6 ± 8.4 months (range, 1–27 months). All patients underwent one treatment session.

Treatment Efficacy

Table 2 lists the changes in size, volume, and laboratory test data after treatment in patients with PHPT. Significant reductions in the mean size and volume of the ablated nodule were noted after RFA ($p = 0.003$ for both). The mean VRR was 91.7% at 12-month follow-up. Among the 11 parathyroid adenomas treated, seven had nearly completely disappeared at the last follow-up (residual volume < 0.1 mL, 63.6%). The mean serum PTH and calcium levels significantly decreased from 190.2 ± 205.0 to 45.9 ± 22.5 pg/mL and from 10.6 ± 0.6 to 9.4 ± 0.7 mg/dL, respectively ($p = 0.003$ and $p = 0.007$, respectively). Serum PTH and calcium levels were within the normal ranges in seven of the 11 patients (63.6%) (Fig. 1). Among the four patients with a partial response, one underwent surgery due to an overlooked double parathyroid adenoma on the contralateral side, which showed an increase in size on follow-up US after RFA. Analysis of the surgical specimen confirmed complete necrosis of the treated right adenoma and a viable untreated left parathyroid adenoma (Fig. 2). Two females (aged 92 and 87 years, respectively) could not be fully treated because of limited cooperation and refusal to undergo additional treatment. One patient showed complete disappearance of the nodule after treatment, but serum PTH level remained slightly above the normal range (68.5 pg/mL) at the last follow-up.

Table 3 lists the changes in size, volume, and laboratory test data after treatment in patients with SHPT. Significant reductions in the mean size and volume of the ablated nodule were noted after RFA ($p = 0.001$ for both). However, among the eight patients with SHPT, three experienced a therapeutic response with a reduction in serum PTH level (3/8, 37.5%), while five showed no response in

terms of serum PTH level and had persistent symptomatic hyperparathyroidism within 6 months after RFA (5/8, 62.5%) (Fig. 3). The serum PTH and calcium levels were insignificantly changed at the last follow-up ($p = 0.449$ and $p = 1.000$, respectively). Multiple treatment sessions (two sessions for four patients and three sessions for three patients) were required in seven patients (7/8, 87.5%) within 6 months after the initial treatment. Among them, two patients showed therapeutic responses, while five patients showed no responses on follow-up evaluations.

Table 4 lists the changes in cyst size and volume after treatment in patients with SNPCs. Significant reductions in size and volume were noted at the last follow-up ($p = 0.012$). The mean volume decreased from 19.3 ± 11.9 to 0.1 ± 0.1 mL after EA, and the mean VRR was 98.5% (Fig. 4).

Complications

RFA and EA procedures were safely performed, and none of the patients required hospitalization after treatment. Permanent voice change was observed in one patient with SHPT after two sessions of RFA and was not recovered at 1-year follow-up examinations. Transient voice change was observed in one patient with SNPCs after EA; this complication recovered spontaneously within 2 months. Transient hypocalcemia was observed in one patient with PHPT and in one patient with SHPT after RFA. This complication was recovered with a few days, through the use of medication. There were no life-threatening complications.

DISCUSSION

Our findings demonstrated that RFA could significantly reduce PTH and calcium levels in patients with PHPT; however, it commonly showed transient efficacy and failed to prevent the recurrence of symptomatic hyperparathyroidism in patients with SHPT. EA could be

Table 2. Changes in Ultrasound Features and Laboratory Tests after Radiofrequency Ablation in Patients with Primary Hyperparathyroidism

	Baseline (n = 11)	1 Month (n = 11)	6 Months (n = 10)	12 Months (n = 5)	P
Size (cm)	2.0 ± 0.9	1.3 ± 0.7	0.9 ± 0.6	0.3 ± 0.5	0.003
Volume (mL)	1.2 ± 1.0	0.6 ± 0.8	0.2 ± 0.2	0.03 ± 0.04	0.003
Volume reduction rate (%)	-	54.7	87.6	91.7	
PTH level (pg/mL)	190.2 ± 205.0	98.6 ± 78.0	66.7 ± 34.6	45.9 ± 22.5	0.003
Calcium level (mg/dL)	10.6 ± 0.6	9.0 ± 1.0	9.4 ± 0.7	9.4 ± 0.7	0.007

Values are shown as mean \pm standard deviation unless otherwise indicated. P values were calculated using data before treatment and at last follow-up after treatment. Normal ranges were < 65 pg/mL for PTH and 8.5–10.3 mg/dL for calcium. PTH = parathyroid hormone

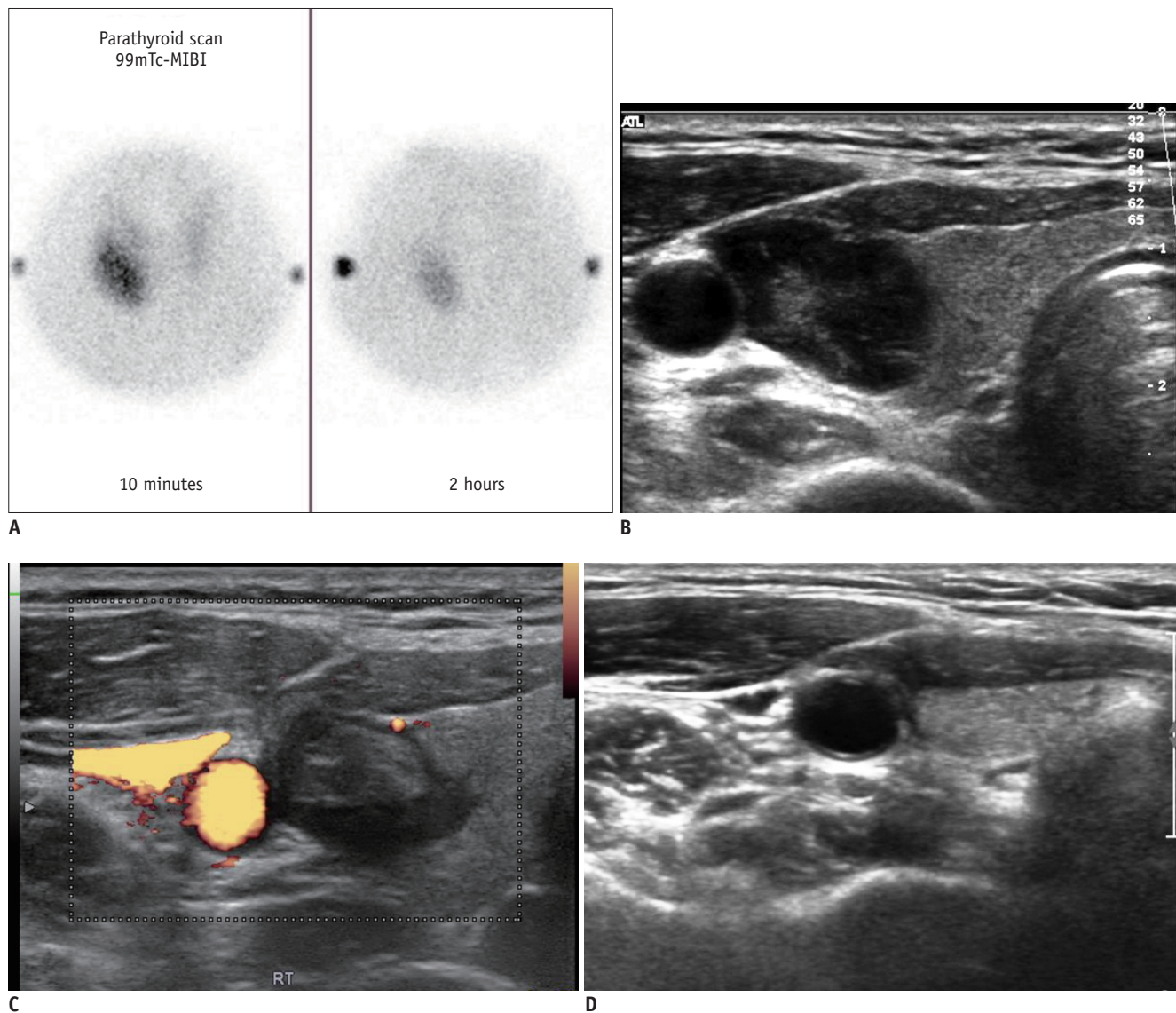


Fig. 1. A 52-year-old female with primary hyperparathyroidism.

A, B. Technetium-sestamibi scan and US examination revealed right parathyroid adenoma. **C, D.** After radiofrequency ablation, volume of nodule gradually decreased and disappeared on serial follow-up US (3 and 69 months after treatment, respectively). Serum PTH and calcium levels were decreased and remained in normal range at 69-month follow-up after treatment (serum PTH, from 223 pg/mL to 30.3 pg/mL; calcium, from 12.5 mg/dL to 8.9 mg/dL). PTH = parathyroid hormone, US = ultrasound

an effective treatment option for patients with SNPCs. Voice change and hypocalcemia may occur after RFA or EA. Although this complication was rare, operators should be aware of the possibility of these complications.

For patients with PHPT, thermal ablation techniques have been suggested as alternatives to surgery since 2010 (6-16, 23, 24). Recent studies have reported the potential efficacies of these approaches: the complete remission rate may reach 86.7% with a mean follow-up duration of 12 months (10). Thus far, RFA has been reported in limited numbers of patients (1-9 patients per study) (6-

9). In our study, among the 11 patients treated, complete disappearance of the nodule and biochemical remission were reported in seven patients (63.6%). Although PTH failed to reach normal levels in four patients (36.4%), one patient showed complete necrosis of the treated nodule on the surgical specimen, and one patient showed complete disappearance of the treated nodule on US with serum PTH level of 68.5 pg/mL. The remaining two patients failed to reach normal PTH levels due to partial ablation in patients who were older and showed limited cooperation. A few residual adenomatous parathyroid cells

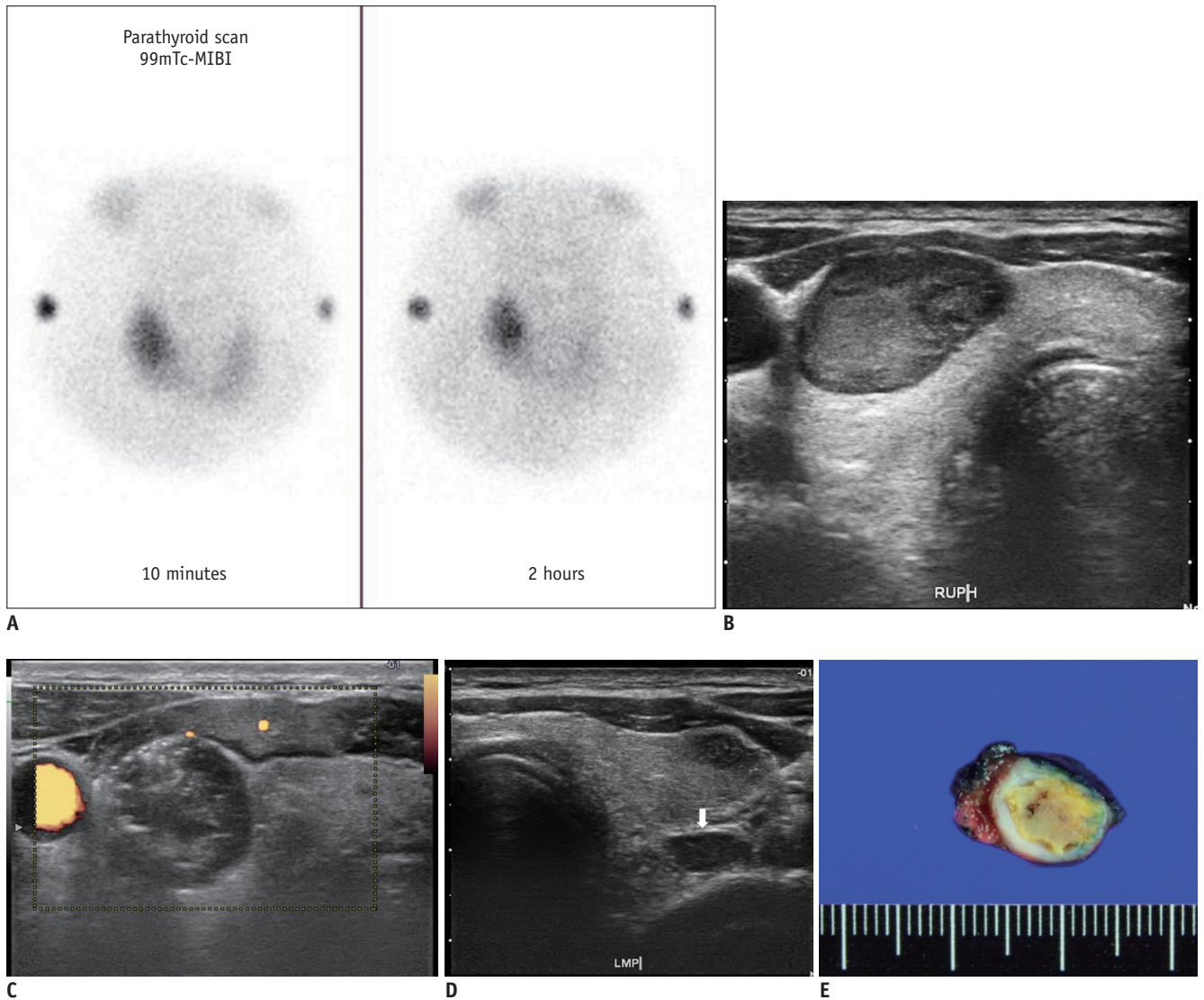


Fig. 2. A 71-year-old female with primary hyperparathyroidism.

A, B. Technetium-sestamibi scan and US examination revealed right intrathyroidal parathyroid adenoma. **C, D.** After radiofrequency ablation, volume of treated nodule decreased; however, overlooked double parathyroid adenoma showed increase on contralateral side (arrow) on 3-month follow-up US (serum parathyroid hormone, from 146 pg/mL to 113 pg/mL; calcium, from 11.1 mg/dL to 10.3 mg/dL). **E.** Surgical specimen revealed complete necrosis of right treated adenoma.

Table 3. Changes in Ultrasound Features and Laboratory Tests after Radiofrequency Ablation in Patients with Secondary Hyperparathyroidism

	Baseline (n = 8)	1 Month (n = 8)	6 Months (n = 8)	12 Months (n = 6)	<i>P</i>
Size (cm)	1.7 ± 0.6	1.2 ± 0.5	1.0 ± 0.4	0.8 ± 0.3	0.001
Volume (mL)	1.4 ± 1.4	0.9 ± 1.0	0.4 ± 0.4	0.2 ± 0.1	0.001
Volume reduction rate (%)	-	46.6	71.2	86.3	
PTH level (pg/mL)	950.4 ± 470.1	698.0 ± 384.1	1198.7 ± 1016.0	296.2 ± 130.9*	0.499
Calcium level (mg/dL)	9.8 ± 1.0	9.5 ± 1.3	9.0 ± 0.8	10.5 ± 2.1	1.000

Values are shown as mean ± standard deviation unless otherwise indicated. *P* values were calculated using data before treatment and at last follow-up after treatment. Reasonable PTH levels were < 585 pg/mL and excessive PTH levels were ≥ 585 pg/mL. *After 6 month of follow-up, two patients with uncontrolled high serum PTH levels (1650 and 2990 pg/mL) underwent surgery and three patients underwent additional treatments.

led to partial remission of hyperparathyroidism. Microwave ablation has been reported with a relatively larger number of patients (1–28 patients per study) and longer follow-

up durations (mean, 6–32.8 months per study) (10–13). Complete remission rates have been reported above 80% after 1–3 treatment sessions per nodule. Therefore, based on the findings of the present study, we suggest that RFA may be a possible treatment option for patients with PHPT; however, careful pre- and post-procedural US evaluations are necessary for therapeutic success.

For patients with SHPT, several studies have reported variable outcomes after thermal ablations (17–22, 25–27). Regarding microwave ablation, Zhuo et al. (20) showed marked reductions of serum PTH level from 1203 pg/mL to 400 pg/mL and serum calcium level from 2.53 mmol/L to 2.33 mmol/L with a mean follow-up duration of 11.1 months. Conversely, Diao et al. (18) reported that 61.54% (16/26) of nodules were nonresponsive. One paper has been reported using the RFA so far (27). They reported a reasonable PTH level in 44.1% (15/34) and excessive PTH level in 55.9% (19/34) at 1 year after ablation. In our study, three patients showed a therapeutic response (37.5%, 3/8), whereas five showed persistent disease (62.5%, 5/8) after 6 months. It was common for patients to experience growth of untreated small parathyroid lesions after treatment of the most prominent lesion. Therefore, we hypothesize that repeated treatments are required for patients with SHPT to maintain the serum PTH and calcium levels at a certain level. A gradual, step-by-step, approach should be considered for the treatment of selected patients with SHPT.

Several studies have demonstrated successful treatment of patients with SNPCs by simple aspiration, with therapeutic success rates ranging from 33% to 92% (3, 28–31). However, in patients with recurring symptomatic cysts, chemical ablation may be a suitable treatment option (3). In our study, the therapeutic success of EA was 100%. However, there remains a concern regarding leakage of ethanol along the needle track. One patient also experienced a transient voice change. Sung et al. (3) proposed that insertion of the needle through sufficient normal thyroid parenchyma, using a technique known as the trans-isthmus approach, could minimize ethanol leakage in the treatment of thyroid cysts. This method can also be used for the treatment of parathyroid cysts to prevent ethanol leakage and potentially reduce complications.

In terms of safety, voice change was observed in two patients after treatment. Because the RLN is anatomically close to the parathyroid gland, prevention of RLN injury is extremely important when treating parathyroid lesions

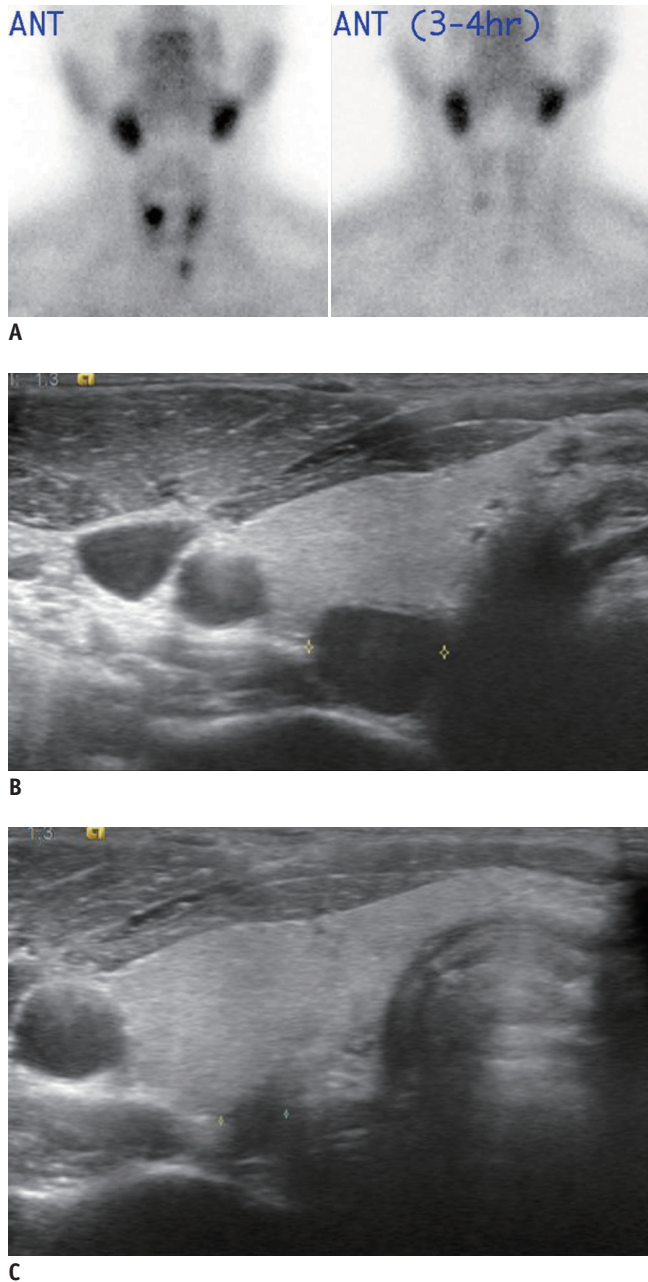


Fig. 3. A 32-year-old male with secondary hyperparathyroidism. A, B. Technetium-sestamibi scan and US examination revealed three parathyroid hyperplasias (sonographic image of left hyperplasia is not presented here). C. After ablation of three lesions with hyperplasia, serum PTH and calcium levels were within target range (serum PTH, 1043 pg/mL → 1008 pg/mL → 251.3 pg/mL; calcium, 9.5 mg/dL → 8.9 mg/dL → 8.8 mg/dL at 9 months after initial treatment). However, new small parathyroid lesion was detected in right lower aspect, and serum PTH level tended to increase again during the follow-up (serum PTH, 435 pg/mL; calcium, 9.7 mg/dL at 18 months after initial treatment).

Table 4. Changes in Ultrasound Features after Ethanol Ablation in Patients with Symptomatic Nonfunctioning Parathyroid Cysts

	Baseline (n = 8)	1–2 Month (n = 8)	3–6 Months (n = 4)	<i>P</i>
Size (cm)	4.4 ± 1.1	1.6 ± 0.8	0.4 ± 0.3	0.012
Volume (mL)	19.3 ± 11.9	1.2 ± 1.5	0.1 ± 0.1	0.012
Volume reduction rate (%)		91.4	98.5	

Values are shown as mean ± standard deviation. *P* values were calculated using data before treatment and at the last follow-up after treatment.

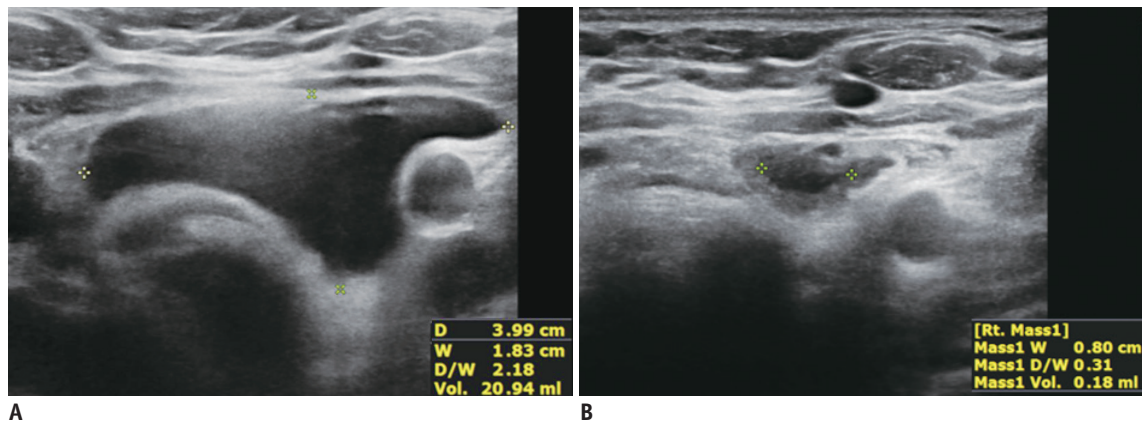


Fig. 4. A 47-year-old female with parathyroid cyst.

A. US examination revealed left parathyroid cyst. **B.** After ethanol ablation, volume of treated cyst markedly decreased and nearly disappeared at 1-month follow-up.

(32–34). Therefore, a hydrodissection technique (injection of a 5% dextrose solution between the nerve and the tumor) is essential for the prevention of thermal injury. It is a significantly safe and effective way to perform RFA of benign thyroid nodules and recurrent thyroid cancers that are located close to the critical structures. It could be also applied for RFA of benign parathyroid lesions (32–34). With this method, the distance between the RLN and the parathyroid lesion can be increased, and complete ablation is possible while preventing complications (32–34). The use of a small active tip, including 0.38 cm of the electrode, also helps to minimize RLN injury and assists in puncturing the smaller parathyroid lesions (34). Transient hypocalcemia after RFA was also observed in patients with PHPT or SHPT; this symptom was treated through the use of medication. None of the patients experienced skin burns, hematomas, infections, or other serious complications during or after ablation.

This study has a few limitations. First, the number of patients enrolled in the study was relatively small. Second, the follow-up duration was relatively short. A follow-up study is required to determine the long-term effectiveness of this treatment. Third, for patients with SHPT, the number of treated nodules per patient was from one to three since we usually ablated larger most functioning parathyroid

lesions first based on the results of parathyroid scan and US images. More multiple sessions and complete 4-gland ablation might be helpful for patients who did not have therapeutic response in this study. Further studies are required to identify the advantages and disadvantages of the additional treatment in these patients. However, despite these limitations, our study has some strengths. First, we tried to evaluate the clinical efficacy and safety of minimally invasive treatment for three different types of benign parathyroid lesions (PHPT, SHPT, and SNPC). Second, we revealed that the treatment efficacy may differ according to the nodule characteristics (PHPT vs. SHPT). There have been no studies comparing the treatment efficacy of RFA for patients with PHPT and SHPT so far. This basic concept is important for treating benign parathyroid lesions. Third, this study was designed as a multicenter study.

In conclusion, minimally invasive treatments, such as RFA and EA, may serve as therapeutic alternatives for patients with PHPT or SNPCs. However, they may not prevent the recurrence of symptomatic hyperparathyroidism in patients with SHPT.

Conflicts of Interest

No authors has financial disclosure or conflict of interest except Dr. Baek JH. He has been consultant of two

radiofrequency companies, STARmed and RF Medical, since 2017.

ORCID iDs

Eun Ju Ha

<https://orcid.org/0000-0002-1234-2919>

Jung Hwan Baek

<https://orcid.org/0000-0003-0480-4754>

Sun Mi Baek

<https://orcid.org/0000-0001-8075-0730>

REFERENCES

- Fraser WD. Hyperparathyroidism. *Lancet* 2009;374:145-158
- Huppert BJ, Reading CC. Parathyroid sonography: imaging and intervention. *J Clin Ultrasound* 2007;35:144-155
- Sung JY, Baek JH, Kim KS, Lee D, Ha EJ, Lee JH. Symptomatic nonfunctioning parathyroid cysts: role of simple aspiration and ethanol ablation. *Eur J Radiol* 2013;82:316-320
- Kidney Disease: Improving Global Outcomes (KDIGO) CKD-MBD Update Work Group. KDIGO 2017 Clinical practice guideline update for the diagnosis, evaluation, prevention, and treatment of chronic kidney disease-mineral and bone disorder (CKD-MBD). *Kidney Int Suppl (2011)* 2017;7:1-59
- Jin J, O'Connell E, O'Leary DP, Liew A, Redmond HP. Focused versus bilateral parathyroid exploration for primary hyperparathyroidism: a systematic review and meta-analysis. *Ann Surg Oncol* 2017;24:1924-1934
- Korkusuz H, Wolf T, Grünwald F. Feasibility of bipolar radiofrequency ablation in patients with parathyroid adenoma: a first evaluation. *Int J Hyperthermia* 2018;34:639-643
- Sormaz IC, Poyanlı A, Açar S, İşcan AY, Özgür I, Tunca F, et al. The results of ultrasonography-guided percutaneous radiofrequency ablation in hyperparathyroid patients in whom surgery is not feasible. *Cardiovasc Intervent Radiol* 2017;40:596-602
- Kim BS, Eom TI, Kang KH, Park SJ. Radiofrequency ablation of parathyroid adenoma in primary hyperparathyroidism. *J Med Ultrason* (2001) 2014;41:239-243
- Xu SY, Wang Y, Xie Q, Wu HY. Percutaneous sonography-guided radiofrequency ablation in the management of parathyroid adenoma. *Singapore Med J* 2013;54:e137-e140
- Fan BQ, He XW, Chen HH, Zhang WM, Tang W. US-guided microwave ablation for primary hyperparathyroidism: a safety and efficacy study. *Eur Radiol* 2019;29:5607-5616
- Liu C, Wu B, Huang P, Ding Q, Xiao L, Zhang M, et al. US-guided percutaneous microwave ablation for primary hyperparathyroidism with parathyroid nodules: feasibility and safety study. *J Vasc Interv Radiol* 2016;27:867-875
- Cao XL, Cheng ZG, Yu XL, Han ZY, Liang P. Ultrasound-guided percutaneous microwave ablation of parathyroid adenoma. *J Vasc Interv Radiol* 2016;27:1929-1931
- Liu F, Yu X, Liu Z, Qiao Z, Dou J, Cheng Z, et al. Comparison of ultrasound-guided percutaneous microwave ablation and parathyroidectomy for primary hyperparathyroidism. *Int J Hyperthermia* 2019;36:835-840
- Kovatcheva RD, Vlahov JD, Shinkov AD, Borissova AM, Hwang JH, Arnaud F, et al. High-intensity focused ultrasound to treat primary hyperparathyroidism: a feasibility study in four patients. *AJR Am J Roentgenol* 2010;195:830-835
- Kovatcheva R, Vlahov J, Stoinov J, Lacoste F, Ortuno C, Zaletel K. US-guided high-intensity focused ultrasound as a promising non-invasive method for treatment of primary hyperparathyroidism. *Eur Radiol* 2014;24:2052-2058
- Ambrosini CE, Cianferotti L, Picone A, Torregrossa L, Segnini G, Frustaci G, et al. High-intensity focused ultrasound as an alternative to the surgical approach in primary hyperparathyroidism: a preliminary experience. *J Endocrinol Invest* 2011;34:655-659
- Diao Z, Liu X, Qian L, Liu J, Liu S, Liu W. Efficacy and its predictor in microwave ablation for severe secondary hyperparathyroidism in patients undergoing haemodialysis. *Int J Hyperthermia* 2016;32:614-622
- Diao Z, Wang L, Li D, Liu W. Efficacy of microwave ablation for severe secondary hyperparathyroidism in subjects undergoing hemodialysis. *Ren Fail* 2017;39:140-145
- Zhao J, Qian L, Zu Y, Wei Y, Hu X. Efficacy of ablation therapy for secondary hyperparathyroidism by ultrasound guided percutaneous thermoablation. *Ultrasound Med Biol* 2016;42:1058-1065
- Zhuo L, Peng LL, Zhang YM, Xu ZH, Zou GM, Wang X, et al. US-guided microwave ablation of hyperplastic parathyroid glands: safety and efficacy in patients with end-stage renal disease-a pilot study. *Radiology* 2017;282:576-584
- Zhuo L, Zhang L, Peng LL, Yang Y, Lu HT, Chen DP, et al. Microwave ablation of hyperplastic parathyroid glands is a treatment option for end-stage renal disease patients ineligible for surgical resection. *Int J Hyperthermia* 2019;36:29-35
- Wang G, Liu S, Liu X, Qian L, Diao Z, Liu W. Microwave ablation: an effective treatment for mild-to-moderate secondary hyperparathyroidism in patients undergoing haemodialysis. *Int J Hyperthermia* 2017;33:946-952
- Jiang T, Chen F, Zhou X, Hu Y, Zhao Q. Percutaneous ultrasound-guided laser ablation with contrast-enhanced ultrasonography for hyperfunctioning parathyroid adenoma: a preliminary case series. *Int J Endocrinol* 2015;2015:673604
- Andrioli M, Riganti F, Pacella CM, Valcavi R. Long-term effectiveness of ultrasound-guided laser ablation of hyperfunctioning parathyroid adenomas: present and future perspectives. *AJR Am J Roentgenol* 2012;199:1164-1168
- Li X, An C, Yu M, Peng L. US-guided microwave ablation for secondary hyperparathyroidism in patients after renal transplantation: a pilot study. *Int J Hyperthermia* 2019;36:322-327
- Jiang B, Wang X, Yao Z, Wu H, Xiao L, Gong H, et al.

- Microwave ablation vs. parathyroidectomy for secondary hyperparathyroidism in maintenance hemodialysis patients. *Hemodial Int* 2019;23:247-253
27. Peng C, Zhang Z, Liu J, Chen H, Tu X, Hu R, et al. Efficacy and safety of ultrasound-guided radiofrequency ablation of hyperplastic parathyroid gland for secondary hyperparathyroidism associated with chronic kidney disease. *Head Neck* 2017;39:564-571
 28. Ippolito G, Palazzo FF, Sebag F, Sierra M, De Micco C, Henry JF. A single-institution 25-year review of true parathyroid cysts. *Langenbecks Arch Surg* 2006;391:13-18
 29. Kodama T, Obara T, Fujimoto Y, Ito Y, Yashiro T, Hirayama A. Eleven cases of nonfunctioning parathyroid cyst--significance of needle aspiration in diagnosis and management. *Endocrinol Jpn* 1987;34:769-777
 30. Prinz RA, Peters JR, Kane JM, Wood J. Needle aspiration of nonfunctioning parathyroid cysts. *Am Surg* 1990;56:420-422
 31. Shi B, Guo H, Tang N. Treatment of parathyroid cysts with fine-needle aspiration. *Ann Intern Med* 1999;131:797-798
 32. Ha EJ, Baek JH, Lee JH. Ultrasonography-based thyroidal and perithyroidal anatomy and its clinical significance. *Korean J Radiol* 2015;16:749-766
 33. Xiaoyin T, Ping L, Dan C, Min D, Jiachang C, Tao W, et al. Risk assessment and hydrodissection technique for radiofrequency ablation of thyroid benign nodules. *J Cancer* 2018;9:3058-3066
 34. Park HS, Baek JH, Park AW, Chung SR, Choi YJ, Lee JH. Thyroid radiofrequency ablation: updates on innovative devices and techniques. *Korean J Radiol* 2017;18:615-623