

We are IntechOpen, the world's leading publisher of Open Access books Built by scientists, for scientists

4,900

Open access books available

124,000

International authors and editors

140M

Downloads

Our authors are among the

154

Countries delivered to

TOP 1%

most cited scientists

12.2%

Contributors from top 500 universities



WEB OF SCIENCE™

Selection of our books indexed in the Book Citation Index
in Web of Science™ Core Collection (BKCI)

Interested in publishing with us?
Contact book.department@intechopen.com

Numbers displayed above are based on latest data collected.

For more information visit www.intechopen.com



Bone Biology for Implant Dentistry in Atrophic Alveolar Ridge - Theory and Practice

Jeong Keun Lee
Ajou University School of Medicine
Republic of Korea

1. Introduction

It's a common experience for dental clinicians to note that the edentulous alveolar ridges always become atrophic as time goes by. It was late in the 19th century that Doctor Wolff first mentioned that form follows function (Wolf, 1892, as cited in Bilezikian et al., 2002). He described the individual capacity of morphological adaptation to a specific function as an "ontological adaptation" against the gravity through a daily locomotion or other daily mechanical duties (Fig.1-a). As a dentist I may illustrate the "dental compensation" in an Angle's class III malocclusion as a morphological adaptation to a masticatory function (Fig. 1-b), which itself is an example of the Wolff's "ontological adaptation."

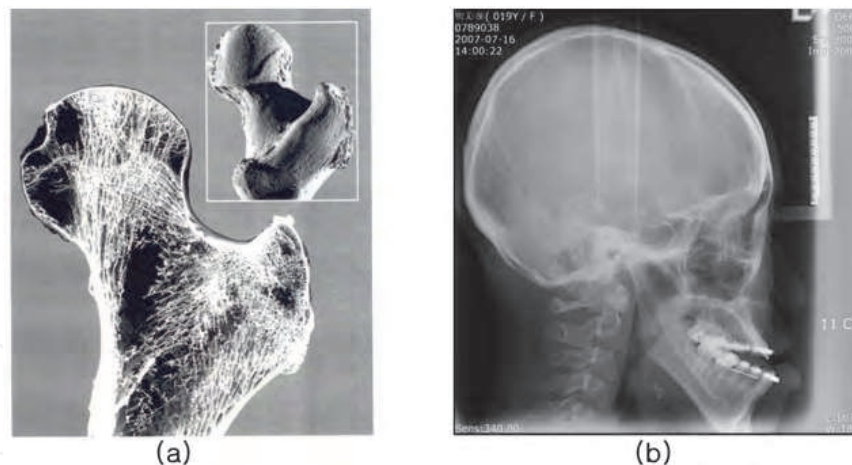


Fig. 1. Form as determined by function.

(a) As an orthopaedic surgeon, Dr. Wolff mentioned ontological adaptation on observing the morphological adaptation against gravity. The trabecular pattern of the trochanter reflects the functional loading against gravity through a daily locomotion or other daily mechanical duties.

(b) As dentists, we may exemplify the dental compensation as Dr. Wolff's ontological adaptation. Upper incisors are labially tipped in accordance to everyday masticatory function.

There's a tendency for Angle's class II patients to have new symptoms of temporomandibular disorder (TMD) after orthognathic surgery. In contrast, there's no definite relationship of Angle's class III patients to postoperative development of TMD. It was deduced that altered biomechanical situation after orthognathic surgery was the

causative factor for the new TMD symptoms in Angle's class II patients after orthognathic surgery (De Clercq et al., 1995). De Clercq compared the trabecular bone pattern of the Angle's class II and III patients to show that those of the former usually have less compact trabecular pattern than those of the latter. He conceived that this natural sparse trabecular pattern of the Angle's class II patients was brought about by the less functional loading subject to the mandibular condyle during mastication. And it was the increased masticatory stress after changed biomechanical circumstances that, in his opinion, was related to the newly-developed TMD after orthognathic surgery. It's a good example of the observation that "form follows function."

The author intended this chapter into two parts; the matter of why in the basic aspect and the matter of what to do for the clinician's perspective. First I will address the matter of why. Why does the unloaded bone go atrophic? Not exactly can we answer this question yet but current opinion pertaining to this problem will not only encourage current clinical treatment such as the principle of orthodontic tooth movement, but also implicate the future development of treatment outcome such as the complete regeneration of the alveolar bone loss of the periodontal pathologic origin. Next part will be on clinical aspect to assist in improving the implant site. Current treatment rationale, principles, and techniques for site improvement will be discussed with emphasis on autogenous bone graft using bone blocks. Additionally I will address the treatment strategy for the edentulous maxillary posterior alveolar ridge which is of main concern to many dental practitioners planning implant treatment in this troublesome region.

2. Why does the unloaded bone go atrophic?

2.1 Mechanotransduction

Solutions to the problem of atrophic alveolar bone begin with understanding why unloaded bone goes atrophic. Nobody can exactly depict why alveolar ridge goes atrophic after extraction of teeth. Efforts have been made to elucidate the scientific basis for the observation that the integrity of the skeletal tissue has something to do with mechanical usage. Frost has evolved the concept of the mechanostat (Frost, 1996) which he himself proposed as a new paradigm of understanding the mechanical-usage-dedicated message traffic routes between the skeletal tissue and the circumstances in which it is tuned. He argued the mechano-biologic negative feedback mechanisms would adjust skeletal architecture under the control of a subject's mechanical usage (Fig. 2).

Nowadays the secret of skeletal adaptation is more and more unveiling since around the opening of the 21st century. Doctor Burger hypothesized mechanotransduction as a main cause of the skeletal adaptation to a given functional loads (Burger & Klein-Nulend, 1999). She suggested that strain-derived fluid flow transduces the strain information to stimulate bone metabolism as a cellular response to a given load by the annular porosity produced by the osteocytes and their lacuno-canalicular hollow (Fig. 3). Osteocyte, the most abundant cell in our skeletal tissue was at first known as just a terminal stage cell of the osteoblastic lineage. But evidences are accumulating concerning its role as orchestrating skeletal adaptation to given functional loads. Orchestration of the cellular function is presumed earlier to be performed by the osteocytic syncytium through gap junctions (Moss, 1997). Evolving technology of current molecular biology has revealed many aspects of scientific evidences for this sophisticated orchestration of the skeletal tissue.

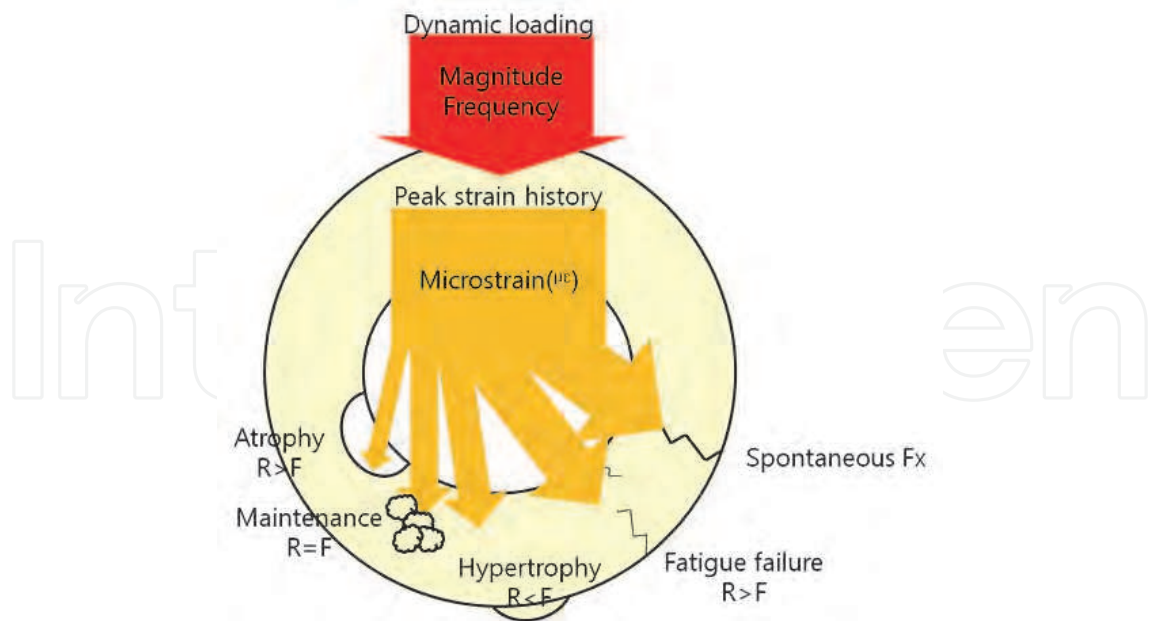


Fig. 2. The concept of the mechanostat.

Mechanostat hypothesis by Frost is schematically presented. Skeletal tissue has its loading history by dynamic loading which is remembered as a microstrain.

- (1) If the strain is too small value, resorption dominates formation of bone tissue and the bone goes atrophic.
- (2) If the strain is adequate, resorption balances formation and the bone maintains its volume.
- (3) If the strain is adequately high value, formation at last dominates resorption and the bone goes hypertrophic.
- (4) If the strain value is high by the overloading outreaching the range of physiological limitation, the strain is accumulated in the bone tissue causing microdamage leading to fatigue failure.
- (5) Finally, if the strain value over the limit of yield strength the bone goes spontaneous fracture.

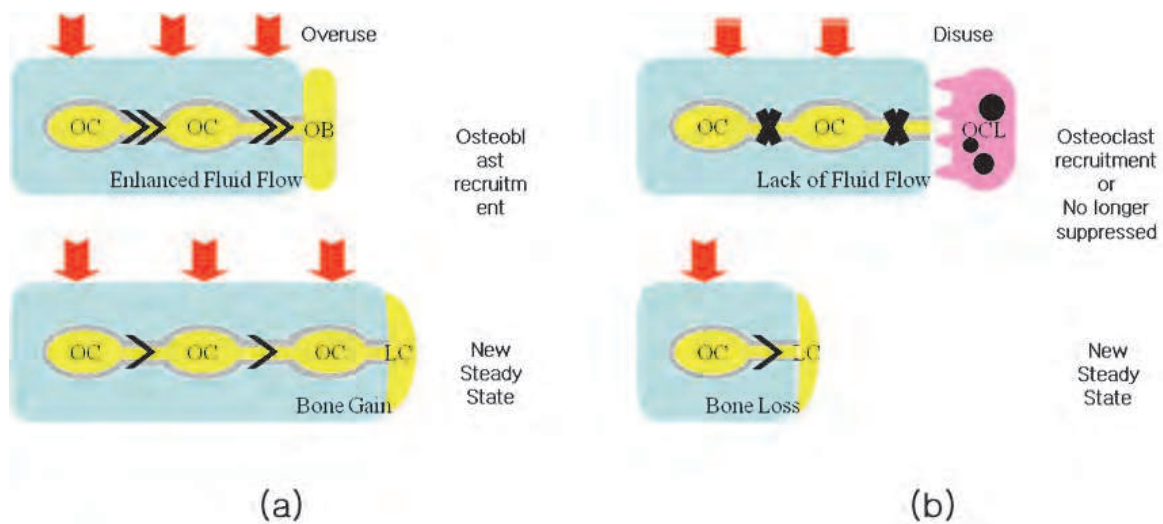


Fig. 3. Schematic diagram of mechanotransduction.

Mechanical information indicating the change of the external loading (red block arrows) is transduced by the strain-derived fluid flow (thin black arrowheads) to deliver biological information for the surrounding osteocytes to initiate bone metabolism for either (a) bone gain (overuse hypertrophy), or (b) bone loss (disuse atrophy). OC, osteocyte; OB, osteoblast; LC, bone lining cell; OCL, osteoclast.

2.1.1 Gap junction

Gap junction is the connection of the 2 hemichannels of each neighbouring cells which permits nanomolecular exchange of these cells. Hemichannel, in other words connexon is composed of six connexins switching from closed to open state depending upon the external stimulation (Fig. 4-1). Fluid shear stress stimulates cell to increase the production of connexin, an amino acid sequence that has 4 transmembrane domains with its two terminals in the cytoplasm (Fig. 4-2). Freely floating on the lipid bilayer, the connexons are able to dock with hemichannels of adjacent cells forming gap junctions (Fig.4-3). Gap junction is known to be restrictively permissive to intercellular mediators such as nitric oxide, Ca^{2+} , and prostaglandin (PG) E_2 (Bakker et al., 2001; Jørgensen et al., 2003; Siller-Jackson et al., 2008) or secondary messenger such as cAMP, IP_3 or cADP ribose (Civitelli, 2008). Connexons can work even without coupling with apposing connexons letting the PG E_2 or ATP out of the cell in response to mechanical stimulation (Cherian et al., 2005). External mechanical stimulus is thought to increase the connexin production, which will promote exchange of the biochemical information through the formation of new gap junctions (Cheng et al., 2001).

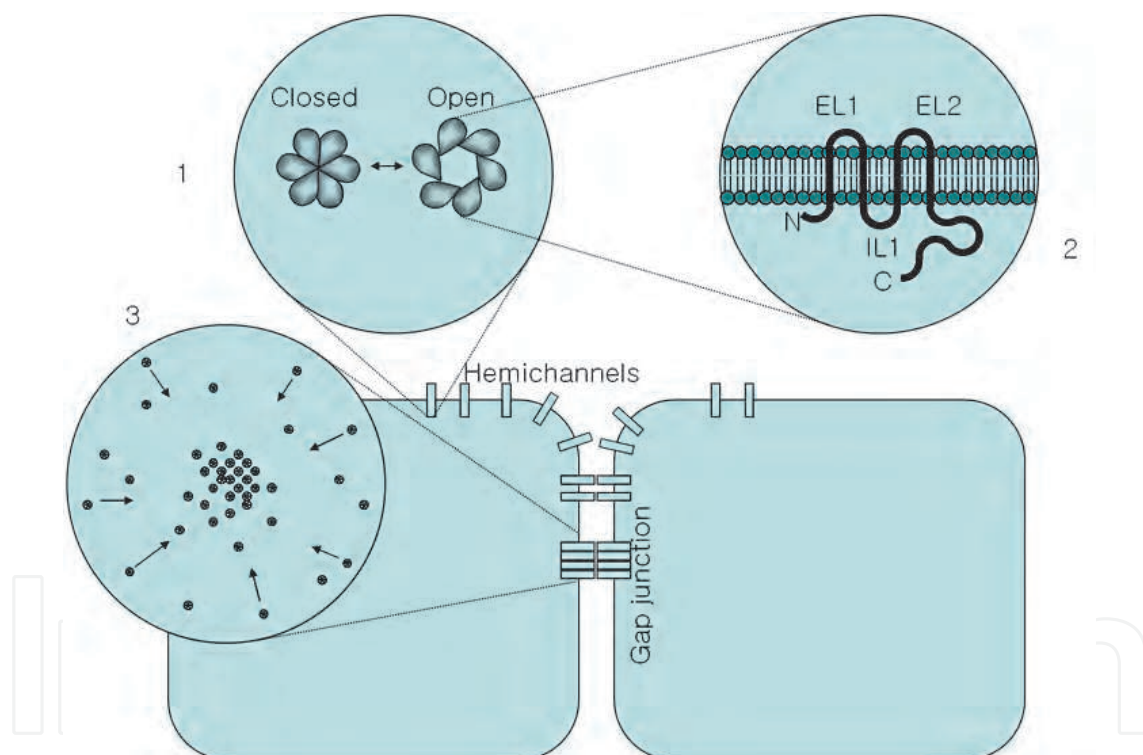


Fig. 4. Schematic diagram of the gap junction and hemichannel.

Hemichannels are selectively permissive pore of nanomolecular size staying free on the cell surface or docking with a hemichannel at sites of cell-cell contact to form a gap junction channel. Gap junction channels may cluster to form a gap junction plaque. 1: En face view of the hemichannels which are at a steady-state between two conformational states (open and closed). 2: Connexin topology at the plasma membrane. 3: En face view of a growing gap junction plaque.

2.1.2 Ionic mechanotransduction

The main mechanical stimulus which evokes mechanotransduction in bone cells is shear stress caused by the fluid flow. Stretch-activated channels open their gate in response to

external mechanical stimuli via this shear stress caused by fluid flow. The net results are increase of the intracellular concentration of the divalent ionic molecules such as calcium ion. These calcium ions are propagated to the neighbouring cells via the gap junctions, which is called slow intercellular calcium waves. On the other hand, intercellular calcium waves can occur by activation of purinergic receptors by extracellular nucleotides, resulting in fast intercellular calcium waves. Ionic mechanotransduction is through both of these mechanisms in human bone cells (Jørgensen et al., 2003). Activation of G-proteins also induces fluid-induced PG E₂ production in osteoblasts (Reich et al., 1997). As a kind of intercellular mediators of bone cells, PG E₂ mediates bone anabolic effect via prostaglandin receptor EP₄ (Machwate et al., 2001).

2.1.3 Mechanical mechanotransduction

Other than ionic mechanotransduction, hypothetical genomic control mechanism was postulated involving transmembrane protein integrins (Huang et al., 2004). Integrins are thought to form focal adhesions against the extracellular matrix to sense the external mechanical loading. Transduced mechanical signals are relayed to the nucleus mechanically via nuclear junctions. Thus genomic activity in response to external mechanical stimuli is postulated to encourage biochemical change in mechanical cellular devices, which is called mechanical mechanotransduction. Cell-cell junctions can also be mechanically involved to inform the signal to the neighbouring cells. But there is no direct evidence supporting this hypothesis until now.

2.1.4 Established model for cell mechanotransduction

Mechanical adaptation is one of the determining factors for regulating bone mass along with calcium and sex steroids (Harada and Rodan, 2003). Many efforts in the area of the molecular biologic cell study have revealed the details of mechanotransduction in all areas of the biological sciences. We now have a schematic depiction on mechanotransduction in cellular level (Jaalouk and Lammerding, 2009) although it is still lacking much (Fig 5). Up to now, mechanotransductive pathways are known to be activated via stretch-activated ion channels, G-protein coupled receptors, and transmembrane protein integrins which sense the shear stresses caused by the extracellular fluid flows. This mechanotransduction model is currently evolving according to cutting-edge knowledge lead by prominent molecular biological work.

2.2 Dynamic alveolar bone

Bone is a dynamic tissue as a kind of supporting structure for our body. Systemically controlled under the influence of calcium and phosphate metabolism, it is under tight control of local physical influence sensitive to surrounding mechanical conditions (Harada & Rodan, 2003). Alveolar bone, the most labile structure of the 4 periodontium, is more active in bone metabolism as much as 10 times that of the long bones, which makes the alveolar bone more sensitive to external mechanical stimuli.

Bisphosphonate is one of the anti-osteoporotic drugs on worldwide sales nowadays. One of the most widely used bisphosphonate is Fosamax and a newer drug, Fosamax Plus D, which had worldwide sales of more than \$23.8 billion from 1999 to 2009, according to IMS Health, a health information company that tracks drug sales (Singer, 2010). Since the first report (Marx, 2003), bisphosphonate-related osteonecrosis of the jaw (BRONJ) has been a matter of

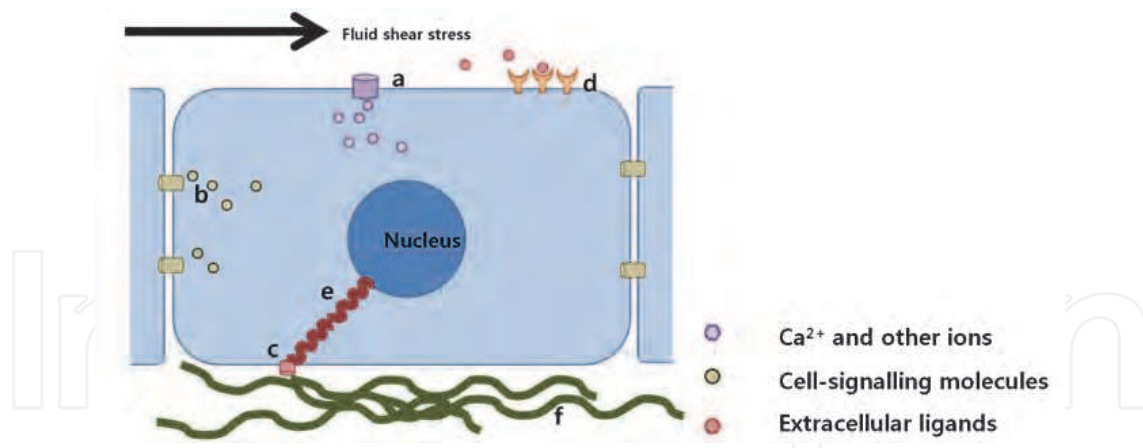


Fig. 5. Schematic depiction of mechanotransduction

a. Stretch-activated ion channels in the plasma membrane. b. Gap junctions for nanomolecular exchanges. c. Extracellular matrix (ECM)-cell focal adhesions to probe their environments. d. Cell surface receptors for autocrine and paracrine signalling molecules which are altered by compression of the intercellular space. Additionally, changes in G-protein-coupled receptors, lipid fluidity and even mitochondrial activity have been proposed as mechanosensors. e. The nucleus itself as proposed to be a mechanosensor. f. Mechanotransductive signalling outside the cell as given by force-induced unfolding of ECM proteins, such as fibronectin.

debate. Its pathogenesis is also still obscure but there is some clue. Osteonecrosis of the jawbone is caused not only by bisphosphonate but also by Denosumab, a monoclonal antibody to osteoclastogenetic factor, RANKL (Aghaloo et al., 2010; Taylor, et al., 2010). Upon this observation, pathogenesis of BRONJ is presumed to be delayed bone turnover resulting from osteoclastic inactivation. The jawbone is the only bone to be necrotised among the whole skeletal system that is complicated by the anti-osteoporotic bisphosphonate drugs, which is known as a BRONJ. Detailed information on BRONJ will be addressed elsewhere in this book.

2.3 Bone remodelling and sclerostin

Sensitive bone reaction is performed by the bone remodelling procedure encompassing bone resorption by osteoclast and bone redeposition by osteoblast. Microdamage to the bone tissue accumulates by mechanical overloading, and causes osteoclastic resorption of the damaged bone tissue. After osteoblastic transition which is marked by switching from bone resorption to formation, functional bone adaptation to a given loading is completed. One of the most dramatic advances in the study of the osteocyte is its orchestrating function on the bone remodelling procedure, the key protein of which is the recently discovered sclerostin. Sclerostin is a gene product of the SOST and secreted by the osteocytes into the extracellular matrix reaching a steady concentration gradient. As a functioning glycoprotein it inhibits the osteoblast development and bone formation via Wnt signalling pathway (van Bezooijen et al., 2007). Adequate concentration gradient of the sclerostin enables the maintenance of the normal bone mass responding to a given functional loading. Adequate mechanical stimulation increases bone mass via a downregulation of the osteocytic production of the sclerostin. Irritable overloading affords the osteocytes focal microdamage, which renders reduced concentration of the sclerostin around the focal damage site. Soon the recruitment of the osteoclastic lineage cells is commenced to resorb the focal site, followed by the influx of osteoblastic precursor cells to build a new bone tissue. Generally bone remodelling is accomplished according to the change of local mechanical stress.

3. What can I do for atrophic bone to be prepared for dental implant?

3.1 Characteristics of the bone tissue

Bone is a distinctive tissue in that it undergoes regeneration rather than a repair procedure in the healing process after surgical trauma. The result is that it is always replaced by the same parenchymal structure, i.e. bone, and not by the scar tissue formation. The most important aspect for the adequate regeneration process is the close contact and rigid fixation of the graft bone to the recipient bed. We will discuss the aspect of wound healing of the skeletal tissue in the implications from the fracture healing (See 3.3)

Developmentally there are two types of bone formation, intramembranous and intracartilagenous ossification, with the resultant two types of bone tissues, membranous and endochondral bone, respectively. Cranial bone underwent progressive evolutionary adaptation to be composed of neurocranium and viscerocranium (Park, 2005). The combination of these two classification systems yield four types of cranial bone; membranous neurocranium, cartilaginous neurocranium, membranous viscerocranium, cartilaginous viscerocranium (MacKinnon & Morris, 1990) (Fig. 6). Alveolar bone belongs to membranous viscerocranium and has different developmental origin from iliac bone which belongs to endochondral bone. It is my clinical experience that donor bone block from the mandibular ramus is rather hard and difficult to manage in drilling and fixating with screws on the recipient bone bed in alveolar bone reconstruction. But the clinical result after bone graft is fairly good without so much resorption. Contrast to it, iliac bone block relatively offers little difficulty in surgical manipulation with some degree of bone resorption after alveolar bone reconstruction procedure.

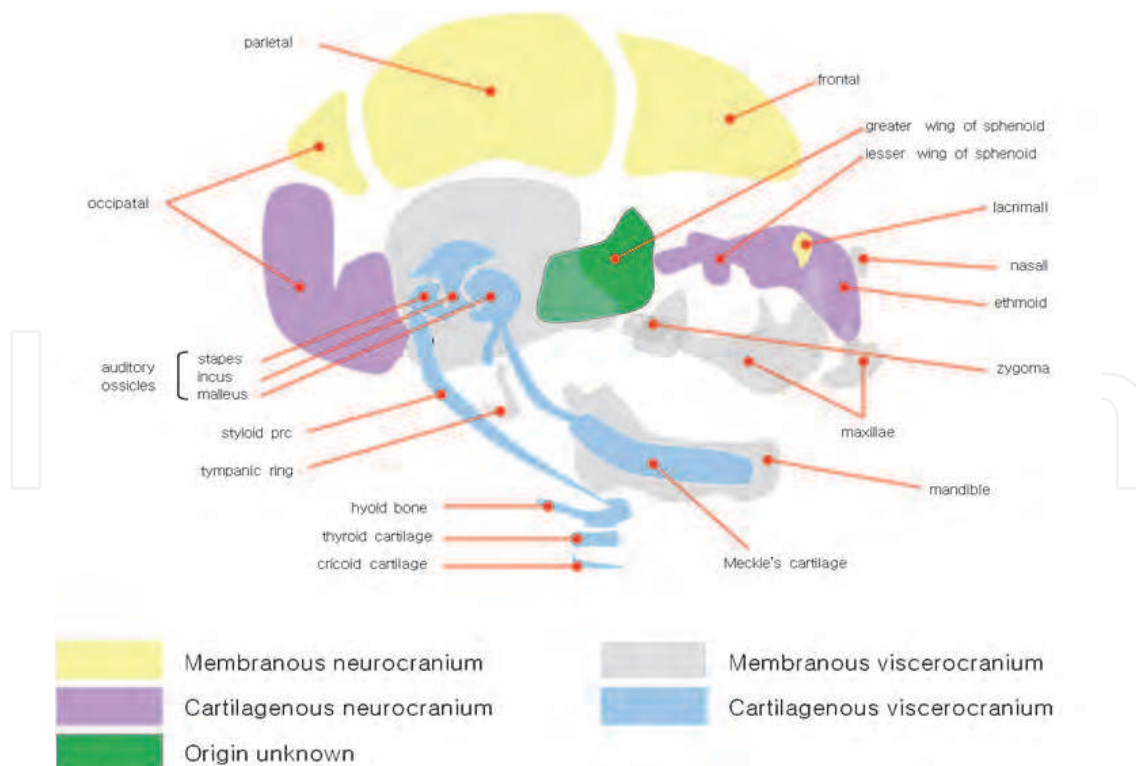


Fig. 6. Head and neck bone tissue.

Cranial bone is classified into four types; membranous neurocranium, cartilaginous neurocranium, membranous viscerocranium, cartilaginous viscerocranium.

3.2 What is going on in there?

Contrasted to the previous issue, an atrophic alveolar bone which is a matter of why, selection of the bone augmentation method is a matter of choice. Adequate selection of the graft material is based upon correct understanding of the biology pertaining to bone graft. Regeneration after bone graft is well studied in autogenous bone graft, which is the gold standard of the bone grafting procedures. Free-graft bone must be replaced with new bone of the recipient site origin, which is called osteoconduction. It functions as a scaffold for osteoprogenitor cells to reside in, and adequate remodelling process is essential because timely activation of osteoclastic function must be preceded before full blown osteoblastic cells begin to build new bone tissue. In addition to osteoconduction, osteoinduction is also an important mechanism of autogenous bone graft repair. Bone morphogenetic protein (BMP) is a potent skeletal mesodermal inducer, which blocks all the other pathways from mesenchymal stem cell but to the osteoblastic commitment. Bone formation can also be accomplished by the bone cell of donor origin, which is called osteogenesis. This is the predominant mechanism for new bone growth in vascularised bone grafts.

3.3 Implications from the fracture healing

Management principle of the bony injuries is close contact of the fractured segments and undisturbed healing without movement or infection (Lavery, 1994). So the most important aspect of the fracture healing is firm immobilization after adequate reduction and the same rule applies to bone graft.

3.3.1 Direct healing

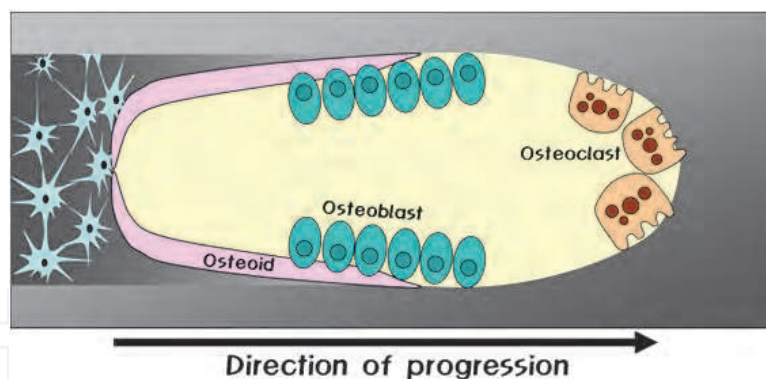


Fig. 7. Schematic diagram of basic multicellular unit (BMU).

Histologically the BMU consists of 1) osteoclastic front or osteogenic front, 2) reversal phase mononucleocytes, 3) osteoblastic layer. It is observed in the Haversian system of the cortical bone which is under the physiological loading such as the masticatory function. The osteoblasts are exclusively intrasosseous Haversian system osteoblasts reacting to the load.

3.3.1.1 Contact healing

Contact healing occurs when the fracture segments are held firm within the interfragmental distance of 100 μm (Shapiro, 2008). Histologically it is mediated mainly by the intrasosseous Haversian system osteoblasts (Fig. 7). Bone repair occurs bridging the minimal gap with osteoprogenitor cells crossing in the same direction of the Haversian system. It seems like that the osteoclastic front feels no barrier on its way across the gap. (Fig. 8).

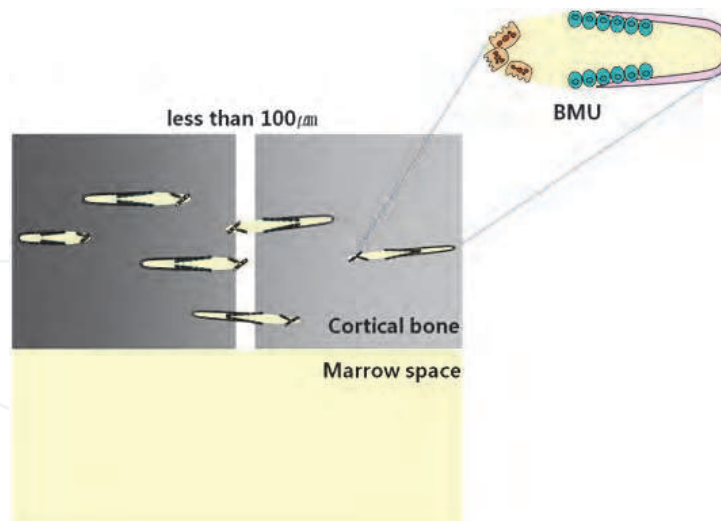


Fig. 8. Schematic diagram of the contact healing.

When the fracture segments are held firm within the interfragmental distance of $100\ \mu\text{m}$, the shape of the osteons in the cortical bone does not change when crossing the fracture or osteotomy. The direction of the lamellar bone is parallel to the long axis of the bone from osteoprogenitor cells in the Haversian longitudinal vessels.

3.3.1.2 Gap healing

If the fracture is reduced and rigidly fixated but the gap is over $100\ \mu\text{m}$, it goes gap healing procedure. Reduced segments are stable but the distance is too far for the Haversian longitudinal osteogenic front to cross. New bone begins to form in the marrow laid to the pre-existing rim of lamellar cortical bone at right angles to the long axis of the bone. After the gap is filled with this mechanism, the osteogenic fronts of the original pre-existing fracture segments find their ways to cross the filled gap (Fig 9).

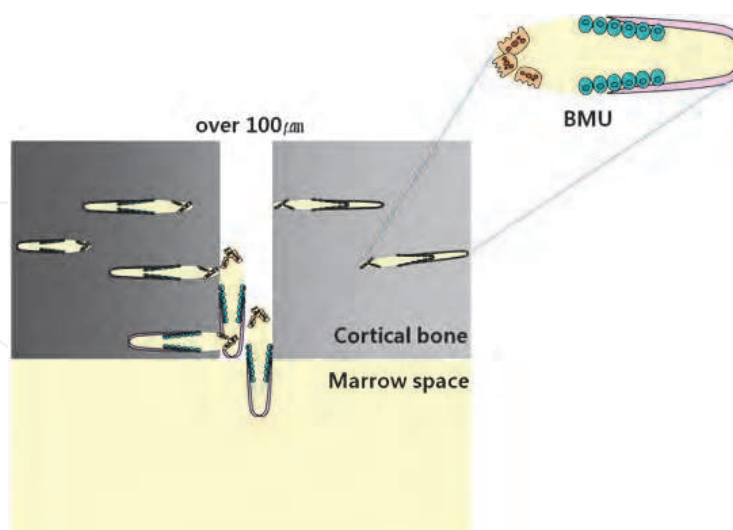


Fig. 9. Schematic diagram of the gap healing.

When the interfragmental distance is over $100\ \mu\text{m}$ under the stable rigid fixation, gap healing commences. Osteoprogenitor cells from Haversian longitudinal vessels cannot cross the gap anymore, and instead those of bone marrow origin will creep on the segmental surfaces to fill the gap at right angles to the long axis of the bone. At last osteoclastic cutting cone from the original cortex begins to cross the filled gap to realign the lamellar bone parallel to the longitudinal axis.

3.3.2 Indirect healing

Failed anatomic repositioning or mobility across the fracture gap gives rise to indirect healing. Indirect healing occurs by callus formation followed by cartilage formation. Initial hematoma under hypoxic circumstances is gradually replaced by the granulation tissue, which in turn forms a fibrocartilagenous callus in the condition of hydrostatic pressure. With minimal strength but having the tolerance to the deforming forces in the interfracture zone, granulation tissue helps attenuate interfracture movement. Decreased interfracture movement in turn aids laydown of the fibrous tissue. Stabilised bone segments further permits fibrocartilagenous callus to form. Bridging the gap across the fracture segments the callus shades into the bone tissue.

The type of force healing bone experiences determines the tissue type the healing bone will be. It's a general agreement that the tensile force favours intramembranous ossification, while compressive stress encourages the pluripotent mesenchymal cells into chondrocytes. Continuous hydrostatic compression incurs cartilage formation whereas intermittent compressive stress gives intracartilagenous ossification (Carter et al., 1998).

3.4 Healing process after bone graft

3.4.1 Initial phase

At the beginning of the bone graft healing, cells with bone forming potential must be recruited to the graft site to construct a new bone tissue. This is done in two weeks after bone graft, which is called the initial phase. It is the most important period although there is no actual bone formation because the osteoblast can lay down mineralized tissue only in their adjacent area.

3.4.2 Phase 1 bone regeneration

Actual mineralization ensues following 4 weeks in which period new bone is formed as a woven bone type. There is no orientation of bone trabeculae irrespective of surrounding mechanical stress. Designated as a phase 1 bone regeneration, it is finished by 6 weeks after the bone grafting, followed by mechanical stress-sensitive period, phase 2 bone regeneration.

3.4.3 Phase 2 bone regeneration

It reaches a peak around 3 to 4 months after bone grafting when bone remodelling occurs in accordance with the mechanical demand. Functional loading guides the existing woven bone into a lamellar type of new bone which is suitable for supporting the mechanical stress within a functional range.

Bone remodelling differs from bone modelling seen in skeletal growth period, in which the bone resorption and formation are accomplished independently in concert with bone growth. On the contrary, the osteoclastic and osteoblastic effects are coupled tightly in bone remodelling which is well demonstrated histologically in the temporary anatomical structure, basic multicellular unit (BMU) (Frost, 1963, as cited in Robling et al., 2006)(Fig. 7). The time with which the BMU travels through tissue space is called sigma (σ). In human cortical bone, it would take approximately 120 days to complete one σ , consisting of roughly 3weeks of osteoclastic phase, 10days of reversal phase, and 3months of osteoblastic phase (Robling et al., 2006).

3.5 Autogenous block bone graft in alveolar defect of height and/or width problems

Edentulous alveolar ridges must be prepared for dental implant treatment. Autogenous bone block can be harvested from diverse sites (Fig. 10) which have their own advantages and disadvantages. Small defects such as those caused by periodontitis can be prepared using small bone blocks from intraoral donor origin. Two intraoral sites are outstanding; the external oblique ridge-ramal area of mandible, and the chin cortex. Of these, I prefer an external oblique ridge-ramal bone, for approaching to chin bone possibly risks the incisive branches of the mental nerve, which is very annoying. Large defects over the basal bone as a result of radical resection of the large head and neck tumours or major trauma can be rehabilitated with reconstructive surgery with extraoral large donor bone block such as iliac bone or fibula. I prefer iliac free bone graft but free vascularised osteocutaneous fibular graft can also be of use.

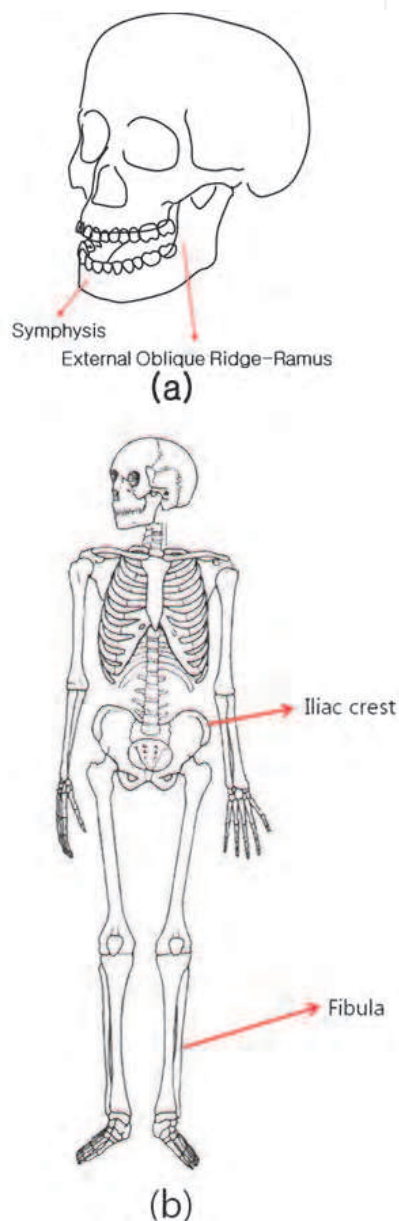


Fig. 10. Favoured donor sites for autogenous alveolar bone reconstruction with bone block. Many parts can be donor site for autogenous alveolar bone reconstruction but the author favours these arrow-indicated sites; (a) intraoral, and (b) extraoral donor sites.

3.5.1 Reconstruction with external oblique ridge-ramal bone block

Fifty six years old female patient resorted to our clinic with the chief complaint of lost anterior upper teeth. Her problem was not only the lost dentition, but also the lost alveolar ridge revealed as in Fig. 11-a. External oblique ridge-ramal area of the mandible was selected as a donor site and harvested for augmentation of the depressed alveolar bone as in Fig. 11-b. Harvested bone was placed and secured in the recipient site as in a Fig. 11-c and waited 4 months for dental implant fixture installation. Immediate before fixture installation we evaluated the bone graft area with CT scan, which revealed good integration of the graft (Fig. 11-d).

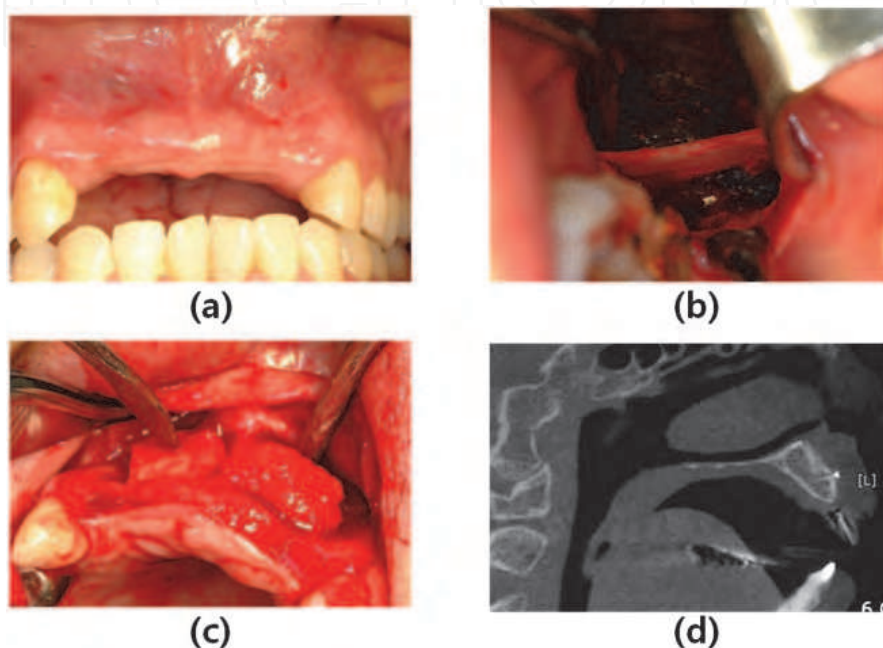


Fig. 11. Alveolar bone augmentation with ramal bone block.

(a) Preoperative figure shows depressed anterior maxillary wall due to lost alveolar bone accompanying loss of maxillary anterior 4 teeth.

(b) As an augmentation source for donor bone, both external oblique ridge-ramal area of the mandible were approached and 2 pieces of bone blocks were harvested.

(c) Harvested bones were well adapted in the depressed recipient area which were fixated with adequate miniscrews.

(d) Graft area was evaluated with CT scan four months after the graft procedure, which showed adequate healing ready for installation of the dental implant fixtures. One of miniscrews was evident on this CT slice.

After instillation of local anesthetics with 2% lidocaine and 1:100,000 epinephrine, previously augmented site was approached, which showed acceptable augmentation as in Fig. 11-e. Fixation screws were retrieved before dental implant fixtures were installed as in Fig. 11-f, and zirconia abutments were used because the aesthetic consideration was important in maxillary anterior region (Fig. 11-g). Clinical appearance after the completion of final prosthesis was good as in Fig. 11-h although slight loss of interdental papilla was observed.

3.5.2 Reconstruction with chin bone block

This 56 years old male patient was diagnosed as total maxillary insufficiency precipitated by long duration of periodontal diseases (Fig.12-a). Implant was planned for implant-

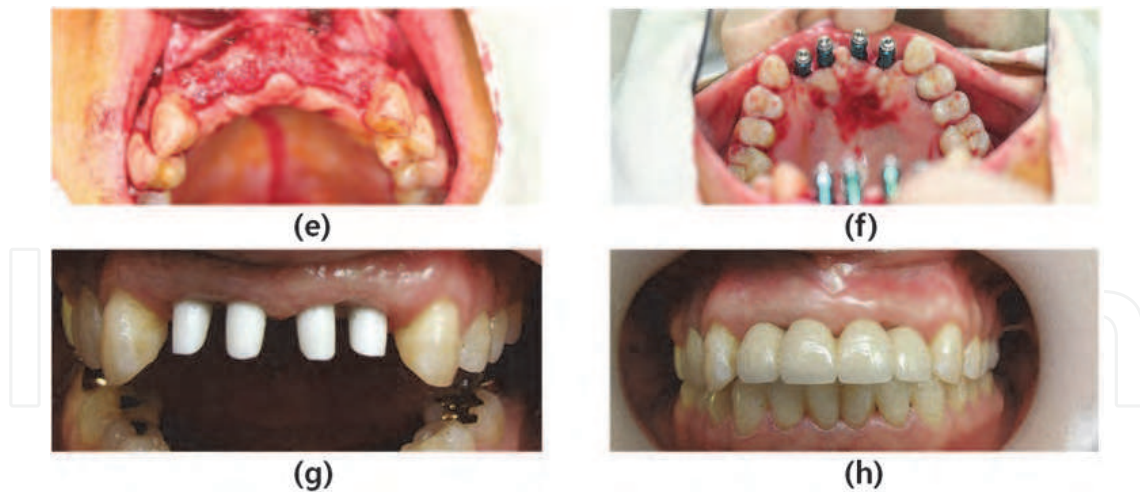

Fig. 11. (continued). Alveolar bone augmentation with ramal bone block.

- (e) Maxillary anterior area of the same patient was re-entered 4 months later to find acceptable appearance of the graft site for implant fixture installation.
- (f) Fixtures were installed after retrieval of the fixation screws.
- (g) Zirconia abutment was selected for cosmetic consideration.
- (h) Minimal aesthetic problem was detected after final prosthodontic rehabilitation.

supported overdenture and total height- and width problem was identified (Fig. 12-b). Ideally iliac bone graft was recommended but the patient refused general anesthesia and finally multiple event of minor augmentation procedure under local anesthesia was accepted as an alternative method. Insufficient alveolar bone was recovered with bilateral sinus graft and lateral wall augmentation along with anterior subapical block bone augmentation. Fig. 12-c shows insufficient anterior maxillary wall inadequate for dental implantation. Both mandibular ramal bone blocks were utilised as the donor for both lateral maxillary wall augmentation, and still we need another bone block for anterior maxillary alveolar ridge. In spite of the possible numbness after donor bone harvesting, chin bone was unavoidable choice (Fig. 12-d). Along with autogenous bone block, allogenic bone powder was accepted for filling the gap between the graft and recipient bed (Fig. 12-e). Fig. 12-f shows clinical picture after successful dental implantation 4 months after the bone graft.

3.5.3 Reconstruction with free iliac bone block

Initial diagnostic panoramic view of forty nine years old male with severe chronic periodontitis showed many hopeless teeth on maxillary anterior and right posterior areas (Fig. 13-a). After scheduled periodontal treatment with extraction of many hopeless teeth diagnostic CT scan revealed compromised areas of the maxillae on the anterior (Fig. 13-b) and right posterior region (Fig. 13-c).

Free iliac bone graft was done under general anesthesia, in which operation inner medial cortical bone was harvested with cancellous bone and marrows leaving the outer cortical bone intact (Fig. 13-d). Maxillary alveolar bone was augmented with harvested cortical block for future dental implant treatment (Fig. 13-e). Prosthodontic treatment was done with excellent treatment outcome as in Fig. 13-f and g.

3.5.4 Microsurgical reconstruction with free vascularised fibular bone

Young man resorted to our clinic with the chief complaint of painless lower facial swelling and preoperative panoramic findings revealed multiple radiolucencies all around the mandible

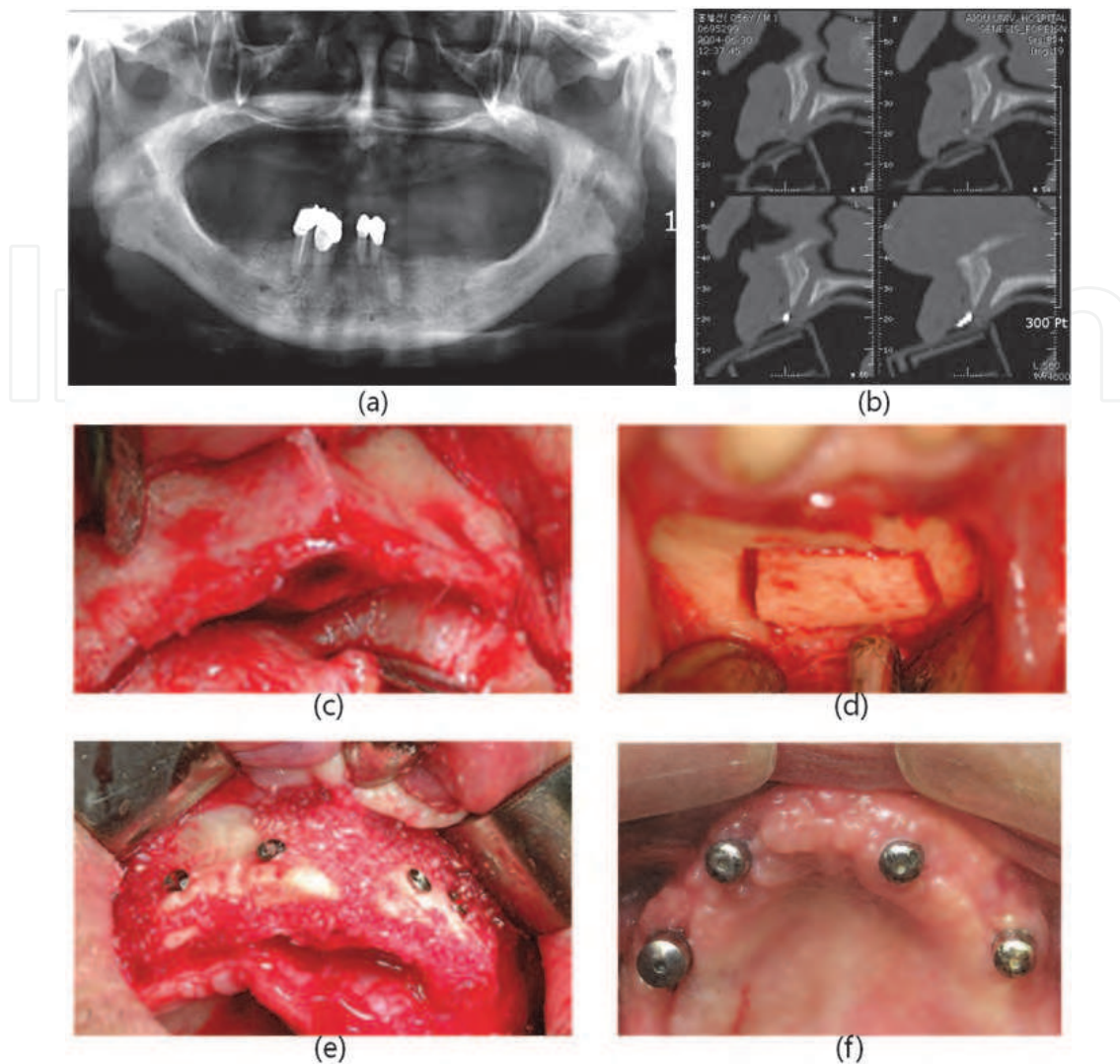


Fig. 12. Alveolar bone augmentation with chin bone block on anterior maxillary defect.

(a) General bone resorption is identified on preoperative panoramic view.

(b) Dentascan on anterior maxillary region revealed large space for nasopalatine neurovascular bundle and poor bone bed for dental implant.

(c) Reflection of the flap revealed thin alveolar process on the anterior maxillary edentulous area. Note large nasopalatine foramen hindering fixture installation on #11 and #21 site.

(d) Dense labial cortex of the chin bone was found after careful dissection, which was harvested for augmentation of the thin anterior maxillary alveolar process.

(e) Bone blocks from the chin cortex were fixated with miniscrews and the remaining gaps were filled with commercially available allogenic bone powder.

(f) Four fixtures were installed 4 months after the bone graft on the strategic sites.

(Fig. 14-a). Biopsy of the lesion confirmed the diagnosis of ameloblastoma and the mandible was extensively removed using segmental resection ranging total body area anterior to both antegonial notches. Mandibular reconstruction plate was utilised immediately as a bridging plate for the maintenance of the mandibular continuity. Six months later when no evidence of recurrence was confirmed, free vascularised fibular reconstruction was done with microsurgical technique utilising peroneal artery as a feeding artery (Fig. 14-b). Four months later when successful reconstruction was identified (Fig. 14-c), six fixtures were installed (Fig. 14-d), followed by hybrid type overdenture treatment (Fig. 14-e).

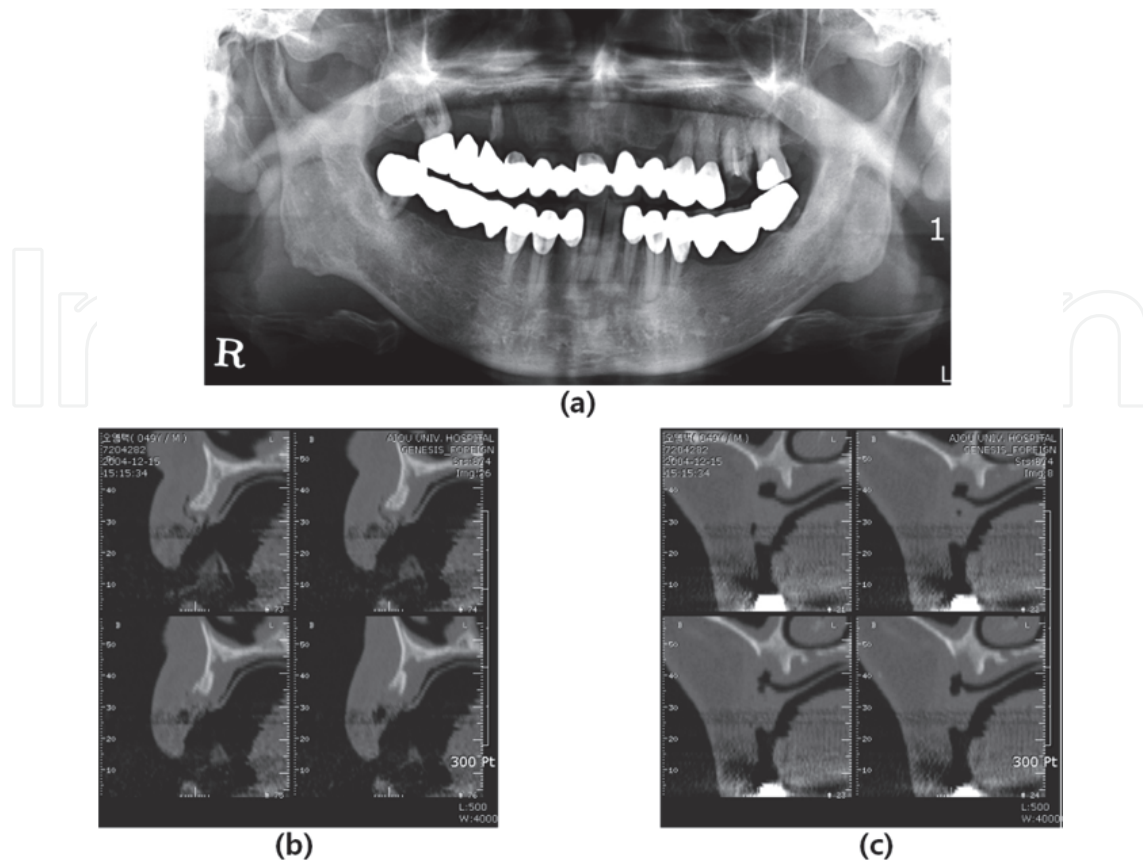


Fig. 13. Alveolar bone augmentation and additional maxillary basal bone reconstruction with free iliac bone block-Preoperative diagnostic imaging.

(a) Severe periodontal disease were evident in preoperative panoramic view in which all maxillary anterior teeth and maxillary right posterior teeth were scheduled to be extracted and periodontally treated with surgical intervention.

(b) Diagnostic CT scanning was inevitable after extraction of all poor teeth and scheduled periodontal surgery was finished, where width problem was evident in anterior maxillary region.

(c) CT also revealed both width and height problems in right maxillary region.

3.6 Treatment strategy for the edentulous maxillary posterior alveolar ridge

Dental implantation on the atrophic posterior maxillary alveolar ridge is always challenging because both quantity and quality of the bone are poor in this area. Maxillary posterior alveolus exhibits poor bone quality, for anatomically maxillae consists almost of cancellous bone and biomechanically posterior teeth are subject to three times more occlusal forces than anterior teeth. Usually the quality of the bone in this region is classified as D3 or D4 in Misch's classification which is composed of fine trabecular bone with thin cortical bone or even finer trabecular bone with almost no cortical bone (Misch, 1990, as cited in Misch, 2008). The amount of available alveolar bone is usually deficient because of the dual resorption inside and outside of the sinus floor, because of pneumatization and alveolar resorption, respectively. Frequently this area needs bone augmentation to allow an implant-supported prosthesis.

Alabama implant meeting held at Birmingham in 1976 was the first meeting that Tatum presented a surgical technique involving the maxillary sinus (Tatum, 1986). It was several years later that the first publication on this technique was reported by Boyne and James

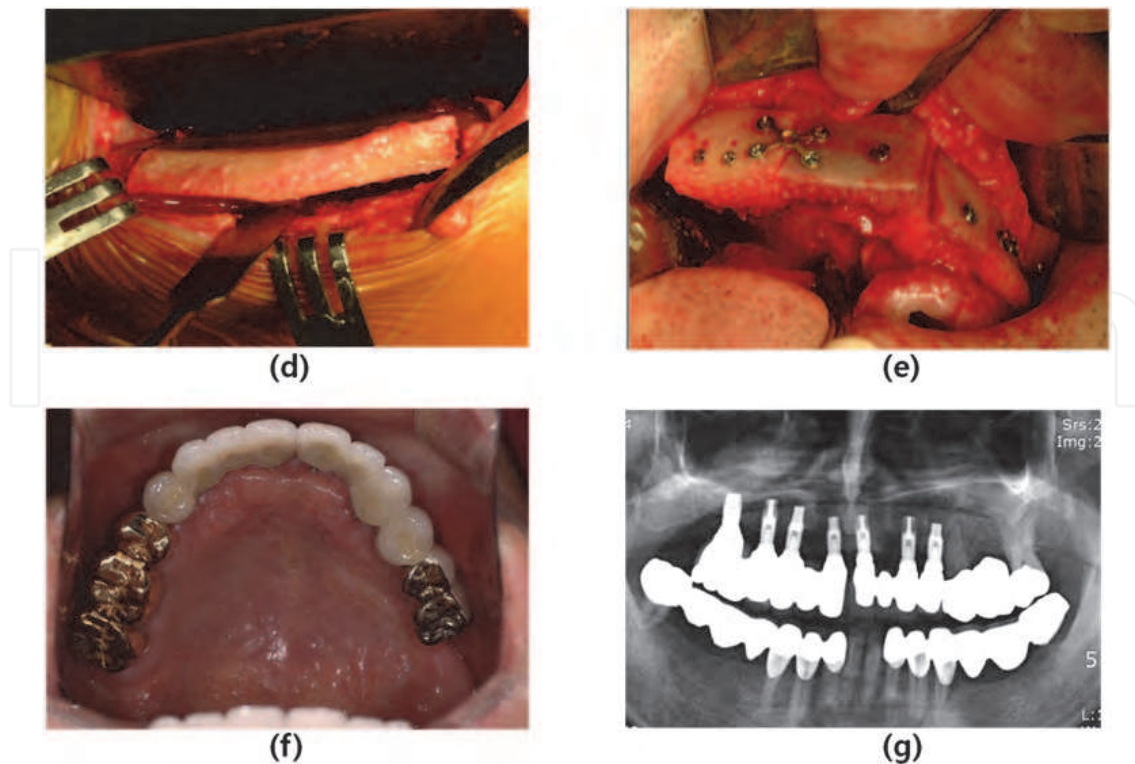


Fig. 13. (continued). Alveolar bone augmentation and additional maxillary basal bone reconstruction with free iliac bone block-Operative procedures and postoperative results. (d) Harvesting of the free iliac bone. Cancellous bone and marrows along with inner medial cortex were harvested leaving the outer cortical bone intact for reduction of postoperative complication. (e) Insufficient maxillary alveolar bone was augmented with the harvested iliac bone. (f) Complete prosthodontic rehabilitation was possible after dental implant fixture was osseointegrated to successfully augmented graft bone. (g) Panoramic view taken after the completion of the dental implant treatment.

(Boyne & James, 1980). They introduced infracture technique with upper hinge in the lateral wall of the maxilla. Consensus meeting on sinus surgery held in 1996 at Babson College, Willesley City, MA was remarkable in that it was the first meeting that reaches an agreement on terminology on the sinus surgery for dental implantation. Sinus augmentation is generally considered a good method for edentulous maxillary posterior alveolar bone to allow an implant-supported prosthesis. Some modifications are available involving hydraulic elevation of the sinus floor via crestal approach (Vitkov et al., 2006) or outfracture of the lateral maxillary window (Lee, 2010).

Evaluation of bone graft is based on the clinical evidence of fixture survival and functioning final prosthesis. However strict criteria for success are based upon the histological evidence of a microscopic activity conducted by vital bone tissue. It can be evidenced by bone remodelling, which means the viable osteoclast and osteoblast is available by the bone grafting procedures. It is therefore one of the criteria for bone graft materials to be incorporated in the bone remodelling procedure. The determinant factor for success of sinus bone graft however is known to be not related to the kind of a graft bone but to the remaining alveolar bone height. Actually many graft materials used in the sinus floor augmentation demonstrate an acceptable success rate irrespective of their nature. It is because that the sinus cavity is compartmentalised and has a natural housing for the graft materials to be stabilized, which is a specific anatomical advantage of the sinus cavity.

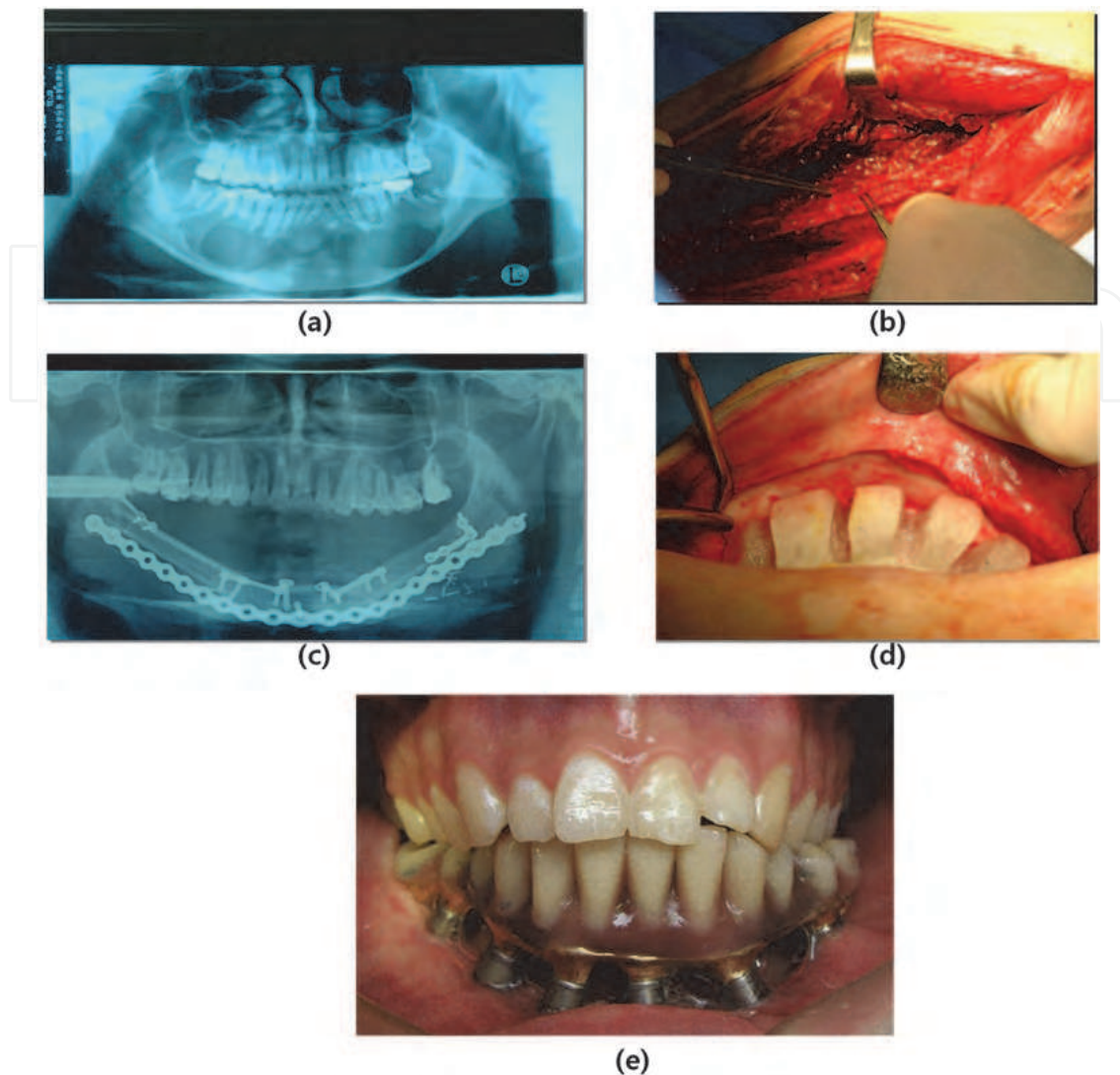


Fig. 14. Mandibular reconstruction utilising microvascular free fibular graft. Preoperative panoramic view showing multiple large radiolucencies all around the mandibular body area (a), which was segmentally resected for radical treatment diagnosed as multicystic ameloblastoma. Confirming no evidence of recurrence at 6 months later, patient's fibula was utilised as in (b) for reconstruction of the basal part of the mandibular body. Four months later when stable reconstruction was identified (c), dental implant fixtures were installed on strategic positions in the fibula as in (d). This fibula was only for the basal part of the mandible and the final denture was designed as a hybrid type as in (e) to facilitate the oral hygiene procedures.

3.6.1 Outfracture osteotomy sinus graft technique for posterior maxillary edentulous ridge concomitant with dental implantation.

The original method of Tatum first presented in the Alabama implant meeting (Tatum, 1986) adopted a trapdoor design which involved inward opening of the lateral bony window with a top hinge. It was a methodological revolution for it was a pushing back the frontiers of a prosthodontic treatment by surgical measure. But it has its own limitations in anatomical considerations in cases with a sinus septum or a thick lateral sinus wall in the operation field. These limitations were overcome by modifying window opening method from inward to outward direction. Outfracture osteotomy sinus graft technique was introduced utilising

readaptation of the outfractured bony window segment after sinus floor augmentation (Lee, 2010). It involves routine window opening on the lateral maxillary wall as in Fig. 15-a. Completion of the outfracture of the bony window segment (Fig. 15-b) is followed by the elevation of the Schneiderian membrane and floor augmentation using the space created by the membrane elevation (Fig. 15-c). Outfractured bony segment was placed back into the original position and secured without any screws or plates (Fig. 15-d). The success rate with the outfracture osteotomy sinus graft technique was reported as 97.2 % in 113 cases through August 2004 to July 2009 in Department of Dentistry, Ajou University Hospital (Song, 2009).

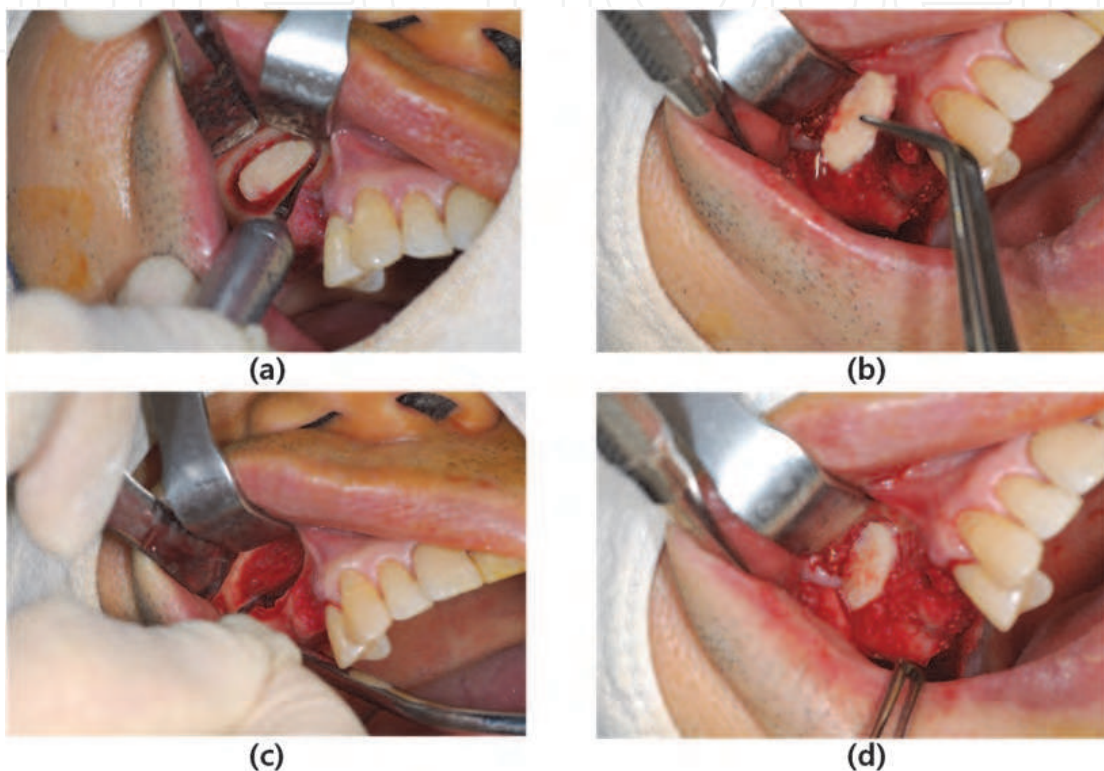


Fig. 15. Outfracture osteotomy sinus graft technique.

(a) Osteotomy of the lateral maxillary wall is done as routine.

(b) Outfractured bony window is shown, which is to be preserved in normal saline solution during Schneiderian membrane elevation.

(c) Schneiderian membrane is elevated via bony aperture created by the osteotomy.

(d) Repositioned bony segment is secured without a screw or plate.

Courtesy by Lee JK in *J Oral Maxillofac Surg* 68:1639-1641 (2010).

3.6.2 Dental implant treatment in severely compromised posterior maxillary edentulous ridges

Fifty nine years old female resorted to our clinic with a chief complaint of chewing difficulty owing to complete loss of teeth. Several years of ill-fitting denture was very annoying to her and doing without this ill-fitting denture inevitably caused her severe alveolar resorption. She agreed with mandibular removable denture but insisted on fixed type maxillary prosthesis. Prosthesis design for the mandible was an implant supported overdenture but maxillary alveolar bone must be augmented for dental implant treatment. Anterior maxillary wall was planed to be augmented with external oblique ridge-ramal bone block

from both sides of the mandible. Both maxillary sinuses were examined with dental CT showing that double resorption inner and outer sides of the sinus floor due to pneumatization and alveolar bone resorption, respectively (Fig. 16-a and b). The CT showed resultant minimal alveolar bone heights with maximum thickness of 2 mm in these areas. Maxillary sinus floor augmentation was done utilising outfracture osteotomy sinus graft technique (Fig. 16-c and d) on both sides. She was very satisfied with maxillary fixed-type prosthesis along with removable-type mandibular overdenture (Fig. 16-e). Radiographic finding after final prosthodontic treatment demonstrated excellent treatment results Fig. 16-f).

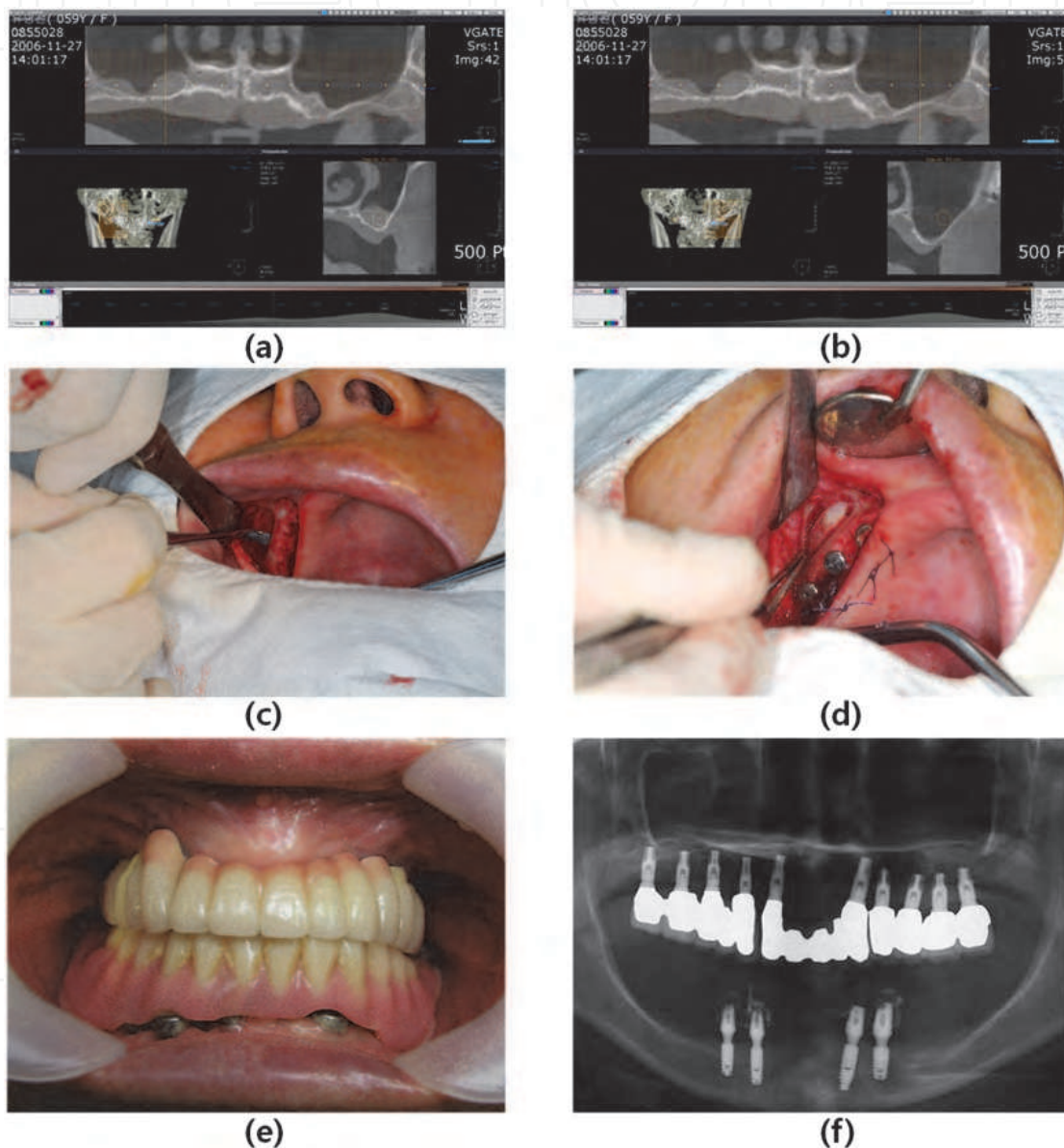


Fig. 16. Sinus graft and dental implant treatment with fixed type bridges.

Preoperative CT showed severe pneumatization and alveolar bone loss leaving only thin cortex of 2 mm thickness or less on both sides of the floor of the maxillary sinus (a and b). Sinus graft utilising outfracture osteotomy technique was done on right maxillary antrum (c and d). The same procedure was repeated on the contralateral sides later. Clinical photograph (e) and panoramic radiograph (f) of final prosthesis showed good function without any complication.

4. Conclusion

Treatment strategy for the dental implant-supported prosthesis in atrophic edentulous alveolar ridge is one of the most difficult tasks for dental clinicians. As a rule, autogenous bone is a gold standard of bone graft and has rated better treatment score than any other types of bone. Clinically available autogenous donor bone was exemplified by respective clinical cases with the theoretical background based upon the basic bone biology. In severe cases such as the defect involving not only an alveolar bone but also a basal part of the jaw bone, harvesting a donor bone was not a minor oral surgery anymore requiring microsurgical techniques under general anaesthesia. But the sinus floor augmentation was possible under local anaesthesia even in the severe cases with the remaining floor thickness only 2 mm or less (Fig. 16).


Dental implant treatment is a powerful option in the treatment choice for edentulous ridge and is now replacing many parts of the traditional prosthodontic treatment. In general losing teeth is accompanied by atrophic alveolar ridge, which compels dentists into complete understanding of the biology of bone augmentation to maximize the benefit of the patients. Ever accumulating medical information and technologies have been increasing the quality of life of many patients. Although still obscure many aspects of the biology of the bone grafting; i.e. the matter of choice, are nowadays being elucidated with molecular biological advancement. What is more, what makes the edentulous bone atrophic; i.e. the matter of why, is unveiling its secret through unwearrying enthusiasm of the many brilliant scientists. Having a long way to go, we're still on the road.

5. References

- Aghaloo, T.L., Felsenfeld, A.L., & Tetradis, S. (2010). Osteonecrosis of the jaw in a patient on Denosumab. *Journal of Oral and Maxillofacial Surgery*, Vol.68, No.5, (May 2010), pp.959-963, ISSN 0278-2391
- Bakker, A.D., Soejima, K., Klein-Nulend, J., & Burger, E.H. (2001). The production of nitric oxide and prostaglandin E(2) by primary bone cells is shear stress dependent. *Journal of Biomechanics*, Vol.34, No.5, (May 2001), pp.671-677, ISSN 0021-9290
- Bilezikian, J.P., Raisz, L.G., & Rodan, G.A. (2002). *Principles of Bone Biology*(2nd ed.), Academic Press, ISBN 0-12-098652-3, London, UK
- Boyne, P.J. & James, R.A. (1980). Grafting of the maxillary sinus floor with autogenous marrow and bone. *Journal of Oral Surgery*, Vol.38, No.8, (August 1980), pp.613-616, ISSN 0022-3255
- Burger, E.H. & Klein-Nulend, J. (1999). Mechanotransduction in bone-role of the lacuno-canalicular network. *FASEB J*, Vol.13, No.Suppl, (May 1999), pp.S101-112, ISSN 0892-6638
- Carter, D.R., Beaupré, G.S., Giori, N.J., & Helms, J.A. (1998). Mechanobiology of skeletal regeneration. *Clinical Orthopedics and Related Research*, Vol.355, No.Suppl, (October 1998), ppS41-55, ISSN 0009-921X
- Cheng, B., Zhao, S., Luo, J., Sprague, E., Bonewald, L.F., & Jiang, J.X. (2001). Expression of functional gap junctions and regulation by fluid flow in osteocyte-like MLO-Y4 cells. *Journal of Bone and Mineral Research*, Vol.16, No.2, (February 2001), pp.249-259, ISSN 0884-0431

- Cherian, P.P., Siller-Jackson, A.J., Gu, S., Wang, X., Bonewald, L.F., Sprague, E. & Jiang, J.X. (2005). Mechanical strain opens connexin 43 hemichannels in osteocytes: a novel mechanism for the release of prostaglandin. *Molecular Biology of the Cell*, Vol.16, No.7, (July 2005), pp.3100-3106, ISSN 1059-1524
- Civitell, R. (2008). Cell-cell communication in the osteoblast/osteocyte lineage. *Archives of Biochemistry and Biophysics*, Vol.473, No.2, (May 2008), pp.188-192, ISSN 0003-9861
- De Clercq, C.A., Abeloos, J.S., Mommaerts, M.Y., & Neyt, L.F. (1995). Temporomandibular joint symptoms in an orthognathic surgery population. *Journal of Craniomaxillofacial Surgery*, Vol.23, No.3, (June 1995), pp.195-199, ISSN 1010-5182
- Frost, H.M. (1996). Perspectives: a proposed general model of the "mechanostat" (suggestions from a new skeletal-biologic paradigm). *Anatomical Record-Advances in Integrative Anatomy and Evolutionary Biology*, Vol.244, No.2, (February 1996), pp. 139-147, ISSN 1932-8486
- Harada, S. & Rodan, G.A. (2003). Control of osteoblast function and regulation of bone mass. *Nature*, Vol.423, No.6937, (May 2003), pp.349-355, ISSN 0028-0836
- Huang, H., Kamm, R.D., & Lee, R.T. (2004). Cell mechanics and mechanotransduction: pathways, probes, and physiology. *American Journal of Physiology-Cell Physiology*, Vol.287, No.1, (July 2004), pp.C1-C11, ISSN 0363-6143
- Jaalouk, D.E. & Lammerding, J. (2009). Mechanotransduction gone awry. *Nature Reviews Molecular Cell Biology*, Vol.10, No.1, (January 2009), pp63-73, ISSN 1471-0072
- Jørgensen, N.R., Teilmann, S.C., Henriksen, Z., Civitelli, R., Sørensen, O.H., & Steinberg, T.H. (2003). Activation of L-type calcium channels is required for gap junction-mediated intercellular calcium signaling in osteoblastic cells. *Journal of Biological Chemistry*, Vol.278, No.6, (February 2003), pp.4082-4086, ISSN 0021-9258
- Lavery, K.M. (1994). Basic principles of treatment, In: *Rowe and Williams' Maxillofacial Injuries*, Williams, J.Ll., pp.51-64, Churchill Livingstone, ISBN 0 443 04591 7, Edinburgh, UK
- Lee, J.K. (2010). Outfracture osteotomy on lateral maxillary wall as a modified sinus graft technique. *Journal of Oral and Maxillofacial Surgery*, Vol.68, No.7, (July 2010), pp.1639-1641, ISSN 0278-2391
- Machwate, M., Harada, S., Leu, C.T., Seedor, G., Labelle, M., Gallant, M., Hutchins, S., Lachance, N., Sawyer, N., Slipetz, D., Metters, K.M., Rodan, S.B., Young, R., & Rodan, G.A. (2001). Prostaglandin Receptor EP₄ Mediates the Bone Anabolic Effects of PGE₂. *Molecular Pharmacology*, Vol. 60, No. 1, (July 2001), pp.36-41, ISSN 0026-895X
- MacKinnon, P.C.B. & Morris, J.F. (1990). *Oxford Textbook of Functional Anatomy*. Vol.3, Oxford University Press, ISBN 0-19-261519-X, London, UK
- Marx RE. (2003). Pamidronate (Aredia) and zolendronate (Zometa) induced avascular necrosis of the jaws: a growing epidemic. *Journal of Oral and Maxillofacial Surgery*, Vol.61, No.9, (September 2003), pp. 1115-1117. ISSN 0278-2391
- Misch, C.E. (2008). *Contemporary Implant Dentistry* (3rd ed.), Mosby, ISBN 978-0-323-04373-1, St. Louis, MO

- Moss, M.L. (1997). The functional matrix hypothesis revisited. 2. The role of an osseous connected cellular network. *American Journal of Orthodontics and Dentofacial Orthopedics*, Vol.112, No.2, (February 1997) pp.221-226, ISSN 0889-5406
- Park, H.W. (2005). *Human Embryology*(3rd ed.), Koonja Publishing Co., ISBN 89-7089-534-5, Seoul, Korea
- Reich, K.M., Mcallister, T.N., Gudi, S, & Frangos, J.A. (1997). Activation of G Proteins Mediates Flow-Induced Prostaglandin E2 Production in Osteoblasts. *Endocrinology*, Vol. 138, No. 3, (March 1997) pp.1014-1018, ISSN 0013-7227
- Robling, A.G., Castillo, A.B., & Turnern, C.H. (2006). Biomechanical and molecular regulation of bone remodeling. *Annual Review of Biomedical Engineering*, Vol.8, No.1, (January 2006) pp.455-498, ISSN 1523-9829
- Shapiro, F. (2008). Bone development and its relation to fracture repair. The role of mesenchymal osteoblasts and surface osteoblasts. *European Cells and Materials*, Vol.15, No.1, (April 2008) pp.53-76, ISSN 1473-2262
- Siller-Jackson, A. J., Burra, S., Gu, S., Xia, X., Bonewald, L.F., Sprague, E., & Jiang, J.X. (2008). Adaptation of Connexin 43-Hemichannel Prostaglandin Release to Mechanical Loading. *Journal of Biological Chemistry*, Vol.283, No.39, (September 2008) pp.26374-26382, ISSN 0021-9258
- Singer, N. (November 10, 2010). Drug Suits Raise Questions for Doctors, and Juries, In: *the New York Times*, January 10, 2010, Available from:
http://www.nytimes.com/2010/11/11/health/11bone.html?_r=1&ref=merckandcompany
- Song, S.I., Jeong, H.R., Kim, H.M., & Lee, J.K. (2009). Clinical investigation on the feasibility of outfracture osteotomy sinus graft technique. *Journal of Korean Association of Oral and Maxillofacial Surgery*, Vol.35, No.5, (October 2009), pp.367-371, ISSN 1225-1585
- Tatum, H. Jr. (1986). Maxillary and sinus implant reconstructions. *Dental Clinics of North America*, Vol.30, No.2, (April 1986), pp.207-229, ISSN 0011-8532
- Taylor, K.H., Middlefell, L.S., & Mizen, K.D. (2010). Osteonecrosis of the jaws induced by anti-RANK ligand therapy. *British Journal of Oral and Maxillofacial Surgery*, Vol.48, No.3, (April 2010) pp. 221-223, ISSN 0266-4356
- van Bezooijen, R.L., Svensson, J.P., Eefting, D., Visser, A., van der Horst, G., Karperien, M., Quax, P.H., Vrieling, H., Papapoulos, S.E., ten Dijke, P., & Löwik, C.W. (2007). Wnt but not BMP signaling is involved in the inhibitory action of sclerostin on BMP-stimulated bone formation. *Journal of Bone and Mineral Research*, Vol.22, No.1, (January 2007), pp.19-28, ISSN 0884-0431
- Vitkov, L., Gellrich, N.C., & Hannig, M. (2005). Sinus floor elevation via hydraulic detachment and elevation of the Schneiderian membrane. *Clinical Oral Implants Research*, Vol.16, No.5, (October 2005), pp.615-621, ISSN 0905-7161



Implant Dentistry - A Rapidly Evolving Practice

Edited by Prof. Ilser Turkyilmaz

ISBN 978-953-307-658-4

Hard cover, 544 pages

Publisher InTech

Published online 29, August, 2011

Published in print edition August, 2011

Implant dentistry has come a long way since Dr. Branemark introduced the osseointegration concept with endosseous implants. The use of dental implants has increased exponentially in the last three decades. As implant treatment became more predictable, the benefits of therapy became evident. The demand for dental implants has fueled a rapid expansion of the market. Presently, general dentists and a variety of specialists offer implants as a solution to partial and complete edentulism. Implant dentistry continues to evolve and expand with the development of new surgical and prosthodontic techniques. The aim of *Implant Dentistry - A Rapidly Evolving Practice*, is to provide a contemporary clinic resource for dentists who want to replace missing teeth with dental implants. It is a text that relates one chapter to every other chapter and integrates common threads among science, clinical experience and future concepts. This book consists of 23 chapters divided into five sections. We believe that, *Implant Dentistry: A Rapidly Evolving Practice*, will be a valuable source for dental students, post-graduate residents, general dentists and specialists who want to know more about dental implants.

How to reference

In order to correctly reference this scholarly work, feel free to copy and paste the following:

Jeong Keun Lee (2011). Bone Biology for Implant Dentistry in Atrophic Alveolar Ridge - Theory and Practice, *Implant Dentistry - A Rapidly Evolving Practice*, Prof. Ilser Turkyilmaz (Ed.), ISBN: 978-953-307-658-4, InTech, Available from: <http://www.intechopen.com/books/implant-dentistry-a-rapidly-evolving-practice/bone-biology-for-implant-dentistry-in-atrophic-alveolar-ridge-theory-and-practice>

INTECH
open science | open minds

InTech Europe

University Campus STeP Ri
Slavka Krautzeka 83/A
51000 Rijeka, Croatia
Phone: +385 (51) 770 447
Fax: +385 (51) 686 166
www.intechopen.com

InTech China

Unit 405, Office Block, Hotel Equatorial Shanghai
No.65, Yan An Road (West), Shanghai, 200040, China
中国上海市延安西路65号上海国际贵都大饭店办公楼405单元
Phone: +86-21-62489820
Fax: +86-21-62489821

© 2011 The Author(s). Licensee IntechOpen. This chapter is distributed under the terms of the [Creative Commons Attribution-NonCommercial-ShareAlike-3.0 License](#), which permits use, distribution and reproduction for non-commercial purposes, provided the original is properly cited and derivative works building on this content are distributed under the same license.

IntechOpen

IntechOpen