

ORIGINAL RESEARCH

# Relation Between Subacromial Bursitis on Ultrasonography and Efficacy of Subacromial Corticosteroid Injection in Rotator Cuff Disease: A Prospective Comparison Study



Doo-Hyung Lee, MD, PhD,<sup>a</sup> Ji Yeon Hong, MD, MS,<sup>b</sup> Michael Young Lee, MD, MHA,<sup>c</sup> Kyu-Sung Kwack, MD, PhD,<sup>d</sup> Seung-Hyun Yoon, MD, PhD<sup>b</sup>

From the <sup>a</sup>Department of Orthopedic Surgery, Ajou University School of Medicine, Suwon, Republic of Korea; <sup>b</sup>Department of Physical Medicine and Rehabilitation, Ajou University School of Medicine, Suwon, Republic of Korea; <sup>c</sup>Department of Physical Medicine and Rehabilitation, University of North Carolina at Chapel Hill School of Medicine, Chapel Hill, NC; and <sup>d</sup>Department of Radiology, Ajou University School of Medicine, Suwon, Republic of Korea.

## Abstract

**Objective:** To evaluate the correlations between subacromial bursitis (bursal thickening and effusion) on ultrasonography and its response to subacromial corticosteroid injection in patients with rotator cuff disease.

**Design:** Prospective, longitudinal comparison study.

**Setting:** University-affiliated tertiary care hospital.

**Participants:** Patients with rotator cuff disease (N=69) were classified into 3 groups based on ultrasonographic findings; (1) normative bursa group (group 1, n=23): bursa and effusion thickness <1mm; (2) bursa thickening group (group 2, n=22): bursa thickness >2mm and effusion thickness <1mm; and (3) bursa effusion group (group 3, n=24): bursa thickness <1mm and effusion thickness >2mm.

**Intervention:** A single subacromial injection with 20mg of triamcinolone acetonide.

**Main Outcome Measures:** Visual analog scale (VAS) of shoulder pain, Shoulder Disability Questionnaire (SDQ), angles of active shoulder range of motion (flexion, abduction, external rotation, and internal rotation), and bursa and effusion thickness at pre- and posttreatment at week 8.

**Results:** There were no significant differences between the 3 groups in demographic characteristics pretreatment. Groups 2 and 3 showed a significant difference compared with group 1 in changes on the VAS and abduction; group 3 showed a significant difference compared with group 1 in changes of the SDQ, internal rotation, and external rotation; and all groups showed significant differences when compared with each other (groups 1 and 3, 2 and 3, and 1 and 2) in changes of thickness.

**Conclusions:** A patient with ultrasonographic observation of subacromial bursitis, instead of normative bursa, can expect better outcome with subacromial corticosteroid injection. Therefore, we recommend a careful selection of patients using ultrasonography prior to injection.

Archives of Physical Medicine and Rehabilitation 2017;98:881-7

© 2016 by the American Congress of Rehabilitation Medicine

Rotator cuff disease is a common cause of shoulder pain and disability in the upper extremity. Many nonoperative treatments have been advocated, including rest, physical therapy, nonsteroidal anti-inflammatory drugs, exercise, and subacromial corticosteroid injection.<sup>1,2</sup> Subacromial corticosteroid injection still remains one of the most common procedures for treating rotator cuff disease among practicing orthopedists, rheumatologists, and general

practitioners. Previous studies of subacromial corticosteroid injections for rotator cuff disease have reported conflicting results ranging from no effect to dramatic improvements, in part because of differences in the patient selection criteria.<sup>3-6</sup> The appropriate indications for use of subacromial corticosteroid injections, including for rotator cuff disease, remain controversial.<sup>7</sup> Some advocate limiting subacromial corticosteroid injections to treatment of inflammatory conditions (eg, impingement syndrome, subacromial bursitis) rather than chronic rotator cuff tendinosis or tear

Disclosures: none.

originating from degenerative changes.<sup>7-9</sup> For example, one study of patients with chronic rotator cuff disease lasting  $\geq 6$  months found no difference in outcomes between subacromial corticosteroid injections and placebo.<sup>10</sup> However, other studies have found that subacromial corticosteroid injections can be effective even for patients with symptoms lasting  $> 6$  months.<sup>5,11,12</sup>

Given the disparate results of prior studies of subacromial corticosteroid injections for chronic rotator cuff disease, the objective of this study is to determine if patients with chronic rotator cuff disease who have evidence of inflammation of the subacromial bursa respond more to corticosteroid injections than people without inflammatory changes. We hypothesized that patients with ultrasound findings of subacromial bursal thickening and effusion indicative of an inflammatory process around the rotator cuff will have better outcomes after subacromial corticosteroid injections than people without bursal thickening and effusions.

## Methods

### Participants

This is a prospective, longitudinal comparison study. The study was approved by the institutional review board at the university hospital, and all participants gave written informed consent. Participants were diagnosed with nontraumatic rotator cuff disease in the outpatient rehabilitation clinic of the university-affiliated tertiary care hospital between October 2010 and June 2011. All patients underwent a standardized history and physical examination by the lead author, including passive and active range of motion, painful arc and impingement test, resisted test, and strength of muscles in the affected shoulder.

Inclusion criteria were patients (1) with clinically and ultrasonographically diagnosed rotator cuff disease of the shoulder—impingement, tendinosis, and small-sized ( $< 2$  mm in maximal length) partial-thickness tear; (2) aged 35 to 60 years; (3) who reported shoulder pain of 5 to 10 months' duration involving the deltoid region; (4) with unilateral shoulder symptoms; (5) with pain of moderate to severe intensity, defined as a score of  $\geq 4$  on a 10-cm visual analog scale (VAS) rated from 0 (no pain) to 10 (worst imaginable pain); and (6) with persisting pain despite at least 1 month of noninvasive and conservative treatments. Exclusion criteria were (1) larger-sized partial- (size  $> 2$  mm) or full-thickness tear; (2) current adhesive capsulitis (normative radiograph of affected shoulder and restriction of passive motion  $> 30^\circ$  in  $\geq 2$  planes of movement)<sup>13</sup>; (3) calcification of the rotator cuff, demonstrated by simple radiography or ultrasonography; (4) identification of only the disorders of biceps tendon or acromioclavicular joint, and not rotator cuff disease, by positive Yergason and Speed tests, respectively, with focal tenderness on bicipital groove or acromioclavicular joint<sup>14,15</sup>; (5) presence of another medical or psychological condition, including cancer, rheumatoid arthritis, endocrine disease (ie, diabetes), major depression, or schizophrenia; (6) previous major trauma history at currently affected shoulder; (7) primary osteoarthritis of the glenohumeral joint in a simple radiograph; (8) previous corticosteroid injection history at the affected shoulder; and (9) those with workers' compensation benefits.

#### List of abbreviations:

SDQ Shoulder Disability Questionnaire  
VAS visual analog scale

A schematic flow of the study is included in figure 1. A total of 75 patients were recruited after a screening evaluation. Patients were assigned to 1 of 3 groups according to ultrasonographic findings.

### Sample size

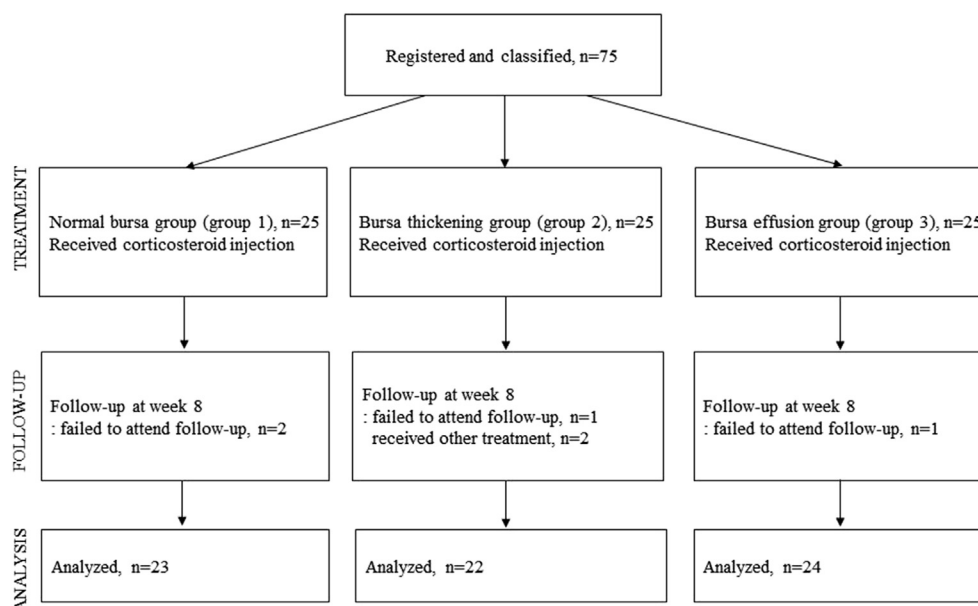
The required sample size was determined on the basis of a previous study of patients with rotator cuff disease who received subacromial corticosteroid injection with a follow-up of 8 weeks.<sup>16</sup> A power analysis program<sup>a</sup> was used to calculate the number of participants required.<sup>17</sup> Using the means of the VAS from the study groups, we obtained a minimal sample size of 72, with an  $\alpha$  of .05,  $1-\beta$  of .95, and SD of 2.3. A total of 75 participants were required to allow for 5% loss to follow-up. At the final analysis, 69 instead of 75 participants were included, and analysis power ( $1-\beta$ ) was .88.

### Ultrasonographic evaluation

Ultrasonography was performed by a musculoskeletal radiologist (K.-S.K.) with 12 years of experience. Ultrasound equipment<sup>b</sup> with a 10- to 13-MHz linear array transducer was used. Previously published studies were referenced to make final decisions on imaging interpretations.<sup>18-21</sup> Long- and short-axis scans from the rotator cuff, subacromial bursa, and biceps tendon were obtained. The biceps tendon, subscapularis tendon, and acromioclavicular joint were examined while the patient sat with his/her arm held in a neutral position and elbow flexed  $90^\circ$ . Supraspinatus tendon and subacromial bursa were evaluated in a modified Crass position. An ultrasonographic examination of the opposite side was performed routinely in all patients. We calculated the subacromial bursa thickness from the superficial peribursal fibrofatty tissue to the upper margin of the supraspinatus.<sup>22</sup> Abnormal bursal thickening was defined as thickness of  $> 2$  mm.<sup>18</sup> Subacromial bursal effusion was defined as hypoechogenic fluid in bursa  $> 2$  mm.<sup>16,20</sup> We selected the thickest measurement from the subacromial bursal thickening and effusion in transverse or longitudinal planes of the area scanned. Subacromial impingement was defined as pooling of subacromial bursa lateral to the acromion by dynamic examination.<sup>19</sup> Following previous studies, we classified patients into 3 groups: (1) normative bursa group (group 1): bursa and effusion thickness  $< 1$  mm, (2) bursa thickening group (group 2): bursa thickness  $> 2$  mm and effusion thickness  $< 1$  mm, and (3) bursa effusion group (group 3): bursa thickness  $< 1$  mm and effusion thickness  $> 2$  mm.

### Subacromial corticosteroid injection

After the physical and ultrasound examination, the physiatrist (S.-H.Y.) injected a mixture of 20 mg (10 mg/mL) triamcinolone acetonide 2 mL and 1% lidocaine 2 mL. For a better visualization of the bursa, an ample amount of gel was used during the injection to minimize the pressure from the probe. Patients sat upright, arms positioned behind their backs with extension and internal rotation of the shoulder and elbow bent for longitudinal supraspinatus view. A 23-gauge, 6-cm-long needle was injected parallel to the probe in a semi-oblique plane from the posterior side of the shoulder. The needle was administered under real-time ultrasound equipment<sup>c</sup> until the needle tip entered the bursa. Patients had to stay at the hospital for  $> 20$  minutes after the injection for any signs of acute adverse reactions, including local bleeding, weakness, anaphylaxis, and vasovagal reaction. Late adverse reactions,



**Fig 1** Flow diagram indicating progress of subjects through the study.

including a postinjection flare of pain, disturbance of menstrual pattern, facial flushing, subcutaneous tissue atrophy, skin depigmentation, infection, and tendon rupture, were also checked at week 8 follow-up. After the injection, all participants received verbal and written education from the physical therapist on a home exercise program that included flexibility and strengthening exercises of the shoulder girdle and rotator cuff. Patients on analgesics at pretreatment were told to stop taking them 5 days before the injection. After the injection, they were instructed not to take any oral pain medications, with the exception of acetaminophen, and were prohibited from receiving any treatments other than the prescribed exercise program.

## Outcome measurements

Participants were assessed at pretreatment and week 8 after the injection by an evaluator (J.Y.H.) not informed of ultrasonographic findings. The primary outcome measure was VAS for shoulder pain intensity. Patients answered the question “with respect to the worst pain you have experienced in your life, what was the average level of your shoulder pain in the past 1 week?” by placing a mark somewhere along the 10-cm horizontal line between 2 end points (from 0 [no pain] to 10 [worst imaginable pain]). The secondary outcome measures were the Shoulder Disability Questionnaire (SDQ) and active range of motion of the shoulder. The SDQ score is commonly used in clinical trials to evaluate shoulder disability, has proven levels of validity, and consists of 22 self-reporting items that participants respond to with either yes or no. The SDQ has demonstrated strong associations with quality of life measures and compares favorably with other published shoulder disability questionnaires in terms of overall validity and patient acceptability. The score ranges between 0 (no disability) and 22 (maximal disability).<sup>23,24</sup> Active range of motion was measured by a goniometer for flexion, abduction, external rotation, and internal rotation of the shoulder in a standing position. Patients were asked to move their shoulders slowly, and the angle on onset of pain was measured 3 times to

record the average value. Forward flexion and abduction were measured with palm down, and external and internal rotations were measured with 90° abduction of shoulder and 90° flexion of elbow position.

## Statistical analysis

After a normality test, we compared the 3 groups in terms of age, sex, duration of symptoms, affected shoulder, and ultrasonographic findings of rotator cuff lesion by performing Kruskal-Wallis, chi-square, and Fisher exact tests. Analysis of variance and independent *t* test were carried out to compare the bursa and effusion thickness between unaffected shoulders, and between the affected and unaffected shoulders. We also performed analysis of covariance with the Bonferroni method to compare the changes in outcomes between the 3 groups. Covariates were VAS score, SDQ score, flexion, abduction, external rotation, internal rotation, and bursa and effusion thickness at week 0. Significance was accepted for *P* values <.05. All analyses were performed using SPSS statistical software, version 22.<sup>d</sup>

## Results

Of the 75 patients recruited, 2 in group 1, 1 in group 2, and 1 in group 3 failed to attend the follow-up. Two other patients in group 2 not satisfied with the injection opted out and received other treatments (one patient received arthroscopic acromioplasty and the other received acupuncture). A total of 69 patients were included in the final analysis (see [fig 1](#)). There were no significant differences between the 3 groups in terms of age, sex, duration of symptoms, affected shoulder, and ultrasonographic findings of rotator cuff lesion at pretreatment (*P*>.05) ([table 1](#)).

The ultrasonographic examination performed on the unaffected shoulder showed 6 patients (8.7% in total; group 1: n=1, group 2: n=3, and group 3: n=2) having abnormal bursal thickening and effusion, and there was no significant difference in the average

**Table 1** Baseline characteristics of participants

Characteristics	Group 1 (n=23)	Group 2 (n=22)	Group 3 (n=24)	P
Age, y	51.6±8.6	48.6±8.1	51.2±9.3	.59*
Sex, men:women	10:13	5:17	8:16	.34 <sup>†</sup>
Duration of symptom, mo	8.1±2.1	8.2±1.9	8.3±1.7	.93*
Shoulder affected, dominant:nondominant	16:7	16:6	13:11	.36 <sup>†</sup>
Ultrasonographic lesions of rotator cuff				
Tendinosis only:partial thickness tear	18:5	14:8	21:3	.16 <sup>‡</sup>
Impingement <sup>‡</sup>	2	2	5	.48 <sup>§</sup>
Biceps tendinosis <sup>‡</sup>	5	3	6	.66 <sup>§</sup>

NOTE. Values are expressed as number of participants, mean ± SD, or as otherwise indicated.

\* Kruskal-Wallis test for 3-group comparison ( $P < .05$ ).

<sup>†</sup> Chi-square test for 3-group comparison ( $P < .05$ ).

<sup>‡</sup> Impingement and biceps tendinosis counts duplicated with tendinosis or partial thickness tear counts.

<sup>§</sup> Fisher exact test for 3-group comparison ( $P < .05$ ).

bursa and effusion thickness among the 3 groups ( $P = .368$ ). Although no difference was found in the average bursa and effusion thickness between the affected and unaffected shoulders before the injection in group 1 ( $0.5 \pm 0.3$  and  $0.5 \pm 0.5$ , respectively;  $P = .922$ ), a significant difference was found in group 2 ( $3.0 \pm 0.6$  and  $0.6 \pm 0.9$ , respectively;  $P < .001$ ) and group 3 ( $3.8 \pm 0.7$  and  $0.8 \pm 0.8$ , respectively;  $P < .001$ ).

As for lesions concomitantly found with rotator cuff disease, 14 had biceps tendinopathy (20.3% in total;  $n = 5$ ,  $n = 3$ , and  $n = 6$  in groups 1, 2, and 3, respectively) and 6 had acromioclavicular joint injury (8.7%;  $n = 0$ ,  $n = 4$ , and  $n = 2$  in groups 1, 2, and 3, respectively). No participants were found to have both lesions. No single lesion of subscapularis was involved. Comparing the changes of outcomes between pretreatment and week 8, there were significant differences between group 1 and groups 2 and 3 in changes of VAS ( $P < .001$ ) and abduction ( $P = .002$ ); between groups 1 and 3 in changes of SDQ ( $P = .039$ ), internal rotation ( $P = .004$ ), and external rotation ( $P = .008$ ); and between all 3 groups (1 vs 2 vs 3) in changes of thickness ( $P < .001$ ) (table 2).

## Discussion

Subacromial corticosteroid injection is one of the most common treatments for rotator cuff disease, but there are currently not enough guidelines on its indications because of the paucity of research. Based on this study, we suggest more objective criteria of subacromial corticosteroid injection for rotator cuff disease. We assessed the relation between the inflammatory state of the subacromial bursa and the effect of subacromial corticosteroid injection in rotator cuff disease. Inflammation of the rotator cuff is shown on ultrasonography as subacromial bursitis (bursal thickening and effusion), and the effect of corticosteroid appears to be greater in patients with subacromial bursitis than normative bursa. Patients found to have subacromial bursitis on ultrasonography prior to corticosteroid injection can expect positive improvements in pain and range of motion.

Although different studies have reported varying ratios (6%–78%) of patients having bursitis even in asymptomatic shoulders (8.7% in this study),<sup>19,25</sup> most authors agree that there is a close

relation between the symptoms originating from rotator cuff disease and bursitis. The bursa in the symptomatic shoulder is thicker than that of the asymptomatic shoulder,<sup>22</sup> subacromial bursitis is often secondary to rotator cuff disease, and >90% of patients with pathologic distension of the subacromial bursa had rotator cuff tears.<sup>18,26</sup> The subacromial bursa, composed of synovium, has a denser net of free nerve endings than other anatomic structures of the shoulder and therefore may be the most important source of pain in rotator cuff disease.<sup>27–30</sup> This theory might explain why subacromial corticosteroid injection reduces pain in patients with rotator cuff disease.<sup>30</sup>

Other than the acute, subacute, or chronic inflammation detected on ultrasonography, the time of subacromial corticosteroid injection or the symptoms duration prior to injection can also be major factors affecting the effect of the injection. The average duration of symptoms for the patients of this study was  $8.2 \pm 1.9$  months (range, 5–10 mo), known as subacute to early chronic patients with rotator cuff disease. Although no study has so far proved the adequate timing of subacromial corticosteroid injection, the general assumption is that an early injection in an acute stage would be more effective. However, in most cases, subacromial corticosteroid injection is not performed immediately but rather when pain persists, which can mean up to a few months after noninvasive and conservative management. This is the reason why we also recruited subacute to early chronic—and not acute—stage patients with rotator cuff disease with 5 to 10 months' duration of persisting pain even after conservative management.

In our literature review, we were only able to find a few studies that explored the outcome of rotator cuff disease after subacromial corticosteroid injection. In a study which looked into the relation between activity level after subacromial corticosteroid injection, American Shoulder and Elbow Surgeons score, duration of symptoms, and status of the rotator cuff and symptoms, none of the factors turned out to be clearly associated with a response. The authors of the same study did not read the ultrasonographic findings.<sup>31</sup> In another study which attempted to observe the efficacy of subacromial injection with corticosteroid and local anesthetic in patients with abnormal ultrasonographic findings of the bursa, no correlation was reported between ultrasonographic findings and the efficacy of subacromial injection. Limitations of this second study include short-term (10 min) observation of the

**Table 2** Changes of outcome measurements after subacromial corticosteroid injection

Variable	Group 1 (n=23)	Group 2 (n=22)	Group 3 (n=24)	P*
<b>VAS score</b>				
Pretreatment	5.4±1.2	5.7±1.3	6.0±1.0	
Week 8	3.2±1.4	2.0±1.1	1.9±1.1	
Change	-2.2±1.6	-3.7±1.2	-4.0±1.6	<.001 <sup>†</sup>
<b>SDQ score</b>				
Pretreatment	11.5±3.8	11.8±3.0	13.0±2.7	
Week 8	5.8±3.8	5.5±2.9	4.0±2.0	
Change	-5.7±4.2	-6.4±3.4	-9.0±3.5	.039 <sup>‡</sup>
<b>Flexion</b>				
Pretreatment	150.4±12.0	149.6±15.6	152.1±14.1	
Week 8	160.8±16.8	163.4±13.6	164.3±12.1	
Change	10.4±10.4	13.8±13.8	12.2±11.4	.630
<b>Abduction</b>				
Pretreatment	133.43±17.4	121.2±18.6	132.4±18.8	
Week 8	154.8±16.7	160.4±10.7	167.3±13.1	
Change	21.4±12.2	39.2±23.8	34.9±12.6	.002 <sup>†</sup>
<b>External rotation</b>				
Pretreatment	69.0±10.3	67.0±16.2	58.9±8.9	
Week 8	76.0±12.6	83.9±16.0	83.5±12.7	
Change	7.1±9.9	16.9±18.0	24.6±12.8	.008 <sup>‡</sup>
<b>Internal rotation</b>				
Pretreatment	28.7±11.8	26.4±10.0	23.3±9.0	
Week 8	47.5±17.5	52.5±11.0	54.4±9.1	
Change	18.8±15.8	26.1±16.1	31.1±13.4	.004 <sup>‡</sup>
<b>Thickness of bursal thickening and effusion</b>				
Pretreatment	0.5±0.3	3.0±0.6	3.8±0.7	
Week 8	0.3±0.3	1.9±0.5	1.3±0.9	
Change	-0.2±0.3	-1.1±0.6	-2.5±1.1	<.001 <sup>§</sup>

NOTE. Values are mean ± SD or as otherwise indicated.

\* Analysis of covariance with the Bonferroni method to compare the change of outcome in the 3 groups ( $P<.05$ ). Covariates were VAS score, SDQ score, flexion, abduction, external rotation, internal rotation, and thickness of bursal thickening and effusion at week 0.

<sup>†</sup> Significant differences between group 1 and groups 2 and 3 in changes of VAS and abduction ( $P<.05$ ).

<sup>‡</sup> Significant differences between group 1 and group 3 in changes of SDQ, internal rotation, and external rotation ( $P<.05$ ).

<sup>§</sup> Significant differences between the 3 groups (1 vs 2 vs 3) in changes of thickness ( $P<.05$ ).

effect, which looked only into the effect of the local anesthetic rather than the corticosteroid; patients with full-thickness tears taking up to 21% of the total number of subjects, potentially raising the possibility of bursal effusion being a leakage of synovial fluid rather than inflammation; and not enough patients ( $n=9$ ) in the nonintervention group.<sup>32</sup>

## Study limitations

This study is not without limitations. First, although simple radiograph, ultrasonography, and physical examinations to exclude participants with secondary adhesive capsulitis were performed, patients with labral lesions or small full-thickness tears of the rotator cuff could have still been missed in the absence of a magnetic resonance imaging evaluation. In the same context, the absence of magnetic resonance imaging in measuring the thickness of bursa and effusion or during the follow-up could be a limitation. We have also used ultrasonography to exclude the full-thickness tear, but bursa effusion could possibly have occurred because of a small full-thickness tear undetectable by ultrasonography. Second, although most participants in this study

were patients with rotator cuff tendinosis, there were also some who had partial-thickness tears (23.2% in total). The result may have been affected because the 2 pathologies, tendinosis and partial-thickness tear, can have different responses to subacromial corticosteroid injection. Nonetheless, there were no significant differences in the ratio of partial-thickness tear patients among the 3 groups. We tried to minimize bias by including only very small-sized partial-thickness tears of <2mm. Third, although subacromial bursitis is widely known to be the major disease that causes symptoms of rotator cuff disease,<sup>27-30</sup> other disorders of the biceps tendon and acromioclavicular joint (instability or arthritis) could also cause pain. The aim of this study was to evaluate the correlations between subacromial bursitis and its response to subacromial corticosteroid injection in rotator cuff disease. Therefore, to remove other factors that may contribute to shoulder pain, we excluded participants whose major reasons for shoulder pain were disorders of the biceps tendon and acromioclavicular joint. However, because it was almost impossible to completely exclude these diseases, there were still 20.3% of the participants who concomitantly had biceps tendinopathy and 8.7% acromioclavicular joint injury, which may have affected the

result. Also, shoulder muscle (glenohumeral and scapulothoracic) imbalance, stiffness, injury of ligament, and microtear of tendon can also cause pain in rotator cuff disease<sup>33-37</sup> and therefore may have acted as confounding factors. Fourth, to strengthen the robustness of statistics, an equal number of participants were allocated to each of the 3 groups. However, not much is known about the natural ratio of symptomatic rotator cuff patients with normal bursas, thickening bursas, and bursas with effusion, as determined by ultrasonography. Of note, one trial<sup>38</sup> performed consecutive series of ultrasonography in 1105 subjects with shoulder pain and showed that of the 217 subjects with partial-thickness tear, the ratio of those without to those with subacromial bursitis was 65:152, a ratio similar to our study (23:46). However, all 217 subjects were analyzed for partial-thickness tear and not separately for thickening and effusion. If the design that we have balanced in our study does not reflect the natural ratio, neither would our sampling perhaps represent the state of nature.

## Conclusions

This study illustrates the effect of subacromial corticosteroid injection on patients with subacute to early chronic nontraumatic rotator cuff disease, suggesting further breakdown in the current indication. According to the study, a better outcome after subacromial corticosteroid injection can be expected after subacromial corticosteroid injection for patients who have bursal thickening or effusion—rather than normative reading—on ultrasonography. Therefore, we recommend a careful selection of patients using ultrasonography prior to injection.

## Suppliers

- G\*Power3; Heinrich-Heine-University.
- HD 11XE; Philips Ultrasound.
- Logiq P6; GE Healthcare.
- SPSS, version 22; IBM.

## Keywords

Bursitis; Injections; Rehabilitation; Rotator cuff; Shoulder impingement syndrome; Shoulder pain; Tendinopathy; Ultrasonography

## Corresponding author

Seung-Hyun Yoon, MD, PhD, Department of Physical Medicine and Rehabilitation, Ajou University School of Medicine, Worldcup-ro 164, Yeongtong-gu, Suwon 16499, Republic of Korea. *E-mail address:* yoonsh@ajou.ac.kr.

## Acknowledgments

We thank Aeree Park, MA, for the English translation of the Korean manuscript and Hyun Young Lee, PhD, for statistical support.

## References

- Whittle S, Buchbinder R. In the clinic. Rotator cuff disease. *Ann Intern Med* 2015;162:ITC1-15.
- Codsi M, Howe CR. Shoulder conditions: diagnosis and treatment guideline. *Phys Med Rehabil Clin N Am* 2015;26:467-89.
- Naredo E, Cabero F, Beneyto P, et al. A randomized comparative study of short term response to blind injection versus sonographic-guided injection of local corticosteroids in patients with painful shoulder. *J Rheumatol* 2004;31:308-14.
- Blair B, Rokito AS, Cuomo F, Jarolem K, Zuckerman JD. Efficacy of injections of corticosteroids for subacromial impingement syndrome. *J Bone Joint Surg Am* 1996;78:1685-9.
- Adebajo AO, Nash P, Hazleman BL. A prospective double blind dummy placebo controlled study comparing triamcinolone hexacetonide injection with oral diclofenac 50 mg TDS in patients with rotator cuff tendinitis. *J Rheumatol* 1990;17:1207-10.
- White RH, Paull DM, Fleming KW. Rotator cuff tendinitis: comparison of subacromial injection of a long acting corticosteroid versus oral indomethacin therapy. *J Rheumatol* 1986;13:608-13.
- Gruson KI, Ruchelsman DE, Zuckerman JD. Subacromial corticosteroid injections. *J Shoulder Elbow Surg* 2008;17:118S-30S.
- Walsh N, Eckmann M. Injection procedure. In: Frontera W, editor. *Physical medicine and rehabilitation: principles and practice*. 5th ed. Philadelphia: Lippincott Williams & Wilkins; 2010. p 1815-73.
- Frost A, Michael Robinson C. The painful shoulder. *Surgery (Oxford)* 2006;24:363-7.
- Alvarez CM, Litchfield R, Jackowski D, Griffin S, Kirkley A. A prospective, double-blind, randomized clinical trial comparing subacromial injection of betamethasone and xylocaine to xylocaine alone in chronic rotator cuff tendinosis. *Am J Sports Med* 2005;33:255-62.
- Plafki C, Steffen R, Willburger RE, Wittenberg RH. Local anaesthetic injection with and without corticosteroids for subacromial impingement syndrome. *Int Orthop* 2000;24:40-2.
- Eustace JA, Brophy DP, Gibney RP, Bresnihan B, FitzGerald O. Comparison of the accuracy of steroid placement with clinical outcome in patients with shoulder symptoms. *Ann Rheum Dis* 1997;56:59-63.
- Buchbinder R, Green S, Forbes A, Hall S, Lawler G. Arthrographic joint distension with saline and steroid improves function and reduces pain in patients with painful stiff shoulder: results of a randomised, double blind, placebo controlled trial. *Ann Rheum Dis* 2004;63:302-9.
- Krupp RJ, Kevern MA, Gaines MD, Kotara S, Singleton SB. Long head of the biceps tendon pain: differential diagnosis and treatment. *J Orthop Sports Phys Ther* 2009;39:55-70.
- Jain NB, Wilcox RB 3rd, Katz JN, Higgins LD. Clinical examination of the rotator cuff. *PM R* 2013;5:45-56.
- Hong JY, Yoon SH, Moon do J, Kwack KS, Joen B, Lee HY. Comparison of high- and low-dose corticosteroid in subacromial injection for periarticular shoulder disorder: a randomized, triple-blind, placebo-controlled trial. *Arch Phys Med Rehabil* 2011;92:1951-60.
- Faul F, Erdfelder E, Lang AG, Buchner A. G\*Power 3: a flexible statistical power analysis program for the social, behavioral, and biomedical sciences. *Behav Res Methods* 2007;39:175-91.
- van Holsbeeck M, Strouse PJ. Sonography of the shoulder: evaluation of the subacromial-subdeltoid bursa. *AJR Am J Roentgenol* 1993;160:561-4.
- Girish G, Lobo LG, Jacobson JA, Morag Y, Miller B, Jamadar DA. Ultrasound of the shoulder: asymptomatic findings in men. *AJR Am J Roentgenol* 2011;197:W713-9.
- Naredo E, Aguado P, De Miguel E, et al. Painful shoulder: comparison of physical examination and ultrasonographic findings. *Ann Rheum Dis* 2002;61:132-6.
- Bianchi S, Martinoli C. *Ultrasound of the musculoskeletal system*. Berlin: Springer; 2007.
- Tsai YH, Huang TJ, Hsu WH, et al. Detection of subacromial bursa thickening by sonography in shoulder impingement syndrome. *Chang Gung Med J* 2007;30:135-41.

23. Croft P, Pope D, Zonca M, O'Neill T, Silman A. Measurement of shoulder related disability: results of a validation study. *Ann Rheum Dis* 1994;53:525-8.
24. Angst F, Schwyzer HK, Aeschlimann A, Simmen BR, Goldhahn J. Measures of adult shoulder function: Disabilities of the Arm, Shoulder, and Hand Questionnaire (DASH) and its short version (Quick-DASH), Shoulder Pain and Disability Index (SPADI), American Shoulder and Elbow Surgeons (ASES) Society standardized shoulder assessment form, Constant (Murley) Score (CS), Simple Shoulder Test (SST), Oxford Shoulder Score (OSS), Shoulder Disability Questionnaire (SDQ), and Western Ontario Shoulder Instability Index (WOSI). *Arthritis Care Res (Hoboken)* 2011;63(Suppl 11):S174-88.
25. Hirano Y, Sashi R, Izumi J, Itoi E, Watarai J. Comparison of the MR findings on indirect MR arthrography in patients with rotator cuff tears with and without symptoms. *Radiat Med* 2006;24:23-7.
26. Chen MJ, Lew HL, Hsu TC, et al. Ultrasound-guided shoulder injections in the treatment of subacromial bursitis. *Am J Phys Med Rehabil* 2006;85:31-5.
27. Voloshin I, Gelinis J, Maloney MD, O'Keefe RJ, Bigliani LU, Blaine TA. Proinflammatory cytokines and metalloproteinases are expressed in the subacromial bursa in patients with rotator cuff disease. *Arthroscopy* 2005;21:1076.e1-9.
28. Soifer TB, Levy HJ, Soifer FM, Kleinbart F, Vigorita V, Bryk E. Neurohistology of the subacromial space. *Arthroscopy* 1996;12:182-6.
29. Gotoh M, Hamada K, Yamakawa H, Inoue A, Fukuda H. Increased substance P in subacromial bursa and shoulder pain in rotator cuff diseases. *J Orthop Res* 1998;16:618-21.
30. Itoi E, Minagawa H, Yamamoto N, Seki N, Abe H. Are pain location and physical examinations useful in locating a tear site of the rotator cuff? *Am J Sports Med* 2006;34:256-64.
31. Contreras F, Brown HC, Marx RG. Predictors of success of corticosteroid injection for the management of rotator cuff disease. *HSS J* 2013;9:2-5.
32. Bouju Y, Bouilleau L, Dubois de Montmarin G, Bacle G, Favard L. Do subacromial ultrasonography findings predict efficacy of intra-bursal injection? Prospective study in 39 patients. *Orthop Traumatol Surg Res* 2014;100:S361-4.
33. Tauro JC. Stiffness and rotator cuff tears: incidence, arthroscopic findings, and treatment results. *Arthroscopy* 2006;22:581-6.
34. Seo SS, Choi JS, An KC, Kim JH, Kim SB. The factors affecting stiffness occurring with rotator cuff tear. *J Shoulder Elbow Surg* 2012; 21:304-9.
35. Nakama LH, King KB, Abrahamsson S, Rempel DM. Evidence of tendon microtears due to cyclical loading in an in vivo tendinopathy model. *J Orthop Res* 2005;23:1199-205.
36. Ogata S, Uhthoff HK. Acromial enthesopathy and rotator cuff tear. A radiologic and histologic postmortem investigation of the coracoacromial arch. *Clin Orthop Relat Res* 1990;254:39-48.
37. Page P. Shoulder muscle imbalance and subacromial impingement syndrome in overhead athletes. *Int J Sports Phys Ther* 2011;6:51-8.
38. Draghi F, Scudeller L, Draghi AG, Bortolotto C. Prevalence of subacromial-subdeltoid bursitis in shoulder pain: an ultrasonographic study. *J Ultrasound* 2015;18:151-8.