



Eczema within a Capillary Malformation: A Case of Meyerson Phenomenon

Sang Jin Kim, You Chan Kim

Department of Dermatology, Ajou University School of Medicine, Suwon, Korea

Dear Editor:

Meyerson phenomenon, or halo dermatitis, is characterized by the development of a halo or eczematous patch over another skin lesion, such as nevus cell nevus or nevus flammeus¹. We report the case of a 10-month-old female infant who showed eczema within a pre-existing capillary malformation.

The infant presented with irregularly shaped, but relatively well-demarcated erythematous scaly patch on her back (Fig. 1). She showed an erythematous patch on her back at the time of birth. She had no past history and family history of atopic dermatitis or psoriasis of the infant. The current scaly eczematous lesion developed over the pre-existing congenital erythematous lesion 3 months ago without any triggering event. Biopsy of the skin sample obtained from the center of the lesion showed acanthosis with

marked spongiosis in the epidermis and vascular proliferation with perivascular lymphocytic infiltration in the dermis (Fig. 2). She was eventually diagnosed with capillary malformation with overlying eczema. Mometasone furoate lotion was applied, but only slight and temporary improvement was observed after 2 weeks. Since then, the lesion waxed and waned without any other event like dye laser.

The first case report of an inflammatory reaction within a capillary malformation was published in 1996 and described dermatitis within nuchal-occipital port-wine stains². Since then, only few cases of eczema over a capillary malformation corresponding to Meyerson phenomenon have been reported^{1,3,4}. Most patients usually presented with sharply demarcated, scaly, and eczematous lesions confined within the borders of the capillary malformation¹⁻⁴.

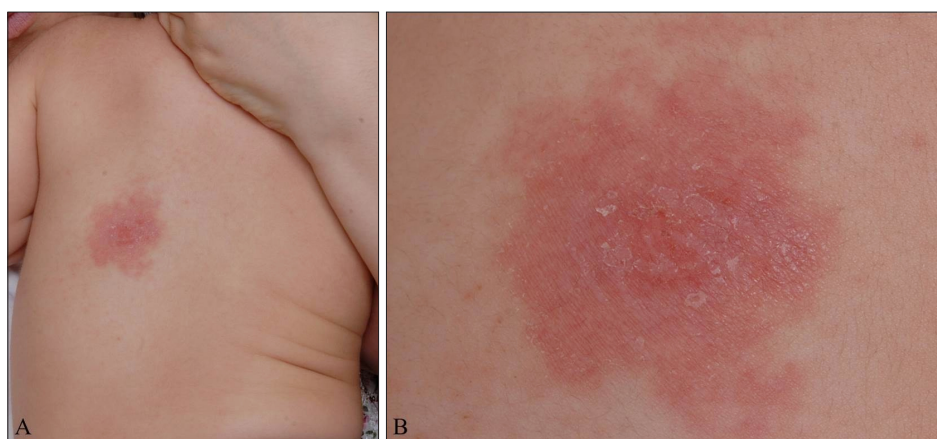


Fig. 1. (A, B) The back skin shows a relatively well-demarcated erythematous and eczematous patch.

Received July 16, 2015, Revised October 15, 2015, Accepted for publication November 3, 2015

Corresponding author: You Chan Kim, Department of Dermatology, Ajou University School of Medicine, 164 WorldCup-ro, Yeongtong-gu, Suwon 16499, Korea. Tel: 82-31-219-5190, Fax: 82-31-219-5189, E-mail: maychan@ajou.ac.kr

This is an Open Access article distributed under the terms of the Creative Commons Attribution Non-Commercial License (<http://creativecommons.org/licenses/by-nc/4.0>) which permits unrestricted non-commercial use, distribution, and reproduction in any medium, provided the original work is properly cited.

Copyright © The Korean Dermatological Association and The Korean Society for Investigative Dermatology

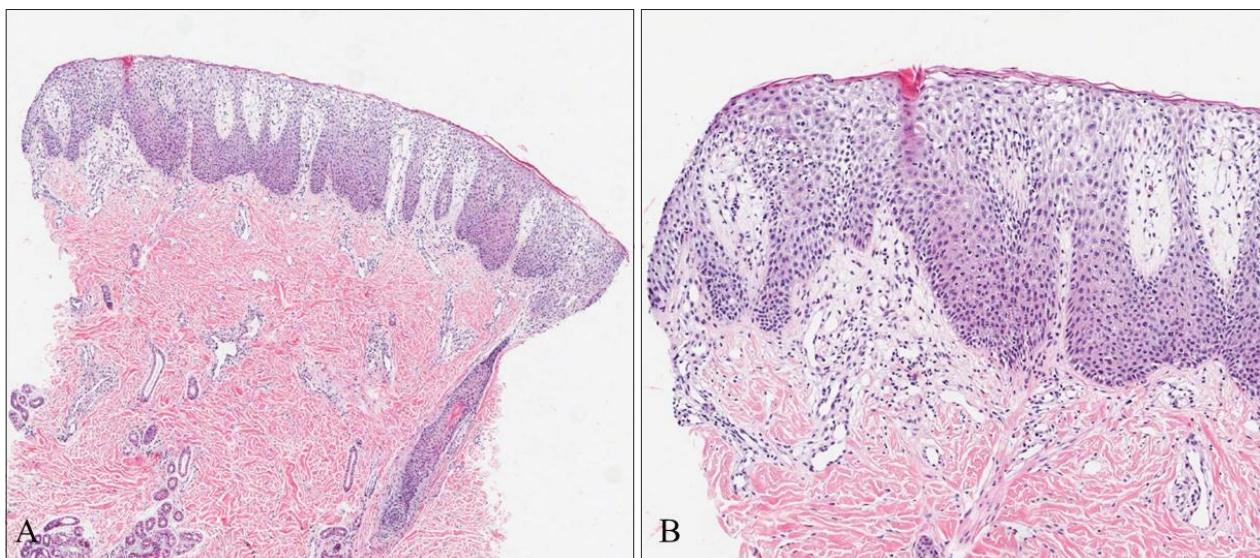


Fig. 2. (A) Skin biopsy showed epidermal hyperplasia and vascular proliferation (H&E, $\times 40$). (B) Marked spongiotic change with exocytosis of lymphocytes in the epidermis and proliferation of capillaries with perivascular lymphocytic infiltration in the upper dermis can be seen (H&E, $\times 100$).

Histological examination showed epidermal hyperplasia and spongiosis overlying capillary ectasias¹. Topical corticosteroid is usually successful for the treatment of eczema, but the lesions tend to recur after treatment discontinuation². Treatment with pulsed dye laser alleviates both capillary malformation and the associated eczema^{1,3}. However, in some patients, eczematous dermatitis was triggered by the laser treatment itself⁴. The pathogenesis of Meyerson phenomenon in the case of capillary malformation remains unclear despite several hypotheses. A hypothesis is that the skin within the capillary malformation shows abnormal dermal vasculature, and this ectatic capillary vessel possibly causes excessive production of proinflammatory cytokines, promoting the development of eczema³. Moreover, endothelial cells possibly play an important role in the inflammatory process³. This hypothesis is supported by the observation that eczema is alleviated by therapy with a dye laser^{1,3}. Reversely, this proinflammatory hypothesis also can be explained in that eczema is triggered by post-laser inflammatory environment⁴. Another theory is that, in terms of nevus flammeus, which are oriented along the lines of Blaschko, this phenomenon is associated with genetic mosaicism. Thus, the microenvironment of the lesions may be different from the microenvironment of the surrounding skin⁴.

In Korean literature, some cases of Meyerson phenomenon were reported; however, the phenomenon was associated with seborrheic keratosis, compound nevus, and junctional nevus, but not capillary malformation⁵. Although Meyerson phenomenon with capillary malformation is not uncommon phenomenon in practice, it seems to be under-reported. Dermatologists should be aware that eczematous lesion could develop over the capillary malformation.

REFERENCES

1. Simon V, Hartschuh W, Flux K. Meyerson-phenomenon hides a nevus flammeus. *J Dtsch Dermatol Ges* 2011; 9:305-307.
2. Tay YK, Morelli J, Weston WL. Inflammatory nuchal-occipital port-wine stains. *J Am Acad Dermatol* 1996; 35:811-813.
3. Sidwell RU, Syed S, Harper JL. Port-wine stains and eczema. *Br J Dermatol* 2001;144:1269-1270.
4. Pavlović MD, Adamič M. Eczema within port wine stain: spontaneous and laser-induced Meyerson phenomenon. *Acta Dermatovenerol Alp Pannonica Adriat* 2014;23:81-83.
5. Kim TH, Lee HS, Park KB. A case of halo dermatitis around seborrheic keratosis. *Ann Dermatol* 1993;5:83-85.