

ORIGINAL ARTICLE

# Totally replaced right hepatic artery in pancreaticoduodenectomy: is this anatomical condition a contraindication to minimally invasive surgery?

Ji Hun Kim<sup>1,2</sup>, Raquel Gonzalez-Heredia<sup>1</sup>, Despoina Daskalaki<sup>1</sup>, Mohammad Rashdan<sup>1</sup>, Mario Masrur<sup>1</sup> & Pier C. Giulianotti<sup>1</sup>

<sup>1</sup>Division of General, Minimally Invasive and Robotic Surgery, Department of Surgery, University of Illinois Hospital and Health Sciences System, Chicago, IL, USA, and <sup>2</sup>Division of Pancreatobiliary Surgery, Department of Surgery, School of Medicine, Ajou University, Suwon, Republic of Korea

## Abstract

**Background:** The appropriate approach, in the case of an aberrant right hepatic artery (RHA) during open pancreaticoduodenectomy (PD), has already been established. The aim of our study is to analyze the short-term surgical and oncological outcomes after robotic PD in patients with anatomical variants, with a special focus on totally replaced RHA.

**Methods:** This study is a retrospective review of a prospectively maintained database collected from consecutive patients who underwent robotic PD at the University of Illinois Hospital and Health Sciences System between September 2007 and April 2015.

**Results:** Fifteen patients (20.5%) presented with an anatomical variation of the RHA. Four patients had an accessory RHA and 11 had a totally replaced RHA. 50% of the cases were recognized by the radiologist preoperatively. There were no significant differences in the pre- and postoperative outcomes of the aberrant and normal RHA group. The mean number of harvested lymph nodes in the totally replaced RHA group was  $22.8 \pm 11.4$ . The rate of positive resection margins was 0% in the totally replaced RHA group and 9% in the normal RHA group.

**Conclusions:** This study suggests that robotic PD has no negative impact on surgical and oncological outcomes in patients with a totally replaced RHA.

Received 9 March 2016; accepted 22 April 2016

## Correspondence

Pier C. Giulianotti, Division of General, Minimally Invasive and Robotic Surgery, University of Illinois Hospital and Health Sciences System, 840 S Wood MC 958 Room 435 E, Chicago, IL 60612, USA. Fax: +1 312 355 1987. E-mail: [piercg@uic.edu](mailto:piercg@uic.edu)

## Introduction

As surgical techniques and postoperative care have both advanced over the past decades, the mortality rate after pancreaticoduodenectomy (PD) has decreased to less than 5% at high-volume centers. However, the morbidity rate still remains high (ranging from 30 to 40%).<sup>1</sup> Anatomic variations of the hepatic artery might lead to increased postoperative morbidity, such as bleeding, ischemia or stenosis of the biliary anastomosis, as well as hepatic abscess and hepatic infarction.<sup>2</sup> The incidence of variation of the hepatic artery described in the literature varies from 55 to 79%.<sup>3,4</sup> A replaced right hepatic artery (RHA) arising from the superior mesenteric artery (SMA) is a common variant,

occurring in 9–24% of patients.<sup>3,5,6</sup> The importance of preserving the RHA during PD has already been reported in several publications.<sup>2,7</sup>

Minimally invasive surgery (MIS) for pancreatic disease is safe and feasible.<sup>8–10</sup> Robotic surgery has been introduced to overcome the limitations of laparoscopy, and has proved to be as safe as the open surgical approach.<sup>11–13</sup> To our knowledge, there has only been one report on robotic PD in the presence of an aberrant right hepatic artery.<sup>14</sup> Most studies reporting variations of the RHA during PD have been described for open surgery and showed data including both accessory and replaced right hepatic artery.<sup>5–7</sup> The aim of our study is to analyze the short-term surgical and oncological outcomes after robotic PD in patients

with anatomical variants, with a special focus on totally replaced right hepatic artery, and compare them to patients with normal anatomy.

## Materials and methods

This study is a single center, retrospective review of a prospectively maintained database as part of standard care. Data was collected from consecutive patients who underwent robotic pancreaticoduodenectomy (PD), by a single surgeon, at the University of Illinois Hospital and Health Sciences System between September 2007 and April 2015. This study was conducted with Institutional Review Board approval.

Inclusion criteria consisted of all patients, age 18 and older, who underwent a robotic PD. Exclusion criteria were the following: age under 18, patients lost in the follow up period, patients who underwent pancreatic islets transplantation at the time of the PD and one patient who had undergone a distal pancreatectomy prior the PD. Patients were divided into two groups, one based on the presence of a vascular anomaly and the other without. Furthermore, we analyzed patients with totally replaced RHA group. The following variables were obtained from the electronic medical records (EMR): patients' demographics, medical comorbidities, pathology reports, intraoperative findings and postoperative outcomes. For the analysis of complications related to an aberrant RHA, we evaluated the liver function tests, obtained on postoperative day 7, and presence of liver abscess from the abdominal CT scan obtained at the 3 month follow up. Our operative technique for robotic PD has been previously described.<sup>11</sup>

Data analyses were conducted using SPSS 22.0 (IBM, SPSS Statistics). Comparisons were performed between the groups using the student T-test for continuous variables, while chi-square tests were performed for categorical variables. For non-parametric variables, the Mann–Whitney U test was used. Confidence intervals were set at 95% and a two-sided P value of <0.05 was considered statistically significant.

## Results

Seventy-three patients underwent robotic pancreaticoduodenectomy (RPD), of which 15 (20.5%) had an anomaly of RHA. 50% of the cases were recognized by the radiologist preoperatively. On the other 50% the anomaly was detected intraoperatively during the surgical dissection. In all instances an attempt of preserving the aberrant artery was performed. The clinical characteristics of the two groups are found in Table 1. There were no significant differences between the two groups regarding the preoperative outcomes. Table 2 shows the final pathologic diagnosis. The most common indication for resection was pancreatic adenocarcinoma (32.9%). There were three cases of conversion to open in the aberrant RHA group. Reasons for conversion included a subcutaneous emphysema in two cases

and cancer encasement in the other (Table 3). The mean operative time was  $443.7 \pm 50.1$  and  $463.6 \pm 105.2$  min in the aberrant and normal RHA group, respectively ( $P > 0.05$ ). The mean estimated blood loss was higher in the aberrant RHA group ( $545.8 \pm 729.0$  ml vs  $310.1 \pm 267.6$  ml), however, there was no significant difference ( $P > 0.05$ ). Out of 15 patients with the anomaly of RHA, 11 had a totally replaced RHA and 4 had an accessory RHA. Of the four patients with an accessory RHA, in

**Table 1** Clinical characteristics

	Aberrant RHA group (n = 15)	Normal RHA group (n = 58)	P value
Age (year)	$61.0 \pm 12.4$	$60.9 \pm 13.4$	>0.05
Gender			>0.05
Male	6	29	
Female	9	29	
BMI	$29.1 \pm 3.9$	$26.5 \pm 5.3$	>0.05
ASA			>0.05
1	0	2	
2	5	30	
3	9	25	
4	1	0	
Diabetes mellitus			>0.05
No	9	46	
Yes	6	12	
Previous history of surgery			>0.05
No	11	40	
Yes	4	18	
Pathology			>0.05
Benign	3	19	
Malignant	12	39	

BMI, body mass index; ASA, american society of anesthesiologists.

**Table 2** Diagnosis

Final pathology	Patients (n = 73)
Pancreatic adenocarcinoma	24
Ampullary carcinoma	10
Intraductal papillary mucinous neoplasm	9
Neuroendocrine tumor	6
Duodenal adenoma	3
Gallbladder carcinoma	3
Solid pseudopapillary neoplasm	1
Common bile duct carcinoma	1
Pancreas cystic lesion	1
Duodenal carcinoma	1
Choledochal cyst	1
Benign diseases	13

two cases the artery had to be sacrificed in order to obtain a clear resection margin. One of the two patients presented with elevated liver enzymes two days after surgery, however, they were later normalized without any complication. Inadvertent ligation of an aberrant RHA never occurred in our cohort. Liver function, tested on postoperative day 7, showed no significant differences between the two groups ( $P > 0.05$ ). There was no liver abscess or biliary stricture in any of the patients during the study period. There were also no significant differences in the rate of pancreatic

fistula, or other complications, length of hospital stay and mortality between the two groups (Table 3).

Out of the 15 patients who had an aberrant RHA, 11 (73.3%) had a totally replaced RHA. In all 11 cases the totally replaced RHA was successfully preserved. Patients were divided into two groups: normal RHA and totally replaced RHA. The mean operative time and estimated blood loss were  $433.0 \pm 56.8$  min and  $643.7 \pm 891.8$  ml in the totally replaced RHA group, and  $463.6 \pm 105.2$  min and  $310.1 \pm 267.6$  ml in the normal RHA group, respectively (Table 4). There were no significant differences among the groups regarding operative time, estimated blood loss and need for intraoperative blood transfusion. There was also no significant difference regarding pancreatic fistula and postoperative complication rates. One patient in the totally replaced RHA group developed bleeding, secondary to pancreatic fistula formation. There was no bleeding or pseudoaneurysm from the variant of the RHA. Liver function tests, obtained on postoperative day 7, in the totally replaced RHA group did not differ from those of the normal RHA group ( $P > 0.05$ ) (Fig. 1a). Bile leakage occurred in one patient in the normal RHA group. There was no bile leakage in the totally replaced RHA group (Fig. 1b).

Fifty-one patients (69.8%) underwent surgery for malignant disease. Among these patients, 12 had a vascular anomaly (4 cases of accessory and 8 cases of a totally replaced RHA). The mean number of harvested lymph nodes in the totally replaced RHA group was  $22.8 \pm 11.4$ , slightly higher than that of normal RHA group ( $20.7 \pm 11.5$ ), but not statistically significant ( $P > 0.05$ ) (Fig. 2a). The rate of positive resection margin was 0% in patients with a totally replaced RHA and 9% in the normal RHA group, but this difference did not reach statistical significance ( $P > 0.05$ ) (Fig. 2b).

**Table 3** Surgical outcomes after robotic PD

	Aberrant RHA group (n = 15)	Normal RHA group (n = 58)	P value
Conversion to open			>0.05
Subcutaneous emphysema	2		
Cancer encasing aRHA	1		
Friable tissue		1	
Bleeding		1	
Severe adhesion of bowel		1	
Other		1	
Operation time (min) <sup>a</sup>	443.7 ± 50.1	463.6 ± 105.2	>0.05
Estimated blood loss (ml) <sup>a</sup>	545.8 ± 729.0	310.1 ± 267.6	>0.05
Transfusion <sup>a</sup>			>0.05
No	7	45	
Yes	5	9	
Liver function test (POD#7) <sup>a</sup>			>0.05
Bilirubin	0.8 ± 0.2	1.1 ± 1.5	
AST	29.8 ± 17.4	31.2 ± 16.8	
ALT	35.4 ± 39.3	41.0 ± 44.4	
Complications <sup>a</sup>			>0.05
No	7	25	
Yes	5	29	
Pancreatic fistula <sup>a</sup>	2	11	>0.05
Grade A	0	6	
Grade B	1	4	
Grade C	1	1	
Bile leakage <sup>a</sup>	0	1	>0.05
Postoperative bleeding <sup>a</sup>	1	5	>0.05
Reoperation <sup>a</sup>	2	4	>0.05
Length of hospital stay (day) <sup>a</sup>	12.7 ± 9.3	13.3 ± 6.9	>0.05
Mortality <sup>a</sup>	0	2	>0.05

POD, postoperative day; AST, aspartate aminotransaminase; ALT, alanine aminotransferase.

<sup>a</sup> Excluding conversion to open.

## Discussion

A totally replaced RHA coming from the SMA is a significant vessel to be preserved during PD since it is one of the main vessels supplying the hepatobiliary system. When an aberrant RHA is encased by cancer, the vessel must be resected with the mass to obtain a safe oncologic margin. Small caliber accessory RHAs can be safely ligated, however a totally replaced RHA must be reconstructed.<sup>15,16</sup> To date, all studies focusing on aberrant RHA during PD have included data for both accessory and totally replaced RHA. To our knowledge, this is the first study focused on outcomes of PD in the presence of a totally replaced RHA.

Severe complications may be attributed to an unexpected vascular injury during PD in the presence of an anatomical variation of RHA. Potential complications following the intraoperative injury of an aberrant RHA include bleeding, bile leakage and liver abscess.<sup>2,17</sup> Excessive manipulation of the aberrant RHA, in order to preserve it during PD, can increase the risk of pseudoaneurysm or thrombosis of the aberrant vessels.<sup>6,18</sup> Some authors reported cases of aberrant vessels that were

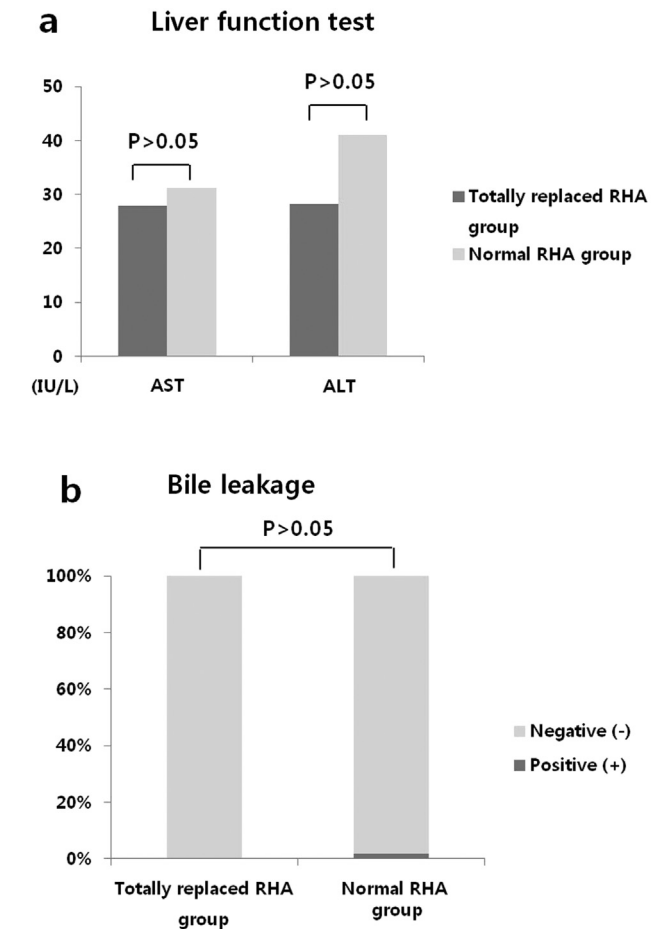
**Table 4** Surgical outcomes after robotic PD in totally replaced RHA group

	Totally replaced RHA group (n = 11)	Normal RHA group (n = 58)	P value
Conversion to open			>0.05
Subcutaneous emphysema	2		
Cancer encasing aRHA	1		
Friable tissue		1	
Bleeding		1	
Severe adhesion of bowel		1	
Other		1	
Liver abscess <sup>a</sup>	0	0	>0.05
Operation time (min) <sup>a</sup>	433.0 ± 56.8	463.6 ± 105.2	>0.05
Estimated blood loss (ml) <sup>a</sup>	643.7 ± 891.8	310.1 ± 267.6	>0.05
Transfusion <sup>a</sup>			>0.05
No	5	45	
Yes	3	9	
Complications <sup>a</sup>			>0.05
No	5	25	
Yes	3	29	
Pancreatic fistula <sup>a</sup>	1	11	>0.05
Grade A	0	6	
Grade B	1	4	
Grade C	0	1	
Postoperative bleeding <sup>a</sup>	1	5	>0.05
Reoperation <sup>a</sup>	1	4	>0.05
Length of hospital stay (day) <sup>a</sup>	10.3 ± 4.6	13.3 ± 6.9	>0.05
Mortality <sup>a</sup>	0	2	>0.05

<sup>a</sup> Excluding conversion to open.

accidentally damaged or ligated. Nevertheless, there were no biliary and hepatic complications.<sup>5,6,18</sup> Recently, Nguyen *et al.*<sup>14</sup> reported their experience with robotic PD in the presence of an aberrant or anomalous hepatic artery anatomy. They demonstrated that all aberrant RHAs were preserved without any vascular injury, and there were no cases of liver abscess, bile leakage or biliary stricture. In our study, no bile leakage was reported in the aberrant RHA group of patients. In addition, there were no other hepatic or biliary complications.

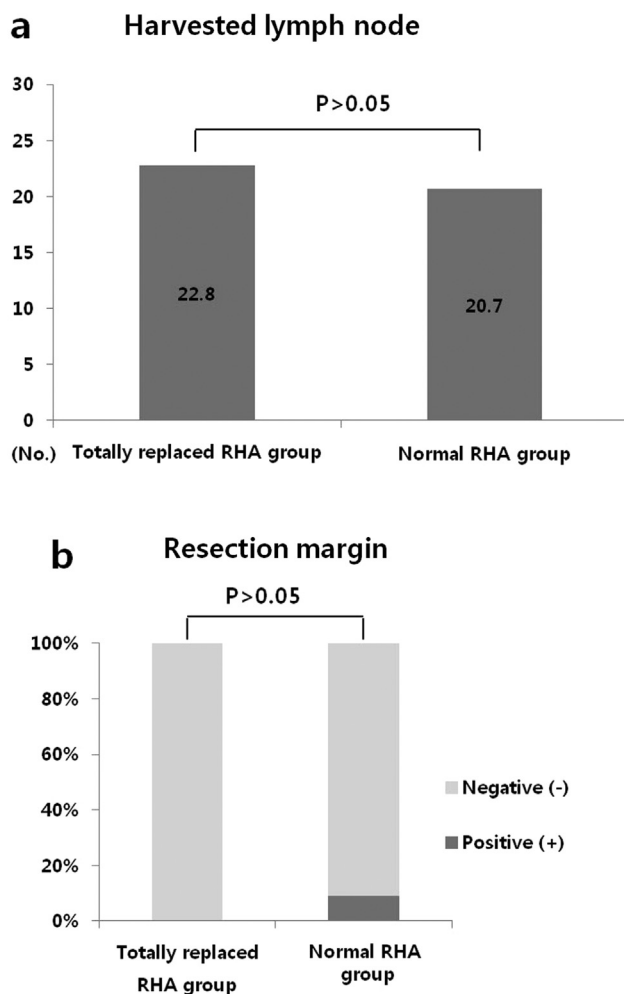
Operative time and blood loss do not significantly increase in patients with an aberrant RHA during PD. Jah *et al.*<sup>19</sup> described that although there was a trend towards an increased operative time and blood loss in these patients, there was no significant



**Figure 1** Complications related to the totally replaced RHA in robotic PD. **a.** Liver function test on the 7th postoperative day. The mean AST and ALT were 27.8 ± 110.7 IU/L and 28.2 ± 15.1 IU/L in the totally replaced RHA group, 31.2 ± 16.8 IU/L and 41.0 ± 44.4 IU/L in the normal RHA group. There was no significant difference between the two groups (P > 0.05). **b.** Bile leakage. There was one case in the normal RHA group. It was not statistically significant between the two groups (P > 0.05). AST, aspartate aminotransaminase; ALT, alanine aminotransferase.

difference. In a recent study for robotic PD in the presence of aberrant RHA, the mean operative time and blood loss was 501 min and 250 ml, without any conversion to open.<sup>14</sup> In our study, the operative time in the aberrant RHA group was acceptable. However, the blood loss in the totally replaced RHA group was higher, even though it was not statistically significant. It is possible that the reason for this might be attributed to a case of extensive intraoperative bleeding in a patient with liver cirrhosis.

Based on several studies, the presence of an aberrant RHA during PD does not affect the rate of R1 resection.<sup>5,20</sup> Some authors suggest that a replaced RHA adjacent to the tumor should be divided in order to obtain R0 resection in open PD.<sup>21</sup>



**Figure 2** Oncological outcomes after robotic PD for malignancy. **a.** Harvested lymph node. The mean number of harvested lymph nodes was  $22.8 \pm 11.4$  and  $20.7 \pm 11.5$  in the totally replaced RHA and normal RHA group. It was not statistically significant ( $P > 0.05$ ). **b.** Status of resection margin. The rates of positive resection margin were 0% and 9% in the totally replaced RHA and normal RHA group. It was not statistically significant ( $P > 0.05$ ).

We experienced one case that was converted to open because the totally replaced RHA was encased by a tumor. In a recent study, the authors described that the rate of R1 was 7.4% and the mean harvested LNs were 22.3 in patients with an aberrant RHA.<sup>14</sup> In our study, the rate of R0 resection in the totally replaced RHA group was 100%. The mean number of harvested LNs was 22.8, in case of malignancy, which is in accordance with current literature. Anatomical variations could negatively influence radical LN dissection during PD, and even affect recurrence and survival.<sup>22</sup> In open PD, many studies report that the presence of an aberrant RHA does not compromise postoperative outcomes or survival.<sup>6,23,24</sup> Unfortunately, there are no reports on survival

after robotic PD in the presence of an aberrant RHA in the current literature.

Preoperative recognition of aberrant RHAs by radiologists has been associated with decreasing complications by avoiding the vascular injury after confirming the location and course of it.<sup>18</sup> However, the rates of identification of aberrant RHAs by radiologists have been reported in 29–69% of patients.<sup>5,24</sup> Most studies used an abdominal CT scan as a preoperative imaging study. Some authors recommend routine use of angiography to identify a vascular anomaly before surgery.<sup>25</sup> In our study, the rate of preoperative recognition by radiologists was 50%, similar with that of others. We do not routinely use preoperative angiography. Moreover, there were no biliary complications in the aberrant RHA group. Our data suggests that an experienced robotic surgeon can detect and avoid injury to the aberrant RHA during surgery, even if there is no preoperative information indicating a vascular anomaly in the imaging. Surgeons can suspect the presence of an aberrant right hepatic artery when the thickness of the tissue on the right side of the portal vein is increased or the size of the common hepatic artery is decreased. In such cases, the surgeon should dissect carefully in order to avoid vascular damage.

Our data shows that robotic PD in the presence of a totally replaced RHA was not associated with increased postoperative complications, R1 resection rate and a lower number of harvested LNs. This study has some limitations, such as being a short-term retrospective study with a small number of cases. However, we believe that this study emphasizes the advantages of robotic procedures based on the 3D magnified vision and articulated instruments that allow for meticulous dissection and more precise hemostasis, even in complex cases with vascular anomaly during PD. In conclusion, a RHA variant during PD can be successfully managed with the robotic approach with similar morbidity and oncological completeness. Therefore, this anatomical condition is not a contraindication for a minimally invasive approach.

#### Acknowledgments

Dr. Giulianotti is a consultant for Covidien LP and Ethicon, Inc.; he has a proctoring agreement and Grant support as Chief of the Division.

#### Conflicts of interest

None of the authors have any conflicts of interest.

#### References

1. Winter JM, Cameron JL, Campbell KA, Arnold MA, Chang DC, Coleman J *et al.* (2006) 1423 pancreaticoduodenectomies for pancreatic cancer: a single-institution experience. *J Gastrointest Surg* 10: 1199–1210. Discussion 210–211.
2. Traverso LW, Freney PC. (1989) Pancreaticoduodenectomy. The importance of preserving hepatic blood flow to prevent biliary fistula. *Am Surg* 55:421–426.
3. Hiatt JR, Gabbay J, Busuttill RW. (1994) Surgical anatomy of the hepatic arteries in 1000 cases. *Ann Surg* 220:50–52.

4. Michels NA. (1962) The anatomic variations of the arterial pancreaticoduodenal arcades: their import in regional resection involving the gall bladder, bile ducts, liver, pancreas and parts of the small and large intestines. *J Int Coll Surg* 37:13–40.
5. Turrini O, Wiebke EA, Delperio JR, Viret F, Lillemoe KD, Schmidt CM. (2010) Preservation of replaced or accessory right hepatic artery during pancreaticoduodenectomy for adenocarcinoma: impact on margin status and survival. *J Gastrointest Surg* 14:1813–1819.
6. Eshuis WJ, Olde Loohuis KM, Busch OR, van Gulik TM, Gouma DJ. (2011) Influence of aberrant right hepatic artery on perioperative course and longterm survival after pancreaticoduodenectomy. *HPB* 13: 161–167.
7. Shukla PJ, Barreto SG, Kulkarni A, Nagarajan G, Fingerhut A. (2010) Vascular anomalies encountered during pancreaticoduodenectomy: do they influence outcomes? *Ann Surg Oncol* 17:186–193.
8. Gumbs AA, Rodriguez Rivera AM, Milone L, Hoffman JP. (2011) Laparoscopic pancreaticoduodenectomy: a review of 285 published cases. *Ann Surg Oncol* 18:1335–1341.
9. Asbun HJ, Stauffer JA. (2012) Laparoscopic vs open pancreaticoduodenectomy: overall outcomes and severity of complications using the Accordion Severity Grading System. *J Am Coll Surg* 215:810–819.
10. Kendrick ML. (2012) Laparoscopic and robotic resection for pancreatic cancer. *Cancer J* 18:571–576.
11. Giulianotti PC, Sbrana F, Bianco FM, Elli EF, Shah G, Addeo P *et al.* (2010) Robot-assisted laparoscopic pancreatic surgery: single-surgeon experience. *Surg Endosc* 24:1646–1657.
12. Buchs NC, Addeo P, Bianco FM, Ayloo S, Benedetti E, Giulianotti PC. (2011) Robotic versus open pancreaticoduodenectomy: a comparative study at a single institution. *World J Surg* 35:2739–2746.
13. Zureikat AH, Moser AJ, Boone BA, Bartlett DL, Zenati M, Zeh, HJ, 3rd. (2013) 250 robotic pancreatic resections: safety and feasibility. *Ann Surg* 258:554–559. Discussion 9–62.
14. Nguyen TK, Zenati MS, Boone BA, Steve J, Hogg ME, Bartlett DL *et al.* (2015) Robotic pancreaticoduodenectomy in the presence of aberrant or anomalous hepatic arterial anatomy: safety and oncologic outcomes. *HPB* 17:594–599.
15. Yang SH, Yin YH, Jang JY, Lee SE, Chung JW, Suh KS *et al.* (2007) Assessment of hepatic arterial anatomy in keeping with preservation of the vasculature while performing pancreaticoduodenectomy: an opinion. *World J Surg* 31:2384–2391.
16. Allendorf JD, Bellemare S. (2009) Reconstruction of the replaced right hepatic artery at the time of pancreaticoduodenectomy. *J Gastrointest Surg* 13:555–557.
17. Woods MS, Traverso LW. (1993) Sparing a replaced common hepatic artery during pancreaticoduodenectomy. *Am Surg* 59:719–721.
18. Stauffer JA, Bridges MD, Turan N, Nguyen JH, Martin JK. (2009) Aberrant right hepatic arterial anatomy and pancreaticoduodenectomy: recognition, prevalence and management. *HPB* 11: 161–165.
19. Jah A, Jamieson N, Huguet E, Praseedom R. (2009) The implications of the presence of an aberrant right hepatic artery in patients undergoing a pancreaticoduodenectomy. *Surg Today* 39:669–674.
20. Kim PT, Temple S, Atenafu EG, Cleary SP, Moulton CA, McGilvray ID *et al.* (2014) Aberrant right hepatic artery in pancreaticoduodenectomy for adenocarcinoma: impact on resectability and postoperative outcomes. *HPB* 16:204–211.
21. Okada K, Kawai M, Hirono S, Miyazawa M, Shimizu A, Kitahata Y *et al.* (2015) A replaced right hepatic artery adjacent to pancreatic carcinoma should be divided to obtain R0 resection in pancreaticoduodenectomy. *Langenbecks Arch Surg* 400:57–65.
22. Yeo CJ, Cameron JL, Sohn TA, Coleman J, Sauter PK, Hruban RH *et al.* (1999) Pancreaticoduodenectomy with or without extended retroperitoneal lymphadenectomy for periampullary adenocarcinoma: comparison of morbidity and mortality and short-term outcome. *Ann Surg* 229: 613–622. Discussion 22–4.
23. Lee JM, Lee YJ, Kim CW, Moon KM, Kim MW. (2009) Clinical implications of an aberrant right hepatic artery in patients undergoing pancreaticoduodenectomy. *World J Surg* 33:1727–1732.
24. Sulpice L, Rayar M, Paquet C, Bergeat D, Merdrignac A, Cunin D *et al.* (2013) Does an aberrant right hepatic artery really influence the short- and long-term results of a pancreaticoduodenectomy for malignant disease? A matched case-controlled study. *J Surg Res* 185: 620–625.
25. Biehl TR, Traverso LW, Hauptmann E, Ryan, JA, Jr.. (1993) Preoperative visceral angiography alters intraoperative strategy during the Whipple procedure. *Am J Surg* 165:607–612.