



Prosthetic reconstruction with an obturator using swing-lock attachment for a patient underwent maxillectomy: A clinical report

Dong-Jae Seong^{1a}, Seoung-Jin Hong^{2a}, Seung-Ryong Ha^{1*}, Young-Gi Hong¹, Hyo-Won Kim¹

¹Department of Dentistry, Ajou University School of Medicine, Suwon, Republic of Korea

²Department of Prosthodontics, Graduate School, Kyung Hee University, Seoul, Republic of Korea

Patients who underwent resection of maxilla due to benign or malignant tumor, or accident will have defect in palatal area. They get retention, support and stability from remaining tissues which are hardly optimal. The advantage of swing-lock attachment design is having multiple contacts on labial and lingual side of the abutment teeth by retentive strut and palatal bracing component. Because the force is distributed equally to abutment teeth, abutment teeth of poor prognosis can be benefited from it. It is also more advantageous to cover soft tissue defects which are hard to reach with conventional prosthesis. A 56-year-old female patient who had undergone a maxillectomy due to malignant melanoma complaining of loose and unstable surgical obturator. Surveyed crowns were placed on #12, 26, and 27. Teeth #11, 21, 22, and 23 had lingual rest seat and #24 had mesial rest seat to improve stability and support of the obturator. This clinical report presents the prosthetic management of a patient treated with obturator on the maxilla using swing-lock attachment to the remaining teeth. [*J Adv Prosthodont* 2016;8:411-6]

KEYWORDS: Palatal obturators; Denture precision attachment; Melanoma

INTRODUCTION

Patients who underwent maxillectomy due to benign or malignant tumor, will have defect in palatal area. Because of this defect, patients will be more likely to have oro-nasal communication, change of facial profile, difficulty in speaking, mastication, and even deglutition. To overcome these problems, surgical intervention or prosthetic treatments are used. Often, surgical reconstruction is very difficult to achieve when the defect area is large. When that happens, the treatment choice is limited to prosthetic rehabilitation. When

treating these patients with prosthetic means, several factors should be considered; the size and location of the defect, accessibility, degree of jaw opening, and the condition of oral tissue after radiation therapy. The factors affecting general treatment planning are the age of the patients, presence of any systemic factors, prognosis of the tumor itself, esthetic and functional expectations of the patient along with the motivation.

In the course of the treatment of the disease, much of the oral tissues must be surgically removed. When it happens, surgical reconstruction or implants placement becomes prohibitive and removable prosthesis becomes only remaining option to cover large defects.

Aramany categorized the defect areas after maxillectomy into six classes based on the relationship of the defect to the remaining abutment teeth.¹

Class I: The resection is performed along the midline of the maxilla, teeth are maintained on one side of the arch.

Class II: The defect is unilateral, retaining the anterior teeth on the contralateral side.

Class III: The palatal defect occurring on the central portion of the hard palate and may involve part of the soft palate. The dentition is preserved.

Class IV: The defect crosses the midline and involves

Corresponding author:

Seung-Ryong Ha

Department of Dentistry, Ajou University School of Medicine,
164 Worldcup-ro, Yeongtong-gu, Suwon 16499, Republic of Korea
Tel. 82312195869; e-mail, dragon_001@hanmail.net
Received January 29, 2016 / Last Revision July 20, 2016 / Accepted
August 8, 2016

© 2016 The Korean Academy of Prosthodontics

This is an Open Access article distributed under the terms of the Creative Commons Attribution Non-Commercial License (<http://creativecommons.org/licenses/by-nc/3.0>) which permits unrestricted non-commercial use, distribution, and reproduction in any medium, provided the original work is properly cited.

^a These authors contributed equally to this work.

both sides of the maxilla. Few teeth remain on one side.

Class V: The surgical defect is bilateral and lies posterior to the remaining abutment teeth.

Class VI: Anterior maxillary defect with abutment teeth present bilaterally in the posterior segment.

Removable prosthesis gets retention, support and resistance mainly through anatomical structures such as teeth, alveolar bones and palate. When surgical intervention removes much of these structures, remaining tissue becomes too vulnerable to support the necessary prosthesis. The prognosis for prosthesis becomes worse for Class IV defect which has too few remaining teeth or for Class I defect which has disadvantages in retention, support or resistance.^{2,3} Therefore, considerations should be given to attain extra retention, support and resistance when planning for obturators of maxillary defects.

Swing-lock attachment design uses vertical retentive strut and palatal bracing component, making many labial and lingual contacts. It enables the prosthesis to have extra retention, support and resistance.⁴⁻⁶

In this case, Aramany Class II defect was restored. If conventional partial denture were to be used, the prognosis of the abutment teeth would be uncertain. To distribute the load to many healthy abutment teeth while getting a rigid closure, swing-lock design framework was used to fabricate obturator closing palate-maxillary defect.

CLINICAL PRESENTATION

A 56-year-old female patient had malignant melanoma removed at Ajou University Medical Center in 2014. Surgical obturator was made prior to the surgery appointment. Definitive obturator was to be made one year after the surgery. Patient complained that the surgical obturator was too loose and not stable. There were no systemic factors that would become problematic for obturator use. The results of radiographic examination did not reveal anything specific except missing tooth number #37 in the mandible. It did not bother the patient and she did not want any treatment for it. Tooth number #12 had grade I mobility and distal bone loss due to the long use of surgical obturator. #26 and #27 were restored with gold crowns (Fig. 1, Fig. 2, Fig. 3).

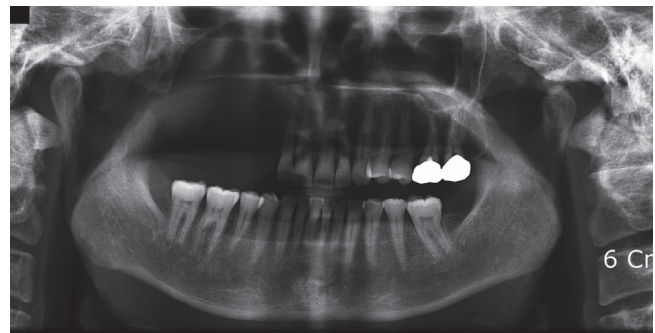


Fig. 1. Panoramic view.

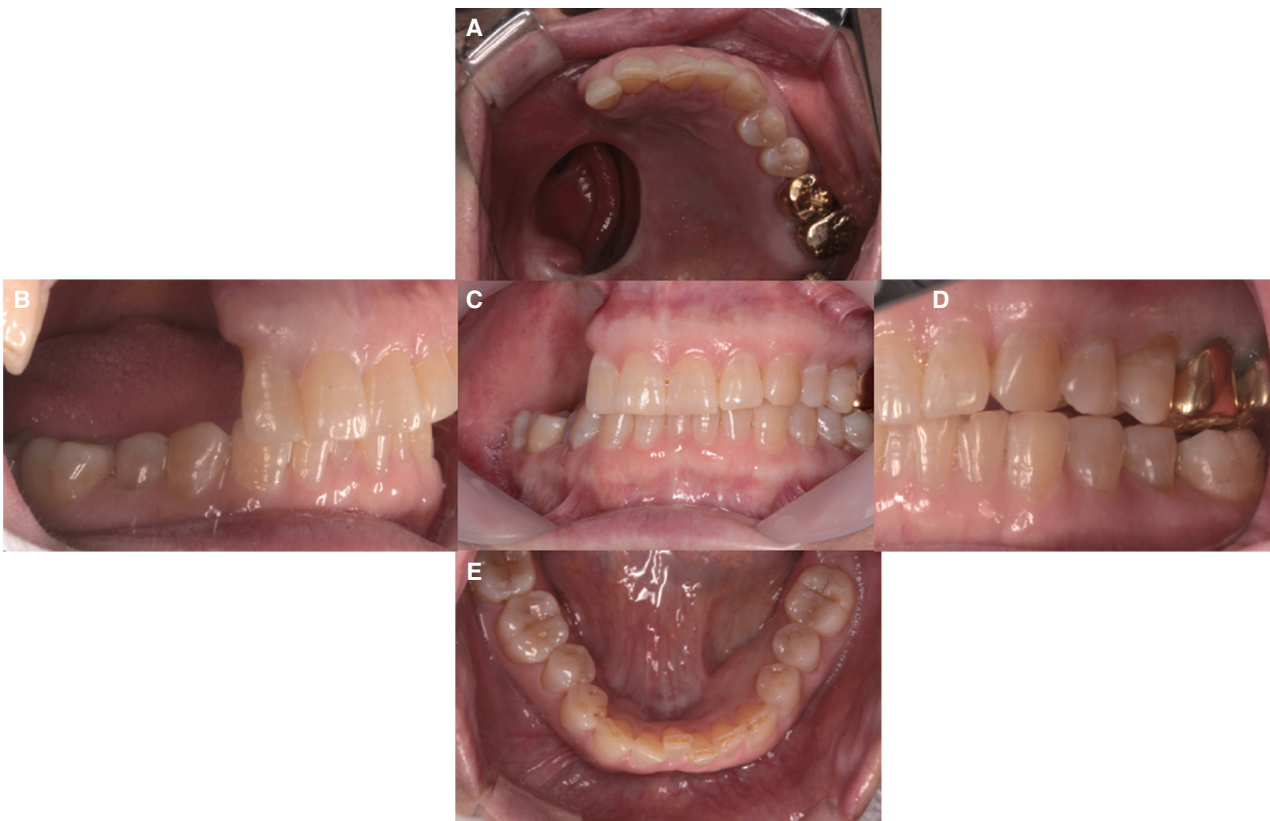


Fig. 2. Intraoral Photos. (A) Maxillary occlusal, (B) Right, (C) Frontal, (D) Left, (E) Mandibular occlusal view.

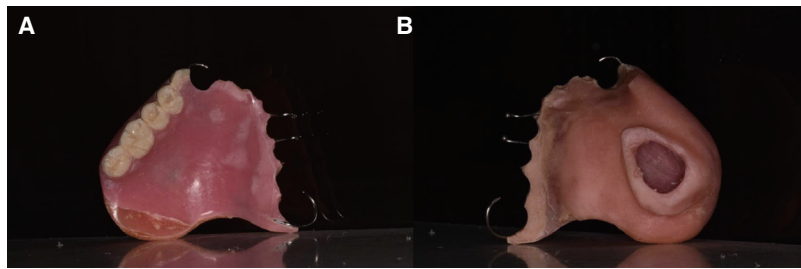


Fig. 3. Surgical obturator. (A) Occlusal surface, (B) Intaglio surface.

This patient who went through maxillectomy has overall sound teeth alignment and periodontal health except the mobility of #12 due to the bone loss and tissue undercut. Conventional removable partial denture design deemed unreliable to achieve adequate retention, support and seal. Proper hybrid gate framework design with swing-lock attachment on #12 as a removable splint would bring more retention to the remaining teeth. Also, post-operative tissue undercut superior to distal of #12 would bring more advantageous path of insertion. Patient used surgical obturator for a year and is used to it. The goals for the new obturator were to enhance the retention and stability and to better fit the palatal closure so that patient can speak better as well. Disadvantages of swing-lock attachment are that it is unaesthetic and it can't be used when labial vestibule is

shallow. The patient in this case had a lower lip line, showing less than 75% of the central incisors when smiling.

Diagnostic cast was made by alginate impression (Aroma Fine DF II, GC, Tokyo, Japan) (Fig. 4).

Locations of each strut were confirmed by surveying. #26 and 27 received new surveyed gold crowns. #12 also received new surveyed crown to form an exact stop. Teeth #11, 21, 22, and 23 had lingual rest seat and #24 had mesial rest seat to improve stability and support of the obturator (Fig. 5).

Individual tray was fabricated. Border molding was done by modeling compound in the same way as conventional partial denture fabrication. Impression was taken by silicone impression material (Express light and regular body, 3M ESPE, St. Paul, MN, USA) (Fig. 6).

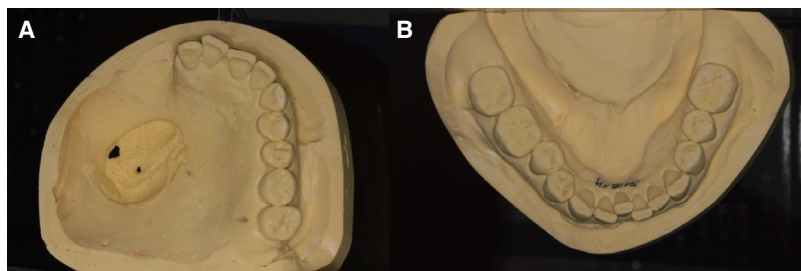


Fig. 4. Diagnostic cast. (A) Maxillary arch, (B) Mandibular arch.

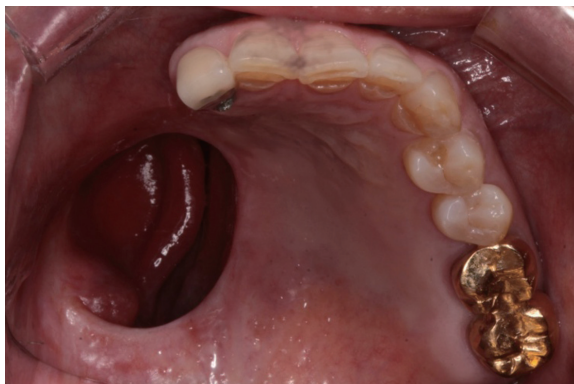


Fig. 5. Surveyed crown with rest seat prepared.

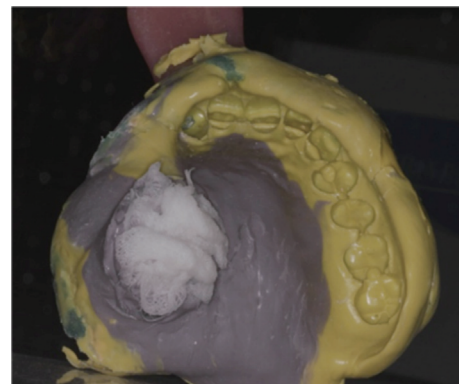


Fig. 6. Border molding and functional impression taking.

Swing-lock design framework was made after fabrication of master cast. Strut fit, hinge and lock-latch function and play was checked. Wax rim was made (Fig. 7).

Framework and wax rim was tried in the mouth. Vertical stop was maintained by residual teeth. No vertical change was made and face-bow was transferred (Fig. 8).

Acrylic teeth were set on the semi-adjustable articulator

(KaVo PROTAR Evo 7, KaVo, Biberach, Germany) (Fig. 9).

Wax denture try-in was done in the mouth. Fit, esthetics, retention, stability and support were evaluated finally. Obturator was fabricated by boiling out. Occlusal adjustment done in the mouth (Fig. 10).

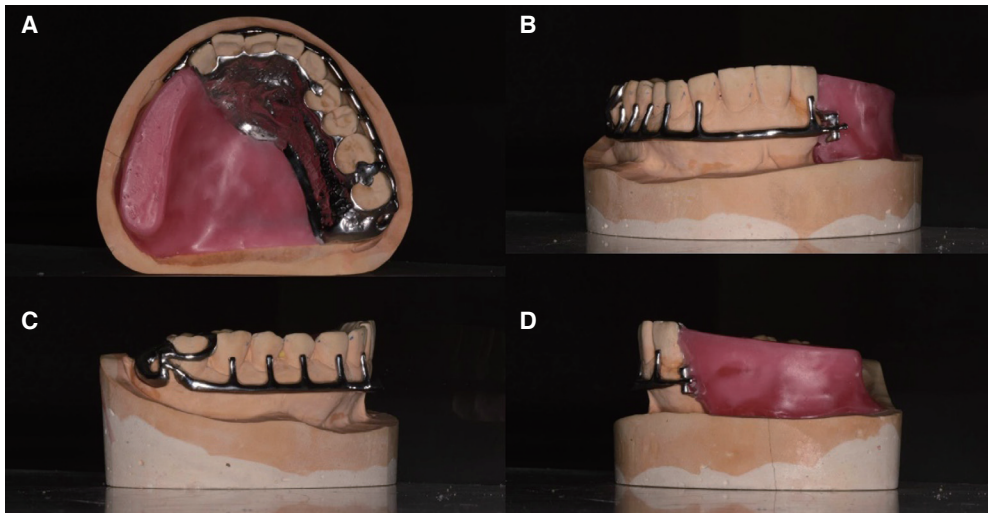


Fig. 7. Framework and wax rim made. (A) Occlusal, (B) Labial, (C) Left, (D) Right side.

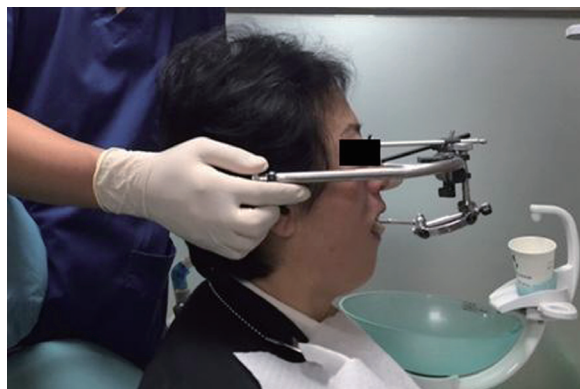

Fig. 8. Face-bow transfer.

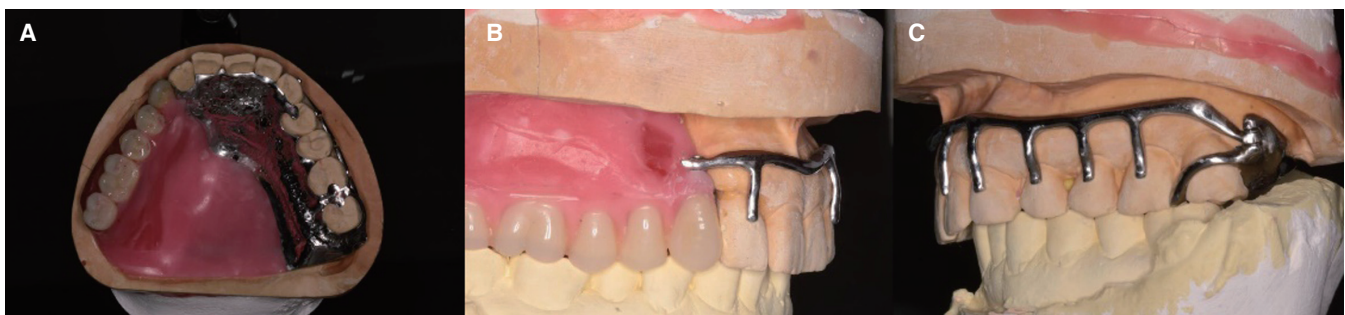

Fig. 9. Articulator mounting and teeth setting. (A) Occlusal, (B) Right, (C) Left side view.

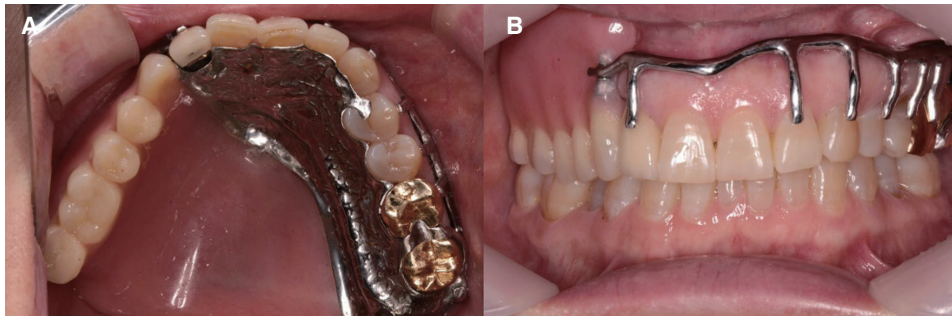


Fig. 10. Final seating. (A) Occlusal, (B) Frontal view.

DISCUSSION

“Gate clasp” was suggested for the first time by Ackerman in 1955.⁷ Simmons introduced the swing-lock design concept.⁸ Its mechanical retention was explained by Javid and Dadmanesh.⁹ On this foundation, obturator restoration by swing-lock design frameworks was discussed by several authors.^{10,11} Swing-lock design gets mechanical retention and support by labial or buccal bar which is made of hinge and latch.¹¹ For the labial bar, at least 6 - 8 mm of labial vestibule is needed. Labial bar should be at least the length of 4 teeth or more and there is no maximum limit as long as the anatomy allows.

Patients with maxillectomy get retention, support and stability from remaining tissues which are hardly optimal. The advantage of swing-lock attachment design is having multiple contacts on labial and lingual side of the abutment teeth by retentive strut and palatal bracing component.^{12,13} Because the force is distributed equally to abutment teeth, abutment teeth of poor prognosis can be benefited from it. It is a viable option even when canine is missing, or when abutment teeth are not aligned optimally. Rotated or tipped teeth would need endodontic, prosthodontic treatment or even splinting to support the key abutment teeth in conventional removable prosthodontics. However, swing-lock attachment design could bypass all those procedures, making it a more financially attractive option. It is also more advantageous to cover soft tissue defects which are hard to reach with conventional prosthesis.

Swing-lock attachment design is not indicated when the patient does not understand the concept or cannot wear it due to the lack of cognitive or motor skills. It tends to require more maintenance due to more complex design. Low labial vestibule would make it hard to fit labial bar. Patient with unrealistic esthetic expectation would not be satisfied with showing labial bar or strut.^{14,15}

This case belongs to Class II arch form. Edentulous area is located ipsilateral to the midsuture line, extending from upper right canine to the posterior area. In this case, support is achieved from the near and far rests of the edentulous area and the palate. In conventional design, the retention is achieved from the nearest abutment tooth from

the missing area by circumferential clasp, cast I bar and wrought wire. Many times, abutment teeth are splinted for more strength. Retention is often achieved by circumferential clasp in posterior teeth while rests are made on first bicuspid or canine as indirect retainers. Conventional retainers resist against masticatory force and abutment teeth take a lot of pressure. Therefore, flexible clasp is encouraged in planning while the undercut should be less than the usual.

Meanwhile, swing-lock attachment enables the most of the residual teeth as abutment teeth, enabling the prosthesis to be more stable. Fulcrum line will be at the incisal area where palatal plate will contact. Less torque and more retention will distribute pressure on the soft tissue more equally. Abutment teeth are stabilized and protected by palatal plate, labial strut and proximal plate. Swing-lock attachment design has many advantages over conventional design, while having esthetic disadvantages due to the presence of labial strut and bar. Additionally, it is more difficult and time consuming to fabricate the framework.

ORCID

Dong-Jae Seong <http://orcid.org/0000-0003-0423-4755>
 Seoung-Jin Hong <http://orcid.org/0000-0002-7460-8487>
 Seung-Ryong Ha <http://orcid.org/0000-0003-4176-6865>
 Young-Gi Hong <http://orcid.org/0000-0002-1356-8274>
 Hyo-Won Kim <http://orcid.org/0000-0001-5318-821X>

REFERENCES

1. Aramany MA. Basic principles of obturator design for partially edentulous patients. Part I: classification. *J Prosthet Dent* 1978;40:554-7.
2. Myers RE, Mitchell DL. A photoelastic study of stress induced by framework design in a maxillary resection. *J Prosthet Dent* 1989;61:590-4.
3. Curtis TA, Beumer J. Restoration of acquired hard palate defects: etiology, disability, and rehabilitation. In: Beumer J, Curtis TA, Marunick MT, eds. *Maxillofacial rehabilitation: prosthodontic and surgical considerations*. 1st ed. St. Louis: Ishiyaku Euro-America; 1996. p. 225-84.

4. Padilla MT, Campagni WV. The swing-lock removable partial denture. *J Calif Dent Assoc* 1997;25:387-92.
5. Bolender CL, Becker CM. Swinglock removable partial dentures: where and when. *J Prosthet Dent* 1981;45:4-10.
6. Schwartzman B, Caputo A, Beumer J. Occlusal force transfer by removable partial denture designs for a radical maxillectomy. *J Prosthet Dent* 1985;54:397-403.
7. Ackerman AJ. The prosthetic management of oral and facial defects following cancer surgery. *J Prosthet Dent* 1955;5:413-32.
8. Simmons J. Swing-lock stabilization and retention. *Texas Dent J* 1963;81:10-2.
9. Javid NS, Dadmanesh J. Obturator design for hemimaxillectomy patients. *J Prosthet Dent* 1976;36:77-81.
10. Black WB. Surgical obturation using a gated prosthesis. *J Prosthet Dent* 1992;68:339-42.
11. Parr GR, Gardner LK. Swing-lock design considerations for obturator frameworks. *J Prosthet Dent* 1995;74:503-11.
12. Lynch CD, Allen PF. The swing-lock denture: its use in conventional removable partial denture prosthodontics. *Dent update* 2004;31:506-8.
13. McKenna G, Ziada H, Allen PF. Prosthodontic rehabilitation of a patient using a swing-lock lower denture after segmental mandibulectomy. *Eur J Prosthodont Restor Dent* 2013;21:141-4.
14. Aggarwal H, Cho SH. Complete removable dental prosthesis with the swing lock system: A clinical report. *J Prosthet Dent* 2014;112:1035-7.
15. Razaq I, Durey K, Nattress B. Provision of a swing lock denture for a patient with Gorlin Goltz syndrome. *Eur J Prosthodont Restor Dent* 2012;20:141-4.